

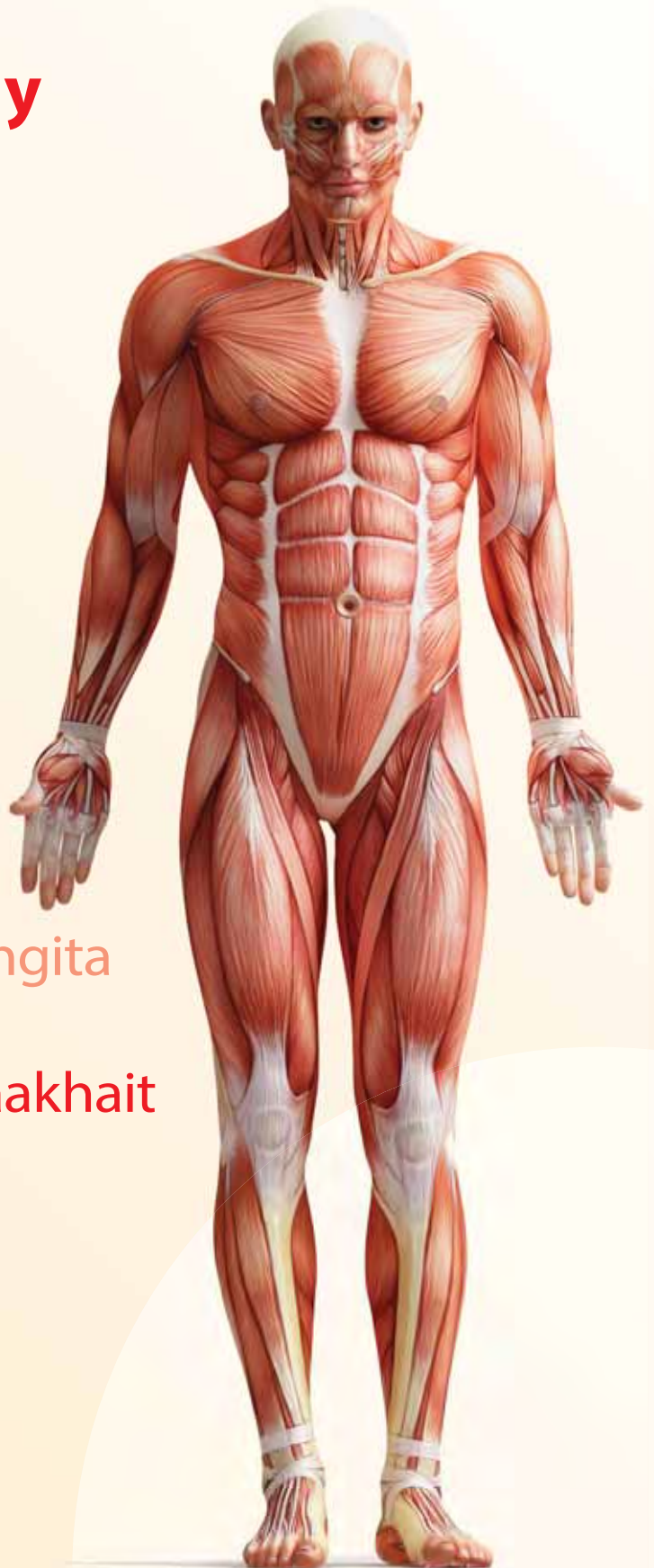# Terminology on Human Anatomy

በገጠና  
የሥነ-ጥናት  
ርዕሰ-ጽሑፍ

Timiup  
Kisukuttilimaangita  
Taiguusingit

Timimi Kituuyaakhait  
Taidjutait

Terminologie  
anatomique











# INTRODUCTION

This is the first colored illustrated human anatomy glossary in Nunavut's official languages. Under Nunavut's language legislation, Nunavummiut have a right to be served in their official language of choice. It is our hope this glossary will become a tool to help improve communications between doctors, nurses, interpreters and patients working and living in our Territory.

Human anatomy terminology is well documented in both English and French. Attempts were made to document human anatomy in Inuktitut from written sources (see Guy Bordin's *Analytical Lexicon of Human Anatomy*, 2003). However, this is the first time traditional terminology in both Inuktitut and Inuinnaqtun on human anatomy is documented directly from Inuit Elders, in consultations with medical interpreters, translators and health professionals in Nunavut.

This project was initiated to address the concerns of Inuit Elders who often struggle to understand or be understood as they often rely on interpretation for their health and medical conditions. We can't stress enough how important the use of accurate terminology in interpretation is crucial for a person's well-being and dignity.

To address these challenges, the Department of Culture and Heritage hosted four workshops in Iqaluit, Kugluktuk and Ulukhaqtuuq, NWT. Participants helped identify Inuktitut and Inuinnaqtun equivalents of approximately 400 English terms related to human anatomy. A review of the terms and associated illustrations was also conducted with smaller groups of Elders and a medical interpreter.

We would like to thank the following individuals who helped identify, review and edit the terms.

## Department of Culture and Heritage

Agnes Ayalik, Agnes Egotak, Carol Cancel, Ida Ayalik-McWilliam, Lазarie Otak, Madeleine d'Argencourt, Ranbir Hundal, Rosemarie Meyok, Sarah Nangmalik, Tocasie Burke.

## Department of Health

Abigail Ootova, Agnes Adams, Alice Kimiksana, Audrey Lemieux, Catherine Kuneluk-Taktogon, Connie Alanak, Diane Netser, Eric Anautalik, Irene Eckalook, Lizzie Nowdluk, Lori Barbour, Louisa Oqaituq, Lucy Anna Nookiguak, Mary Gabby Ikkidluak, Mary Kopak, Nora Niptanatiak-Evaglok, Rene Qulaut, Rosie Kagak, Sarah MacRury, Sandra Qamaniq, Sipporah Peterloosie, Timothy Qamaniq, Veronica Komangat.

## **Nunavut Elders**

Alice Ayalik, Arsene Ivalu, David Issigaitok, Elijah Erkloo, Elisapee Adla, Elisapee Ootovak, Jaycopie Iqalukjuaq, Joanna Qamaniq, Joanasie Kooneeloosie, Joe Ogina, Kigutikarjuk Shappa, Lillian Elias, Louisa Aitaok, Louis Angalik, Margaret Nakashook, Martha Nangmalik Enuaraq, Mariam Aglukkaq, Marianne Tattuini, Mark Taletok, Mary Kudlak, Morris Nigiyok, Nangaat Idlout, Nathan Qamaniq, Norman Attungala, Qapik Attagutsiak, Rene Oliktoak, Rhoda Karetak, Sammy Qaumagiak, Simeonie Aqpik, Simeonie Kaerner, Susie Angotealuk, Thomas Kublu, Tommy Kilaodlok, Tommy Pigalak.

## **Interpreter translators**

Jean Kusugak, Margo Kadlun-Jones, Mary Jean Katiak, Oleepika Ikkidluak.

## **Resource People**

Doris Elatiak, Emily Kudlak, Julia Ogina, Nancy Kadlun.





# HIVUATIGUN NAUNAITKUTIT

Una hivulliuuyq ivitaalik piksait timitigut tainikhat Nunavut Iltariyauhimagut Uqauhiinut titiraqhimayuq. Ukunani Nunavut uqauhiinik maligani. Nunavunmiut pilaarutiqaqtut inmik uqauhirmingnut aturumayamingnut ikayuqtauttaaqut. Piyumayugut ukua tainikhat titirait ikayuutauniaqtuq nakuuharlugit tuha-apkainiit taaktinut, munaqhinut, numiktiriyinut, aanniaqtunut nunaqaqtut Avikturviptingni.

Timitigut tainikhat titirattiaqhimayut Qablunaatut Uiviititullu. Uuktuqpaktu-ugaluit titirarlugit timip taidjutait Inuktut titirariiqhimayunit (takulugu Guy Bordin Ihiviruttiaqhimayuq Tainiit Timitigut, 2003-mi) kihiani, una hivulliuuyq pitquhiit tainiit tamangnik atuqhugik, Inuktitut Inuinnaqtullu timitigut tainikhat titiraqtauhimaliqtut ikayuqtiqaqhutik uqarvigiblugit Inirnikhaat, qauhiyarvigiblugit aanniaqtuliqiyit havaktiit numiktiriyit, aanniaqtuliqiyit ayuittiaqtunit Nunavunmi.

Una havaakhauhiq aulapkaqhimayaat kiudjutaubluni ukununga Inuit Inirnikhaat ilaani ayuqhaqpangmata kangiqhiyaamingni numiktiriyiqainnarmata aanniaru-timingnik uluriahuutigiyamingnik. Qanuq unniutiyaffingni akhuurluta ikpingnaqtuq aturiami ihuaqtunik taidjutikhanik numiktiriliraangamik ikpingnaqtuuyurlu inuup inuuhianut pidjutikhaanut.

Kiudjutigiangita haputauvaktut, Pitquhiliqiyitkut katimapkaihimmaaahimayut hitamaiqtuqhutik Iqalungni, Kugluktumi Ulukhaqtuumilu Nunattiami. Kati-maqatauyut ikayuqtut naunaiqhiblutik Inuktitut Inuinnaqtullu aadjikkuutat amigiangiqaqtut imaa 400-nguyut qablunaatut tainiit timikkut. Ihivriuqtaqhugit tainiit piksaillu katimayut ikitqiyat Inirnikhaat munaqhiqarvingni numiktiriyiit.

Quyagiyumayavut ukua ikayuqpaktut naunaiqhaiblutik, ihivriuqhiblutik ihuaqhaiblutik tainiinnik.

## Pitquhiliqiyitkunit

Sarah Nangmalik, Tocasie Burke, Ida Ayalik-McWilliam, Rosemarie Meyok, Agnes Ayalik, Agnes Egotak, Lazarie Otak, Madeleine d'Argencourt, Ranbir Hundal, Carole Cancel.

## Munaqhiliqiyitkunit

Lori Barbour, Sipporah Peterloosie, Timothy Qamaniq, Rosie Kagak, Catherine Kuneluk-Taktogon, Sarah MacRury, Sandra Qamanirq, Rene Qulaut, Mary Gabby Ikkidluak, Abigail Ootova, Lucy Anna Nookiguak, Irene Eckalook, Eric Anautalik, Diane Netser, Agnes Adams, Louisa Oqaituq, Lizzie Nowdluk, Mary Kopak, Audrey Lemieux.

## **Nunavunmi Inirnikhaat**

Elijah Erkloo, Elisapee Ootovak, Qapik Attagutsiak, Kigutikarjuk Shappa, Jaycopie Iqalukjuaq, David Issigaitok, Arsene Ivalu, Thomas Kublu, Sammy Qaumagiak, Elisapee Adla, Simeonie Aqpik, Joanasie Kooneeloosie, Martha Nangmalik Enuaraq, Marianne Tattuini, Susie Angotealuk, Louis Angalik, Rhoda Karetak, Nangaat Idlout, Mariam Aglukkaq, Alice Ayalik, Norman Attungala, Simeonie Kaernerik, Joanna Qamaniq, Nathan Qamaniq, Mark Taletok, Tommy Kilaohok, Rene Oliktoak, Morris Nigiyok, Tommy Pigalak, Mary Kudlak, Louisa Aitaok, Margaret Nakashook, Lillian Elias.

## **Numiktiriyuyut**

Jean Kusugak, Oleepika Ikkidluak, Margo Kadlun-Jones, Mary Jean Katiak.

# Body/Trunk/Limbs

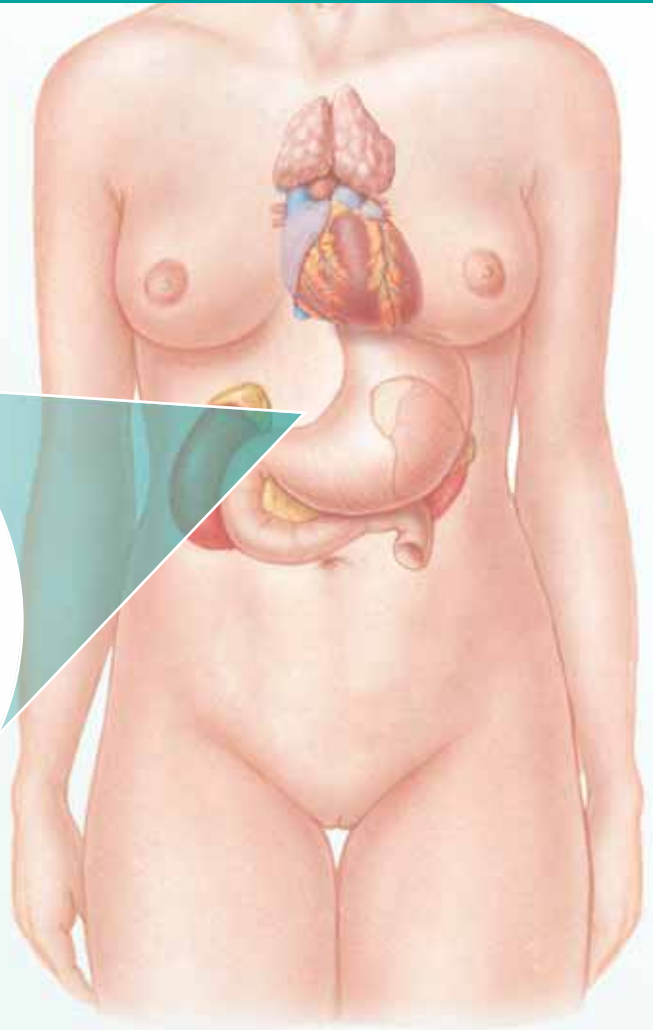
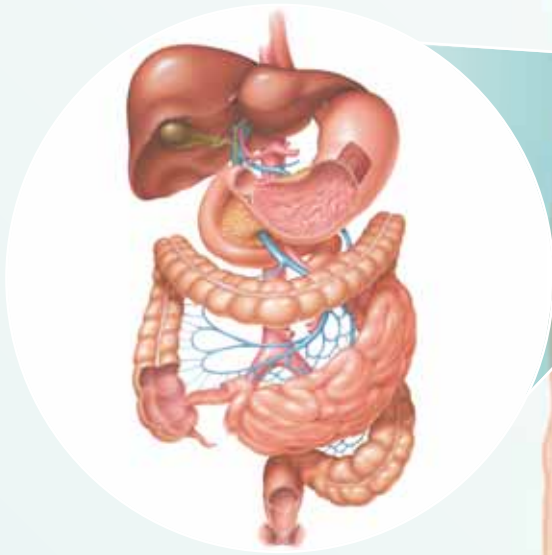ᑎᑦ / ᑭᑦᑎᑦ / ᑕᑦᑭᑦᑎᑦ

Timi/Kiati/Iqijarniit

Timi/Qatigak/Avatiit

Corps / Tronc / Membres

# Abdomen/ Belly



᠒᠙᠖

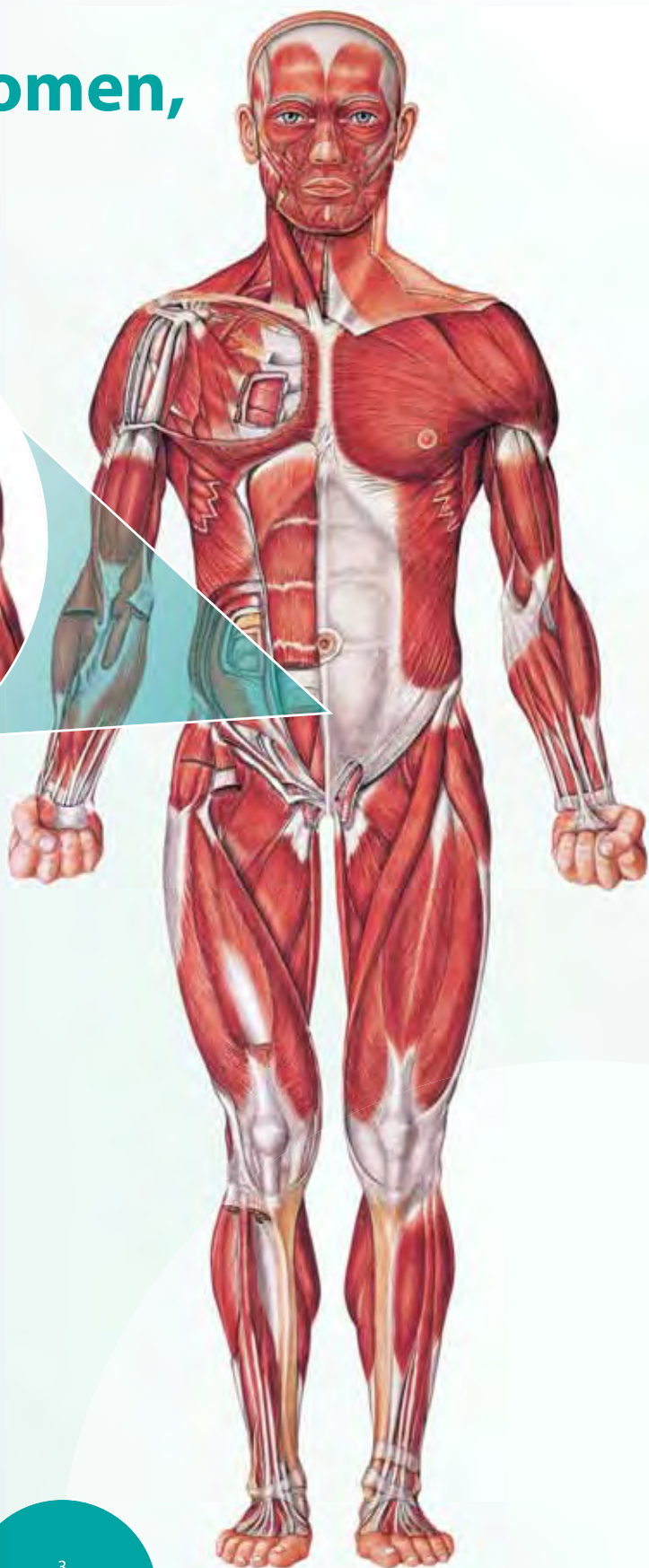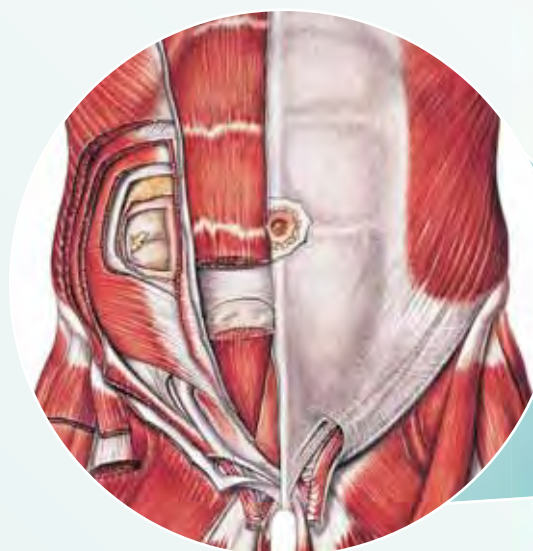
Naaq

Naaq

Ventre, abdomen



# Lower Abdomen, Lower Belly



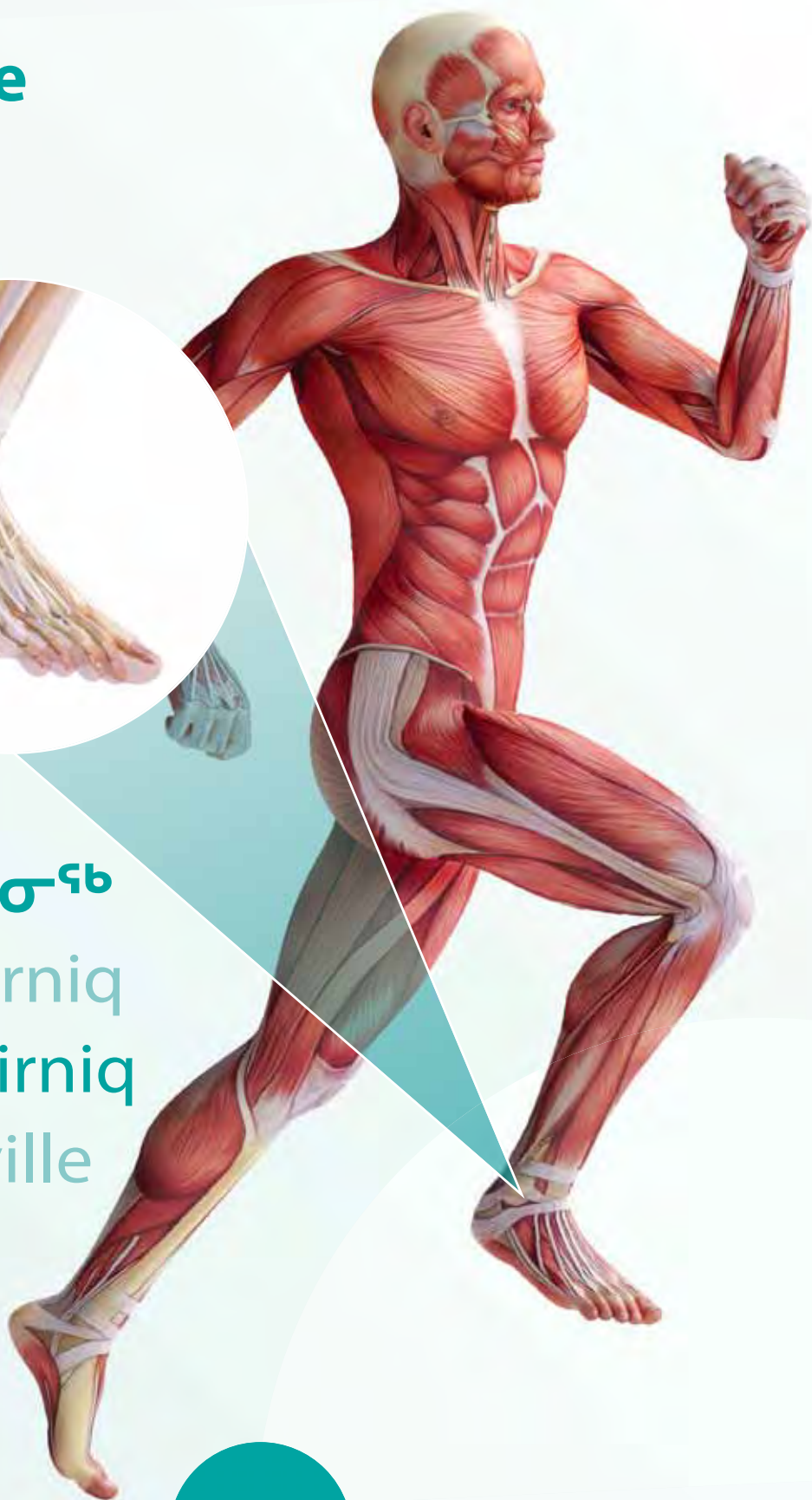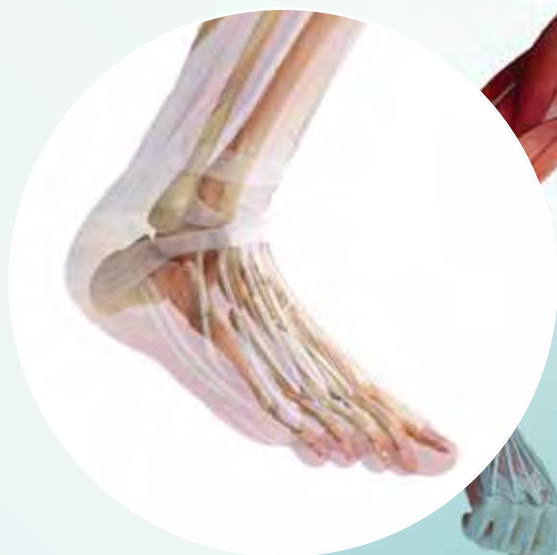ᐱᐃᐱᐅᑳ

Akuaq

Akuaq

Bas-ventre

# Ankle



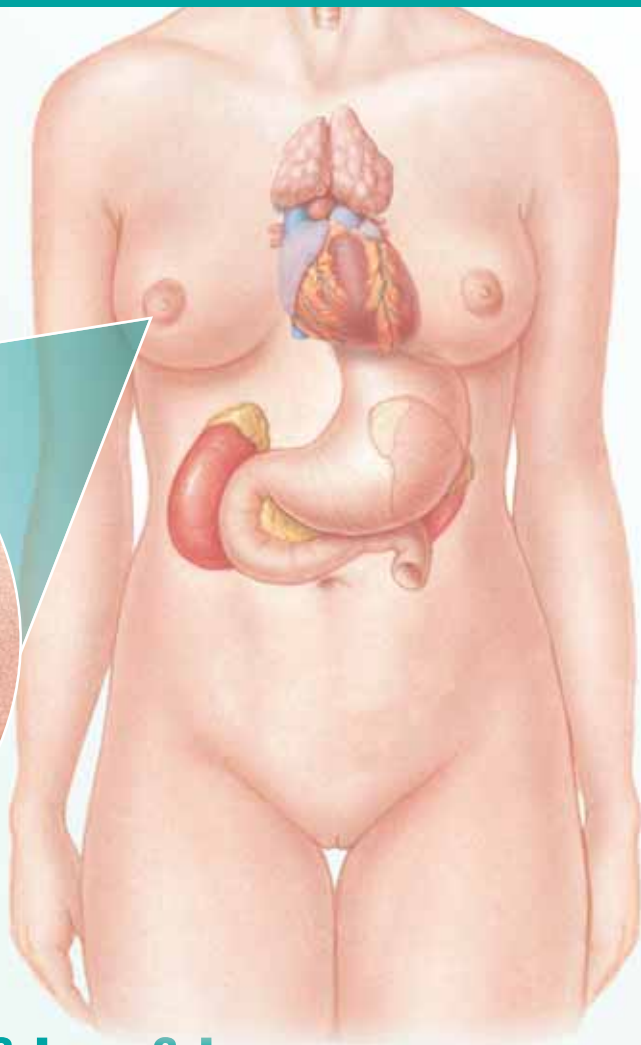
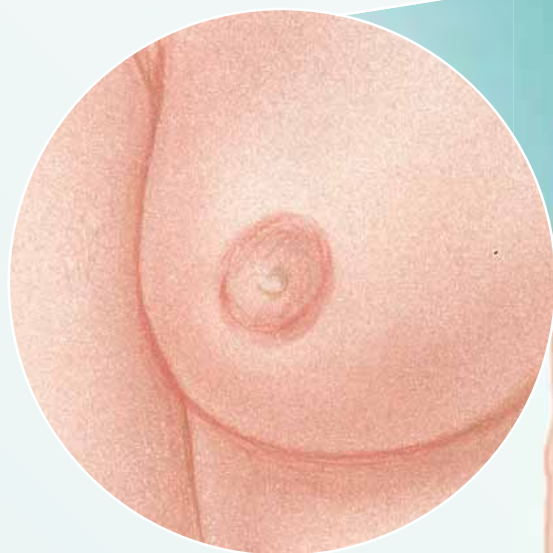ᲠᲚᲛᲗᲚᲛᲗ

Singirniq

Hingirniq

Cheville

# Areola



ᐱᐱᐱᐱ ᐱᐱᐱᐱᐱᐱᐱᐱ

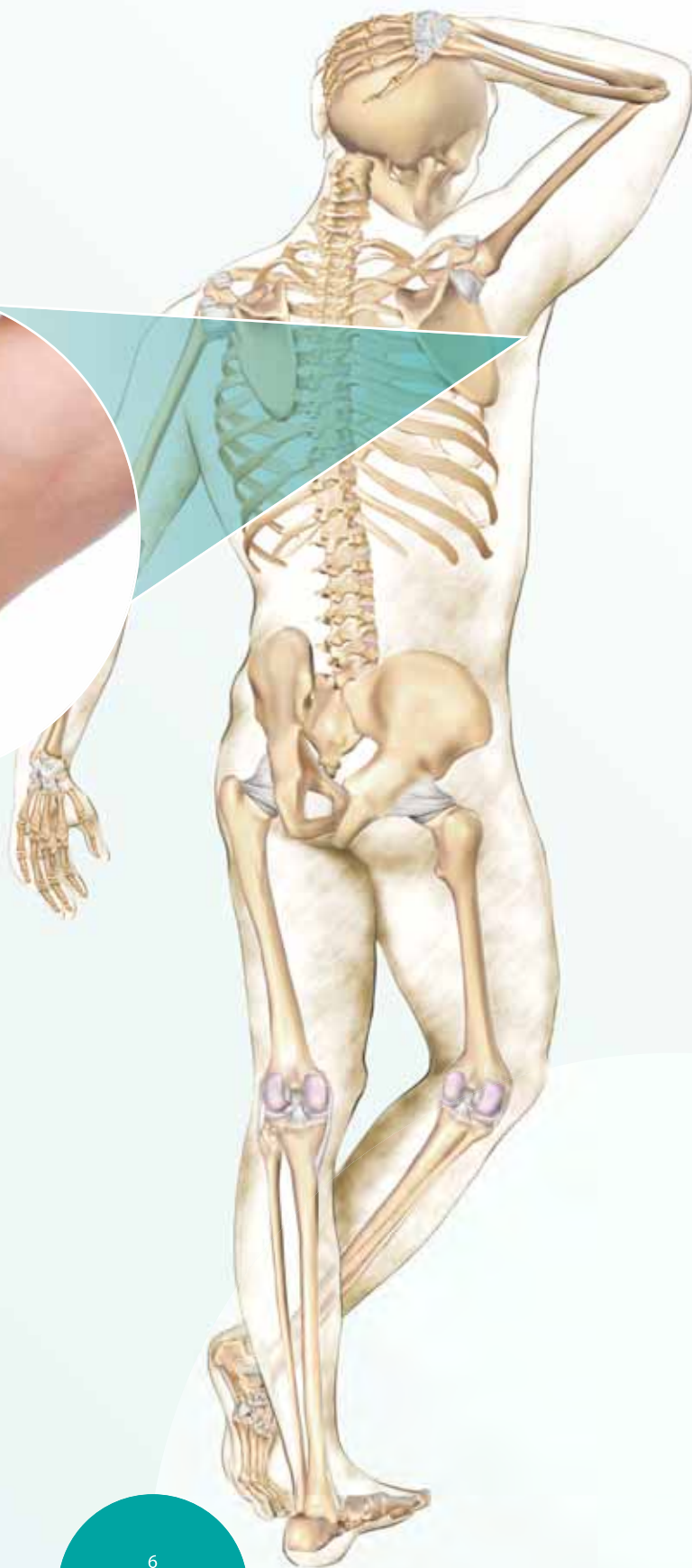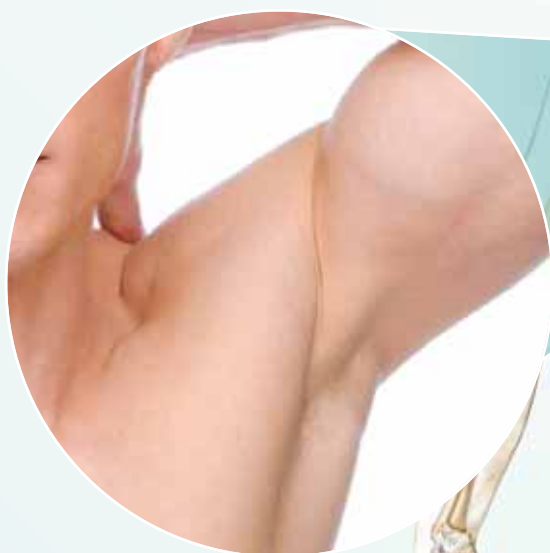Muliup Qirnaanganinga

Muluup Avataa

Aréole



# Armpit/ Axilla



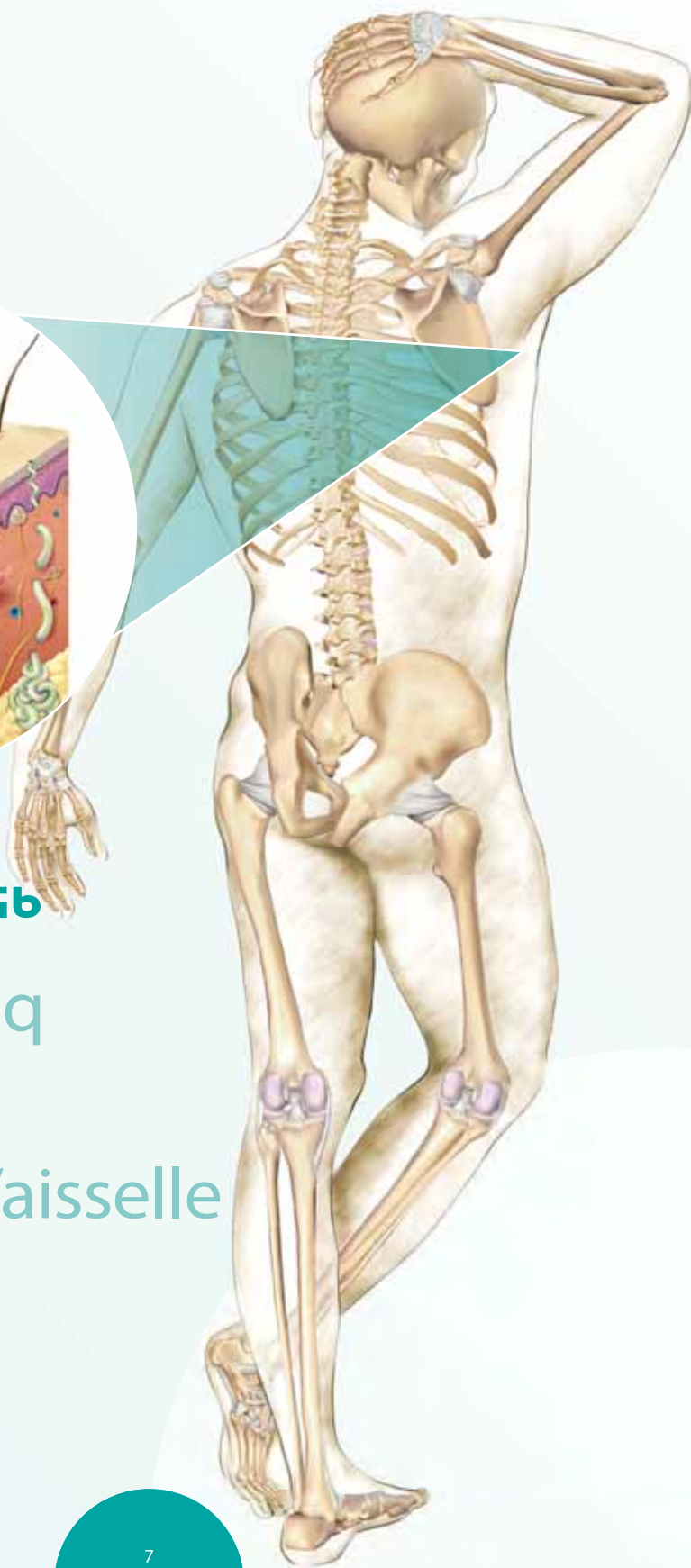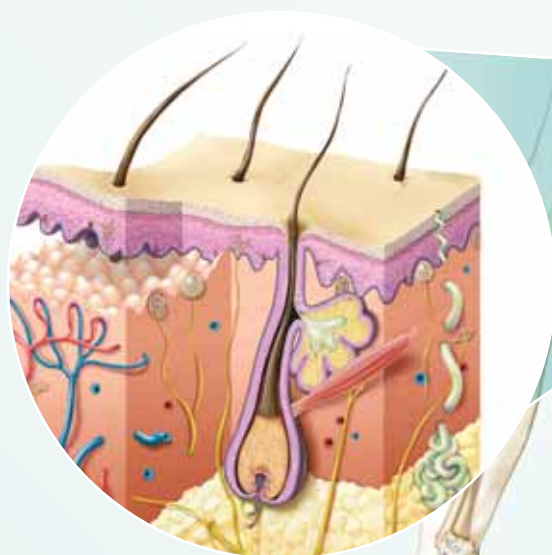
▷σ<sup>ϕ</sup><sub>b</sub>

Uniq

Uniq

Aisselle

# Axillary Hair



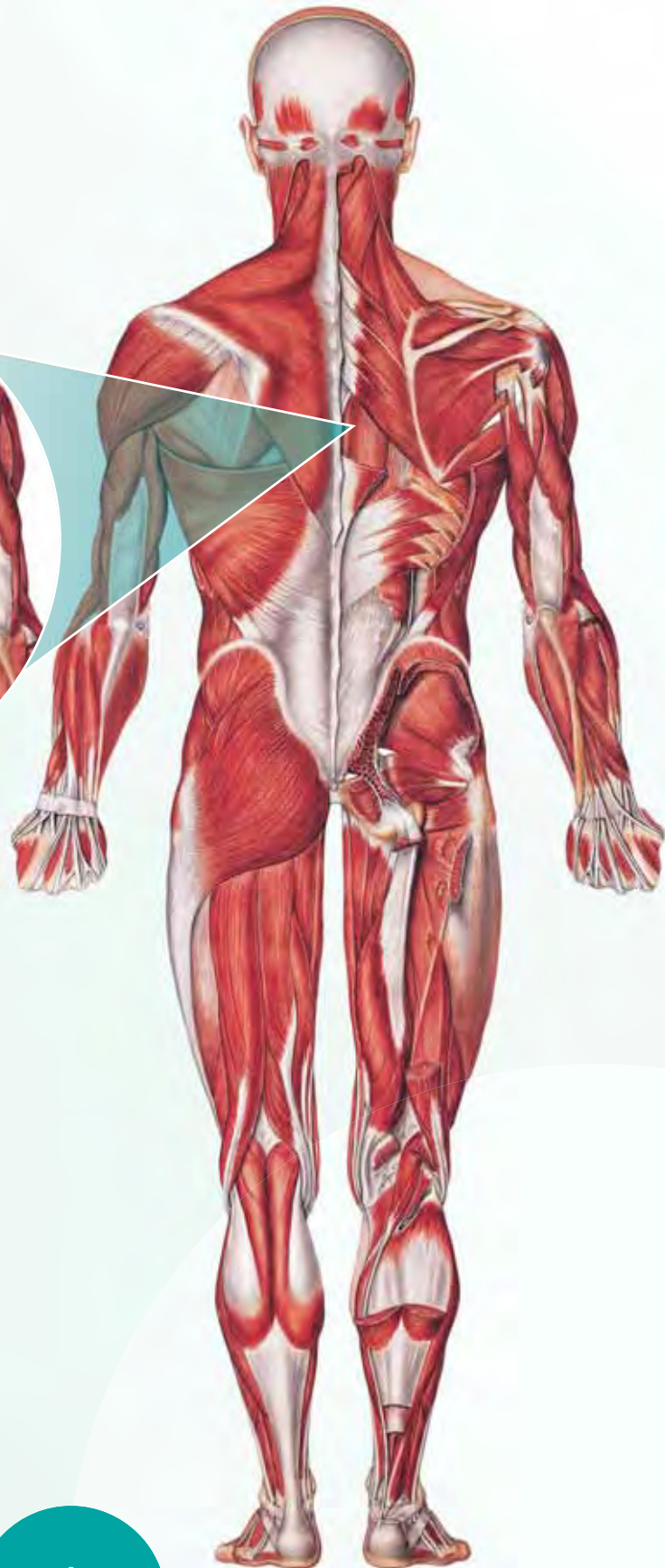
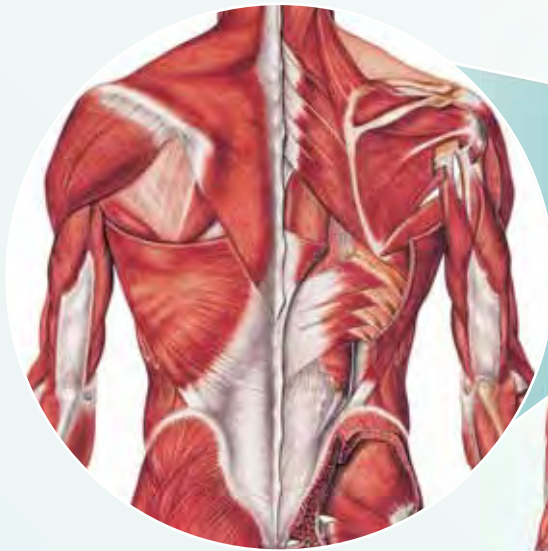▶ ԳՆՐԸԿԻՅԵ

Urngilisaq

Unirutit

Poils de l'aisselle

# Back



ᐅᐅ

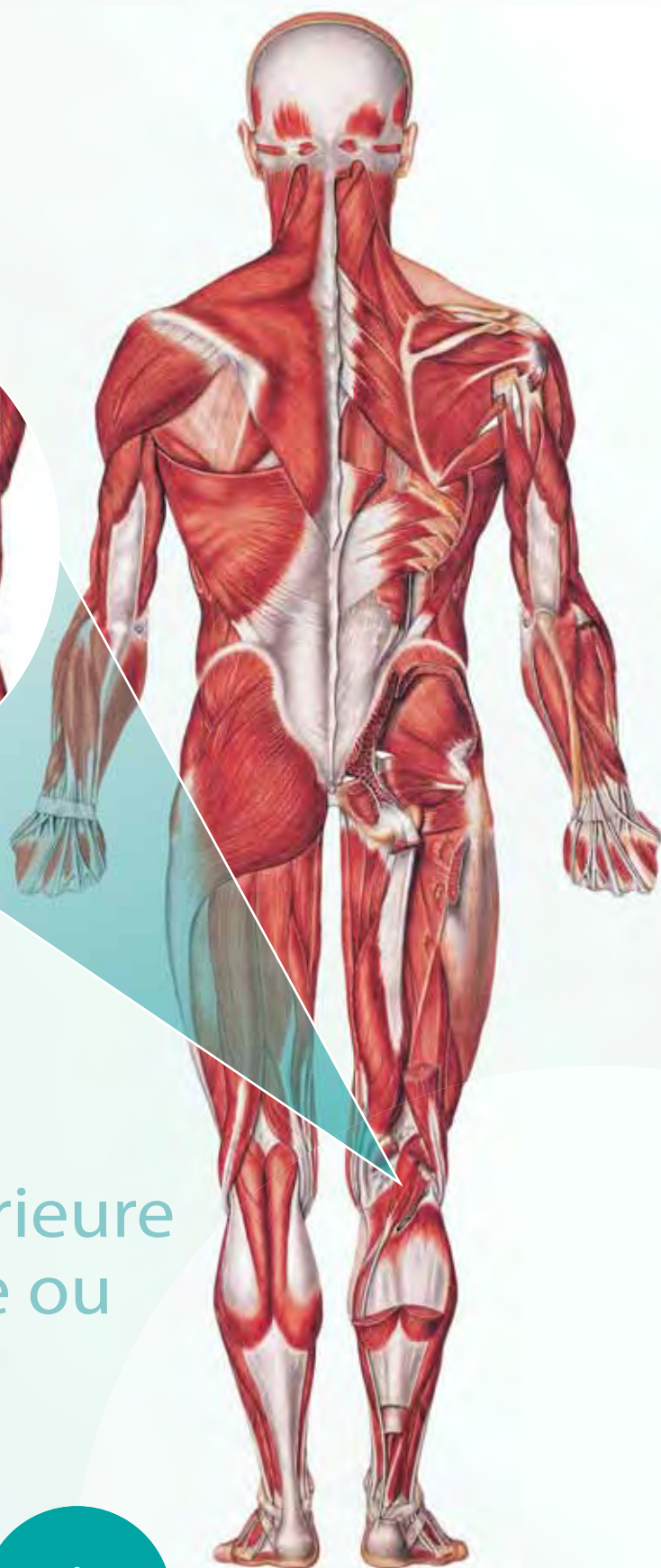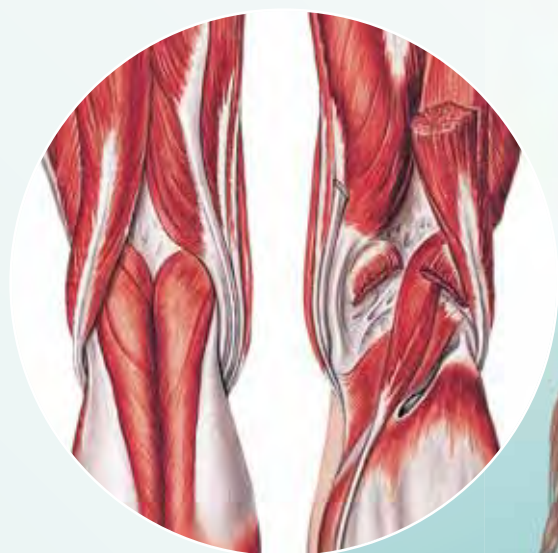
Tunu

Quliik

Dos



# Back of the Knee



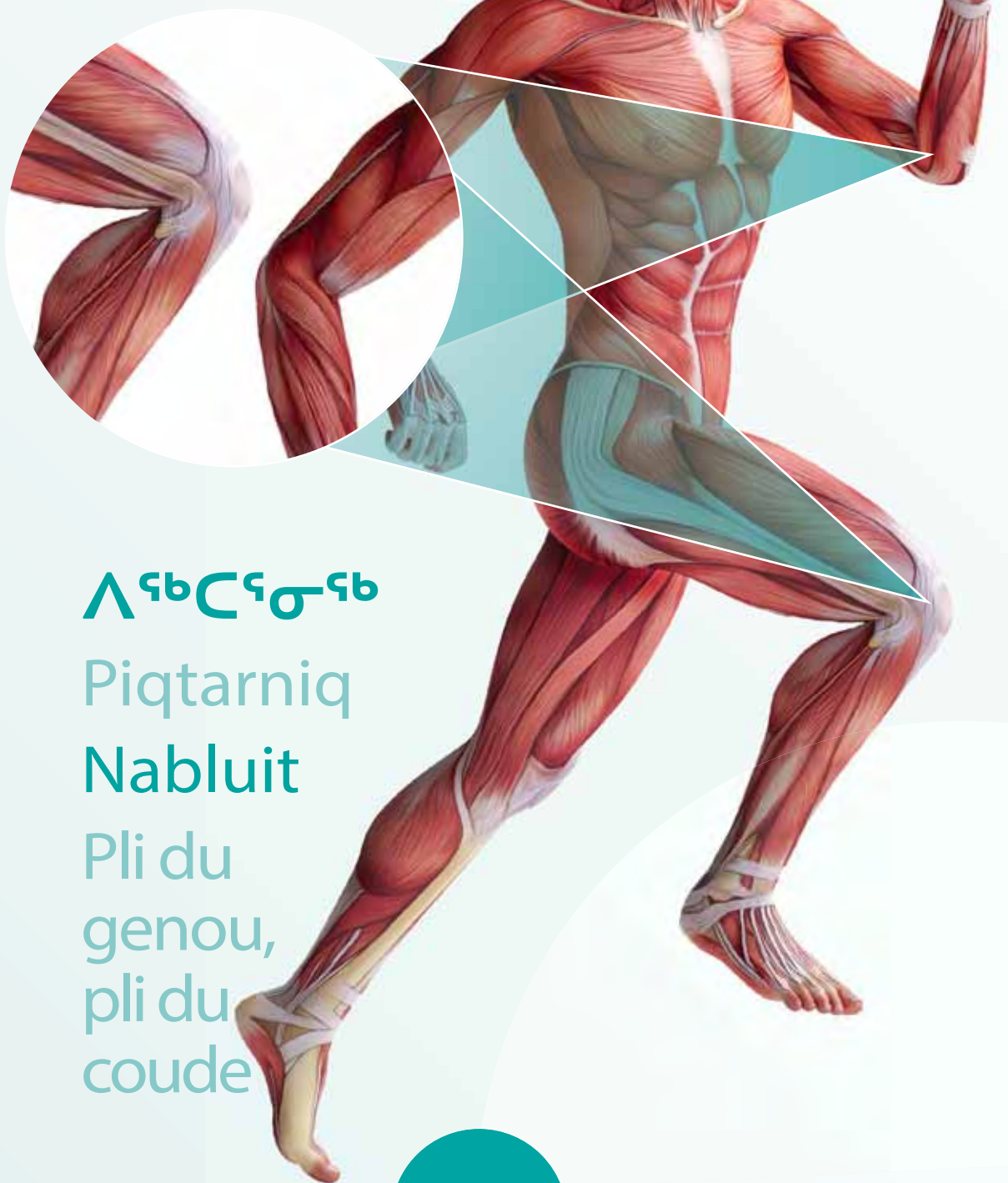ᐱᑦᑲᑦᑲᑦᑲᑦᑲᑦ

Piqtarniq

Kinguraq

Face postérieure  
de la cuisse ou  
du genou

# Bend of the Knee / Bend of the Arm



Λ ςϐ C ς σ ςϐ

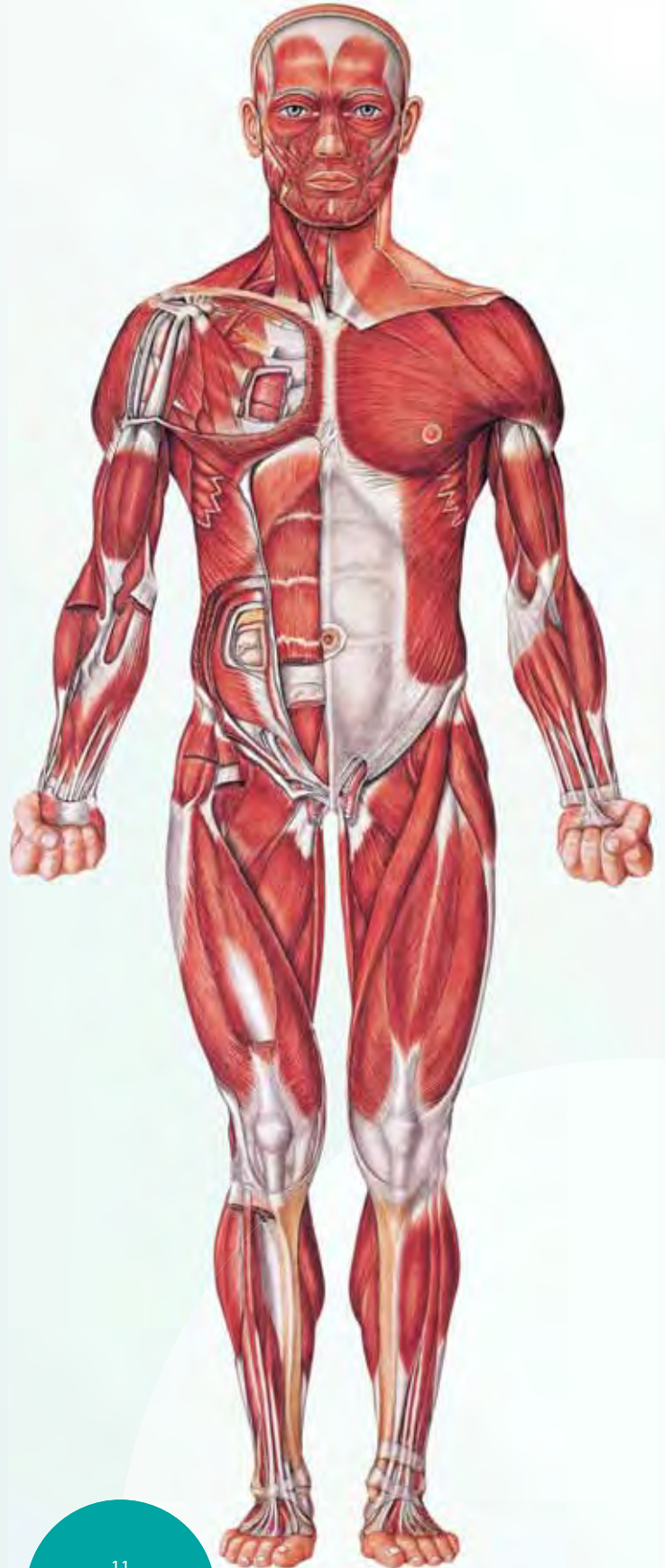Piqtarniq

Nabluit

Pli du  
genou,  
pli du  
coude

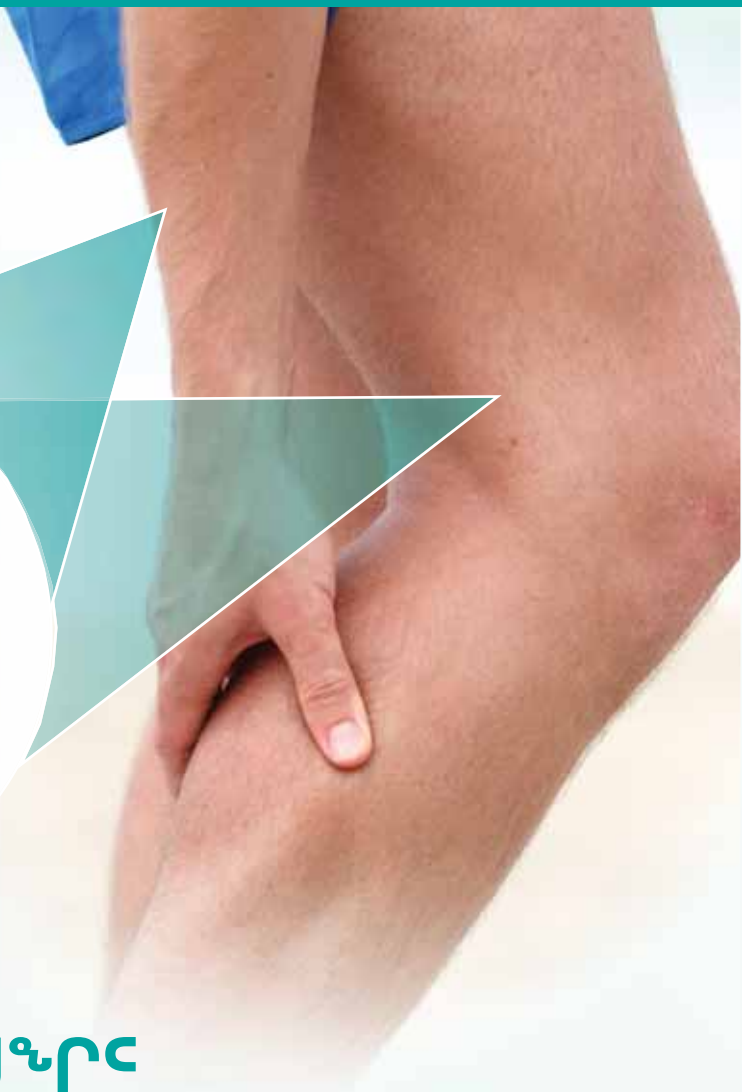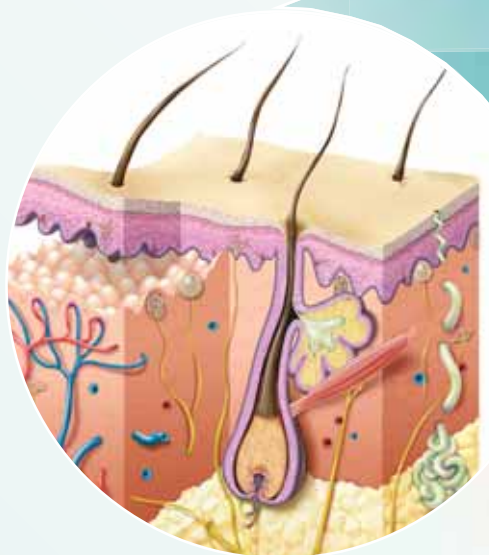


# Body



nr  
Timi  
Timi  
Corps

# Body Hair



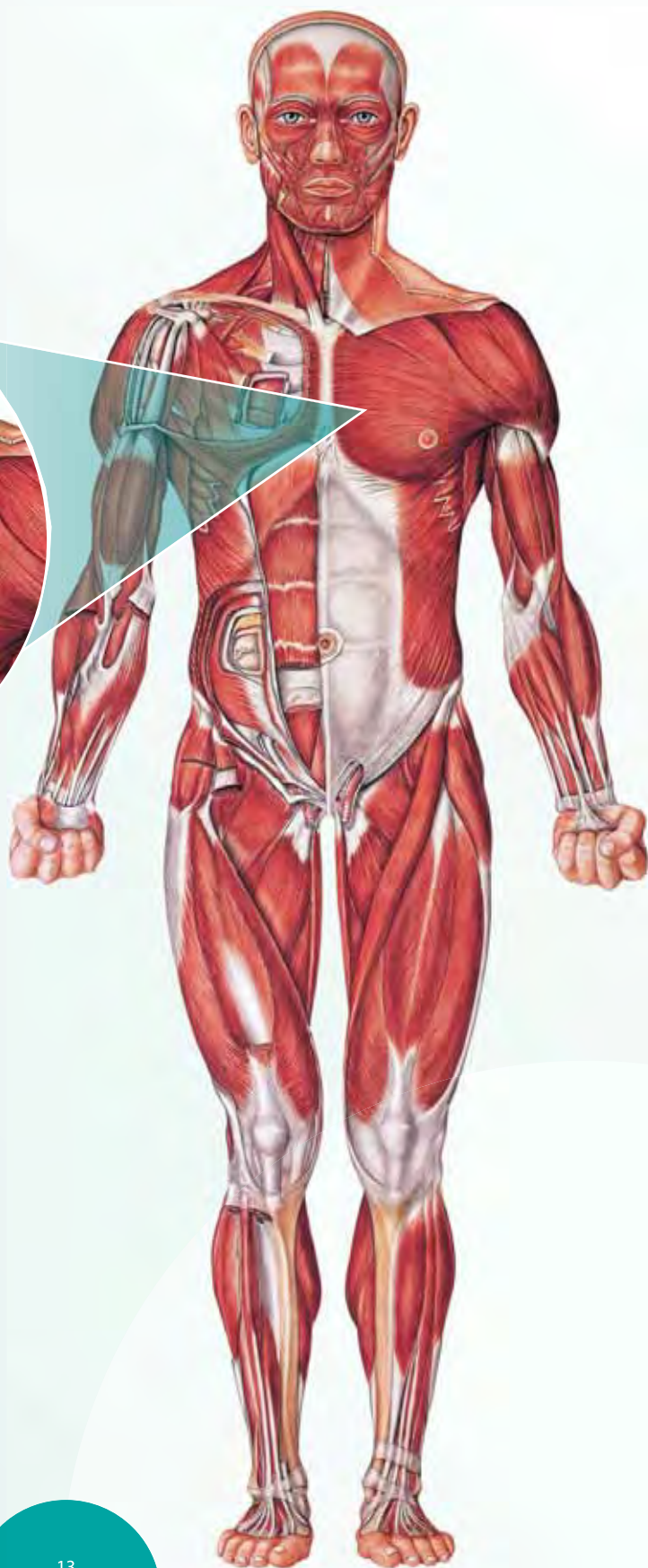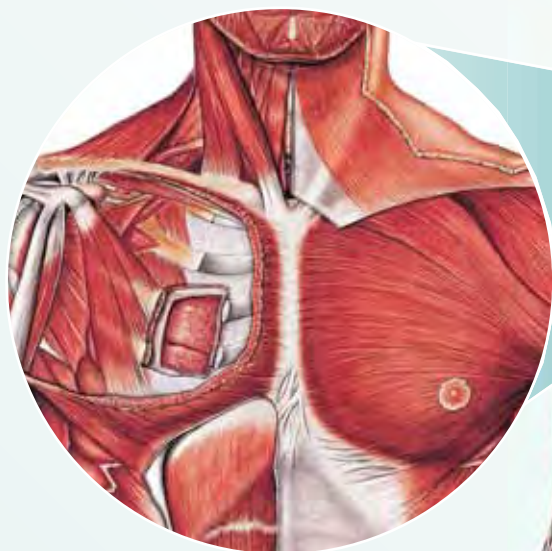
ᐅᐅᐅᐅ ᐅᐅᐅᐅᐅᐅ

Timiup Miqqungit

Timip Mitquit

Poils (à l'exception  
du cuir chevelu)

# Bust



ᄁᄁᄁᄁ

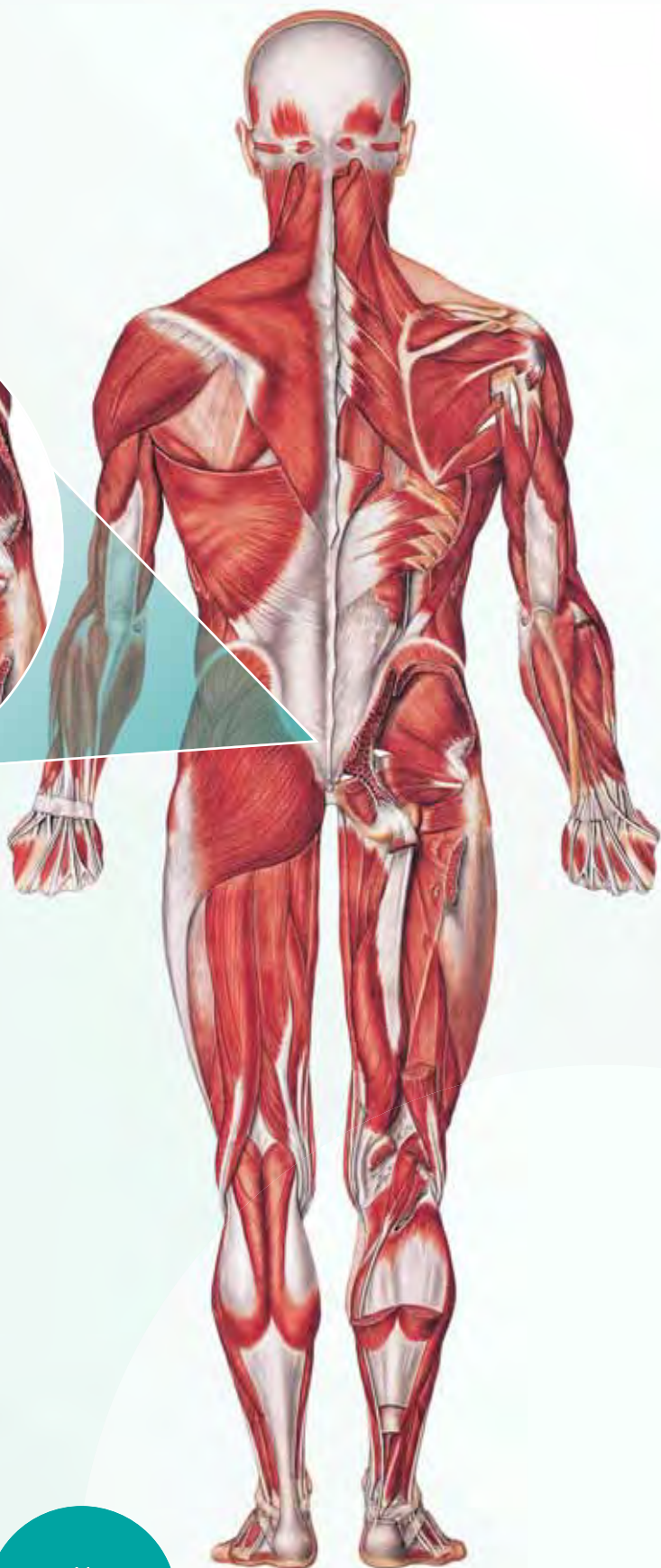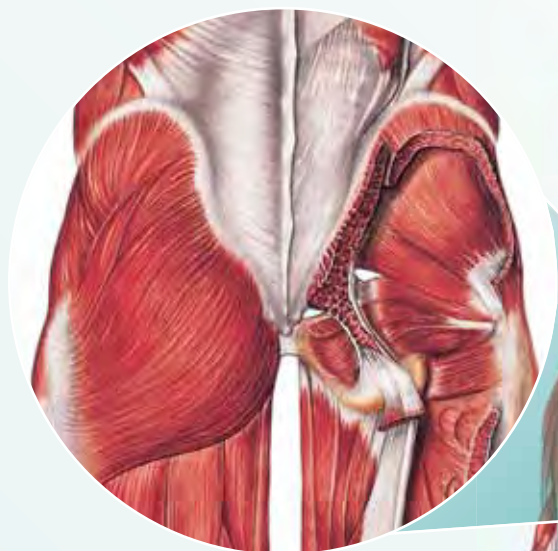
Qatigaak

Qatigak

Buste



# Buttocks



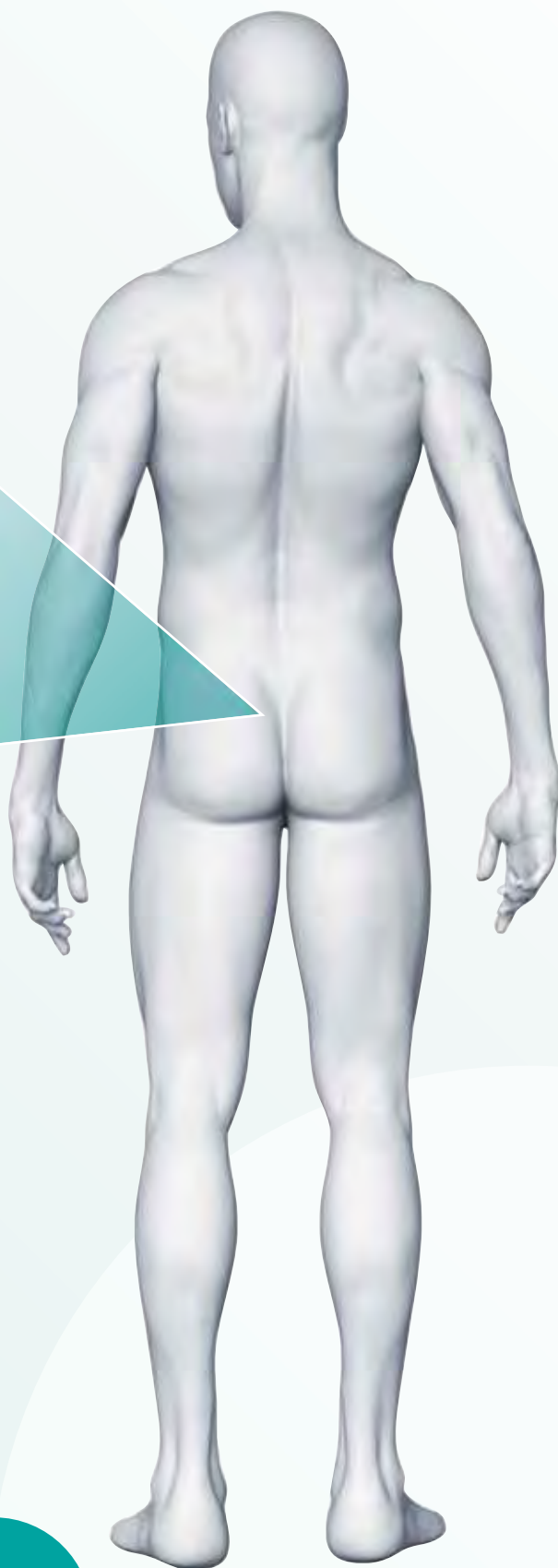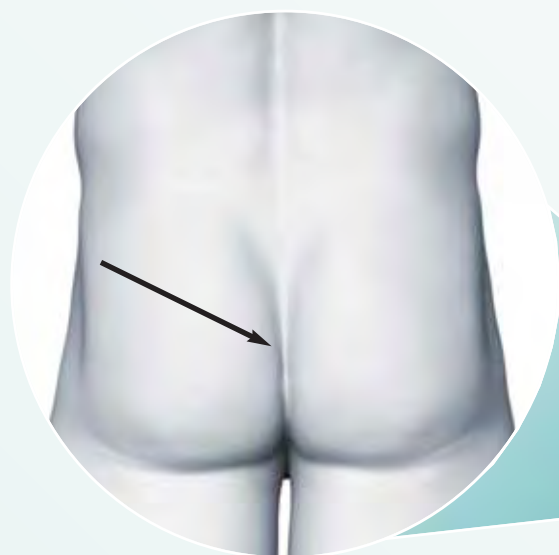▷◁᠋᠋᠋

Ukpatiik

Nulluk

Fesses

# Cleft of the Buttocks



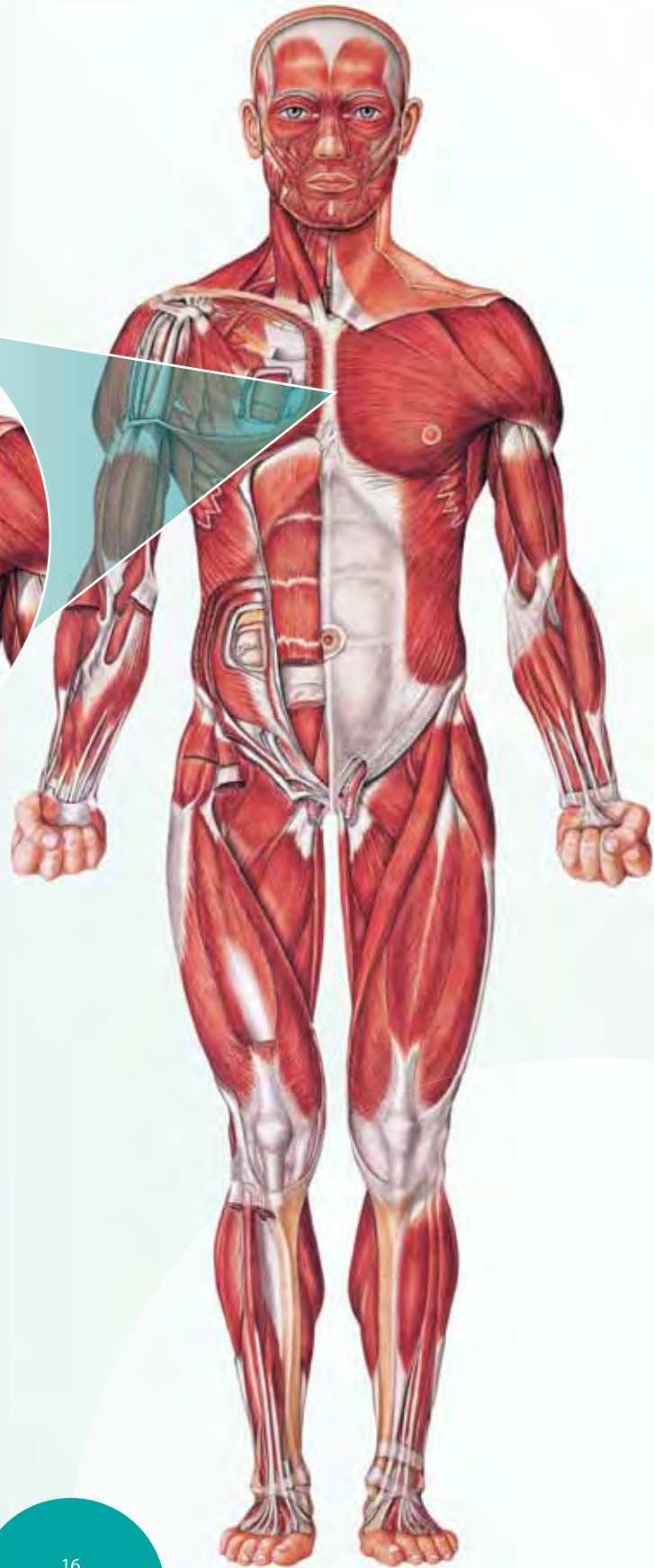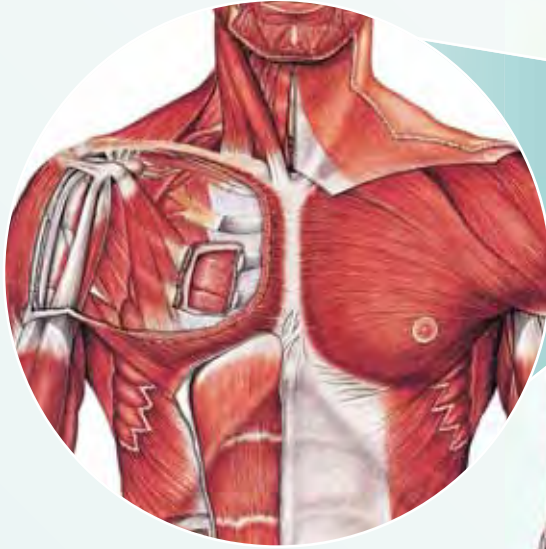
Δηφδλζβ

Itirviluk

Itirviluk

Raie des  
fesses

# Chest



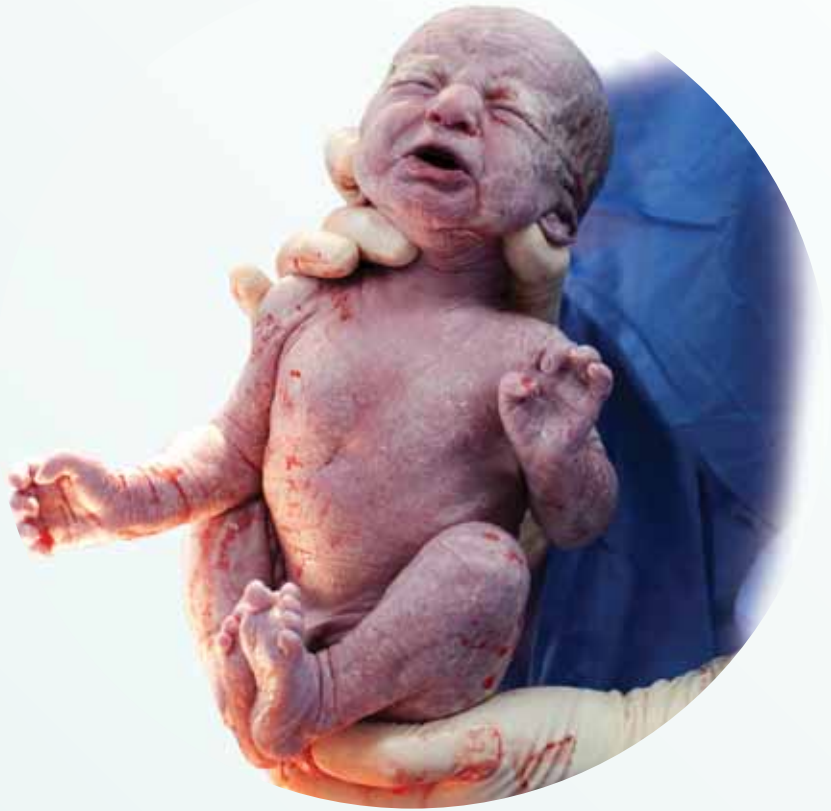ԿՆՃԵ

Sagvik

Hatqak

Poitrine

# Cyanosis



ᑕᕐᑭᑦᑕᑦᑕᑦᑕᑦᑕᑦ

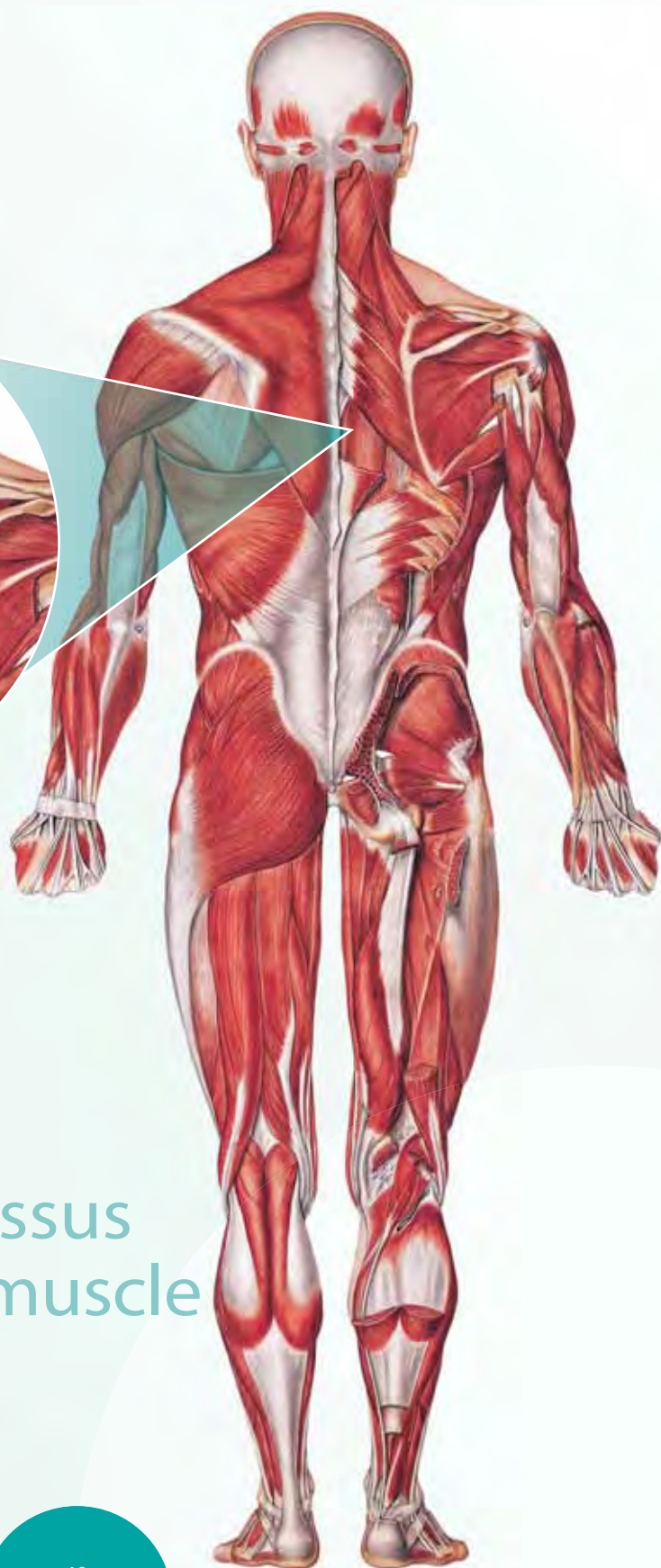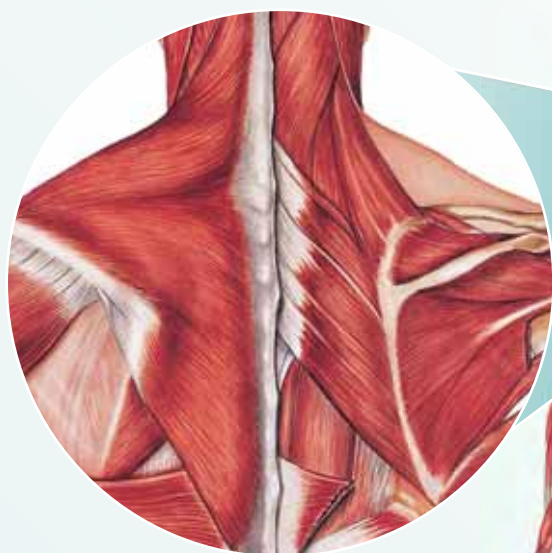
Tunguaqtittuq

Tunguqtittuq

(qui a des) Cernes



# Dorsal Region



قۇلىق

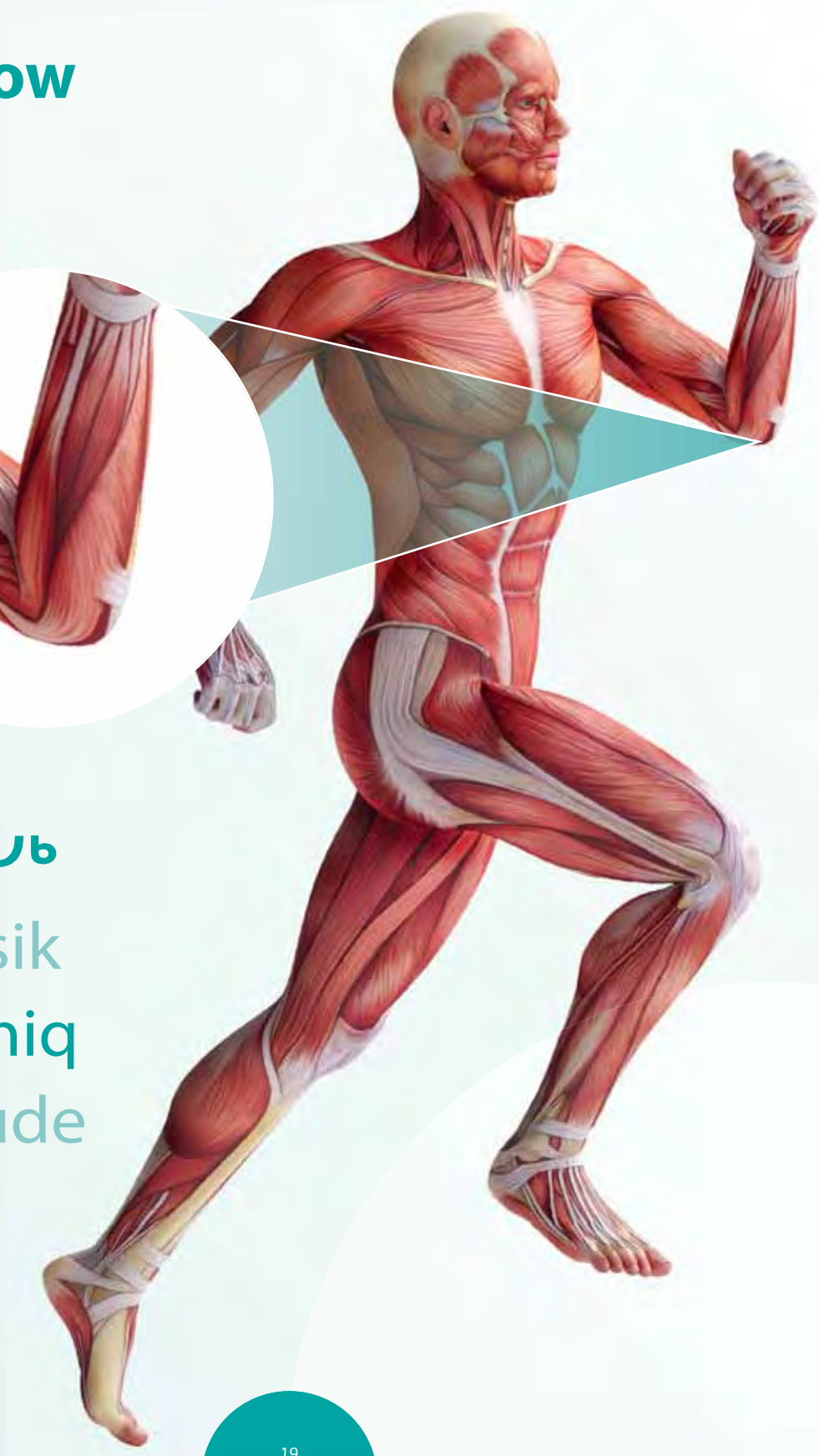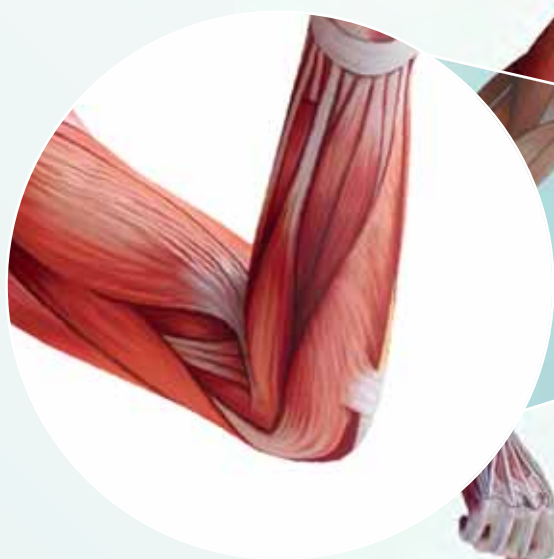Quliik

Quliik

Dos (au-dessus  
des reins), muscle  
trapèze



# Elbow



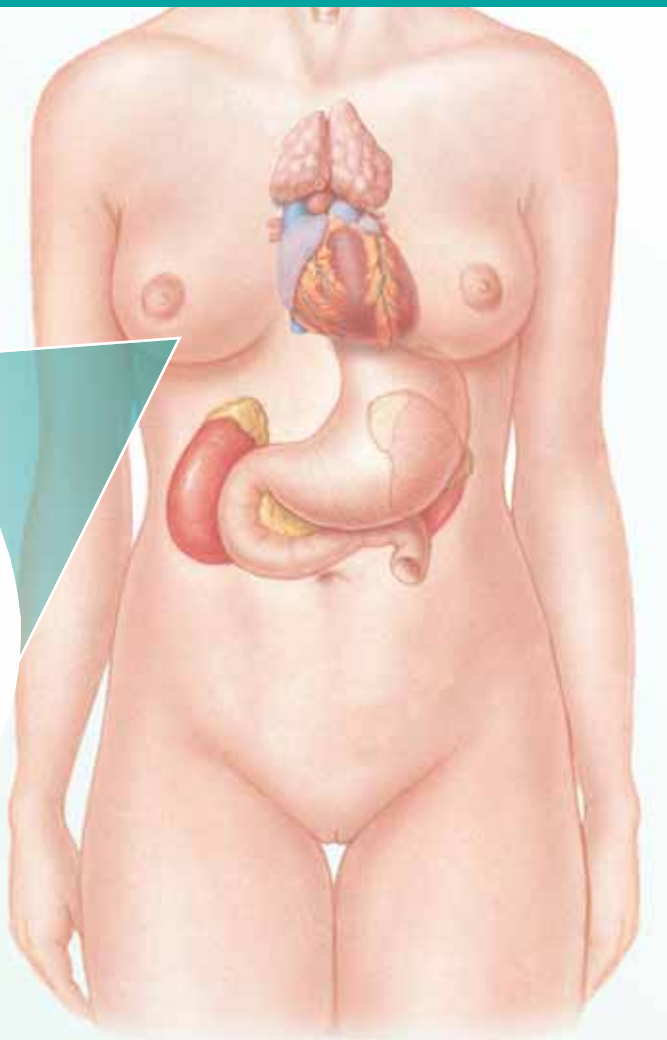
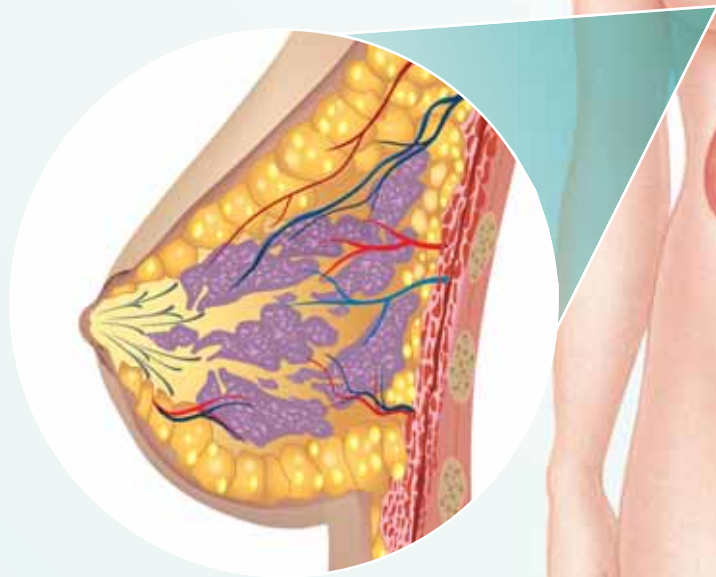
Δdʀᵇ

Ikusik

Ikuhiq

Coude

# Female Breast



ΔΔΔΔΔΔ

Iviangiq

Iviangiq

Sein féminin

# Freckle



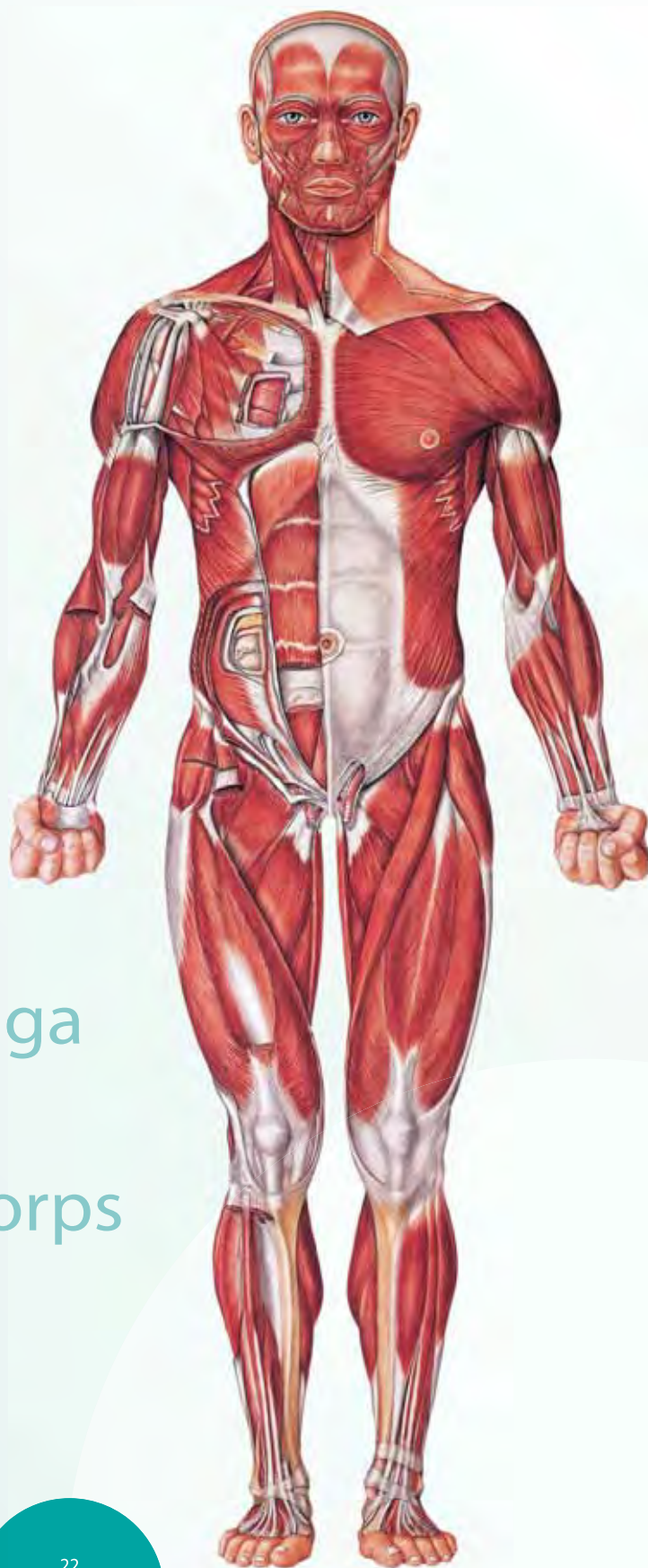ᑃᑃᑦᑲᑦ

Kukuvait

Kukuvalaaq

Grain de beauté,  
tache de son

# Front of the Body



ᐃᓂᐸ ᐱᓂᓴ

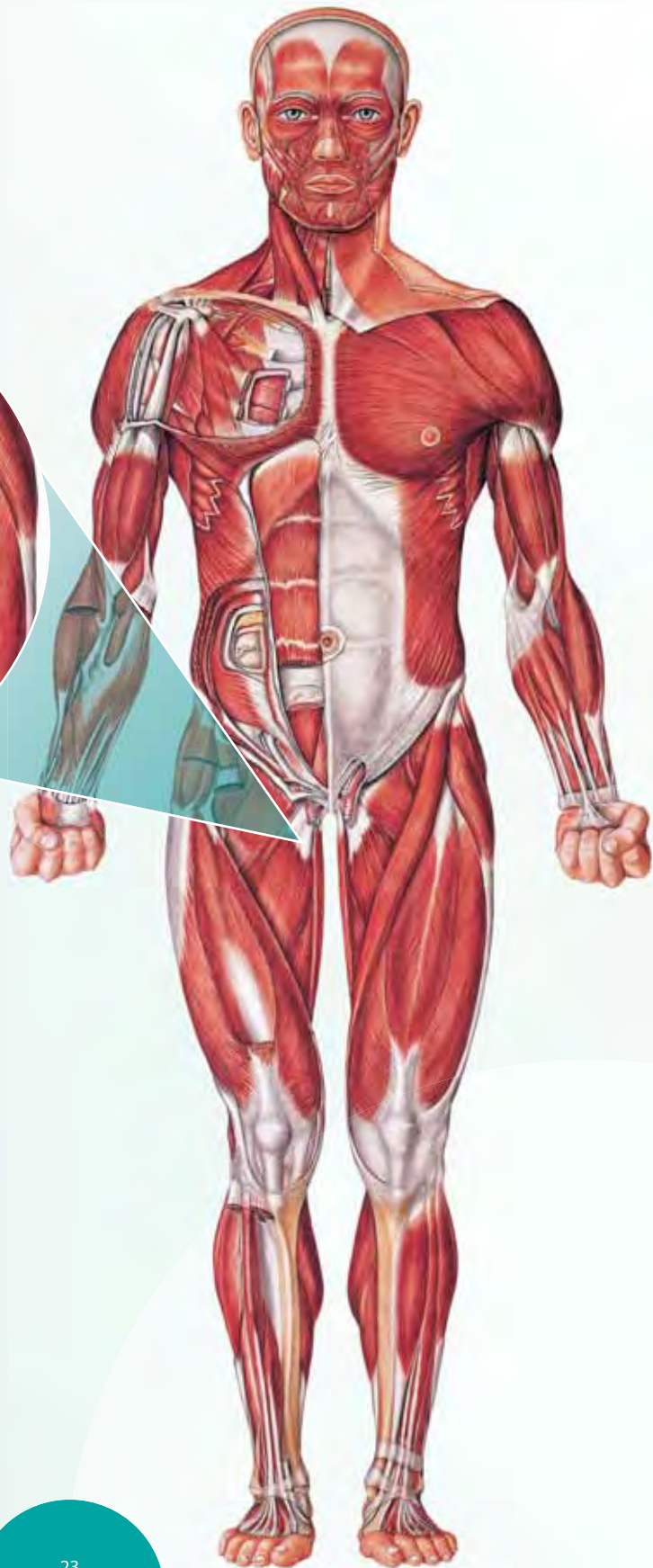
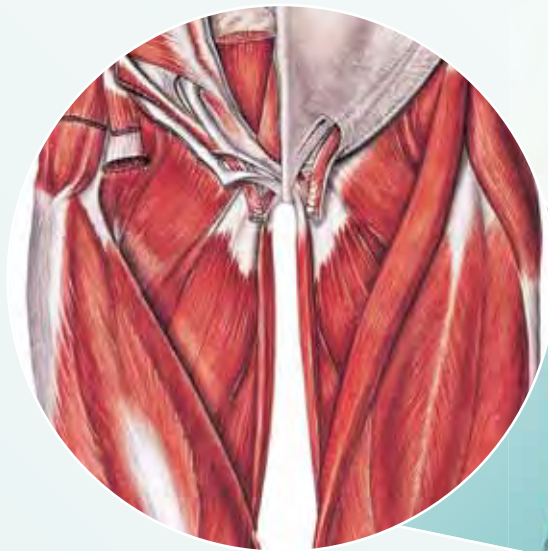
Inuup Saanga

Hatqaq

Avant du corps



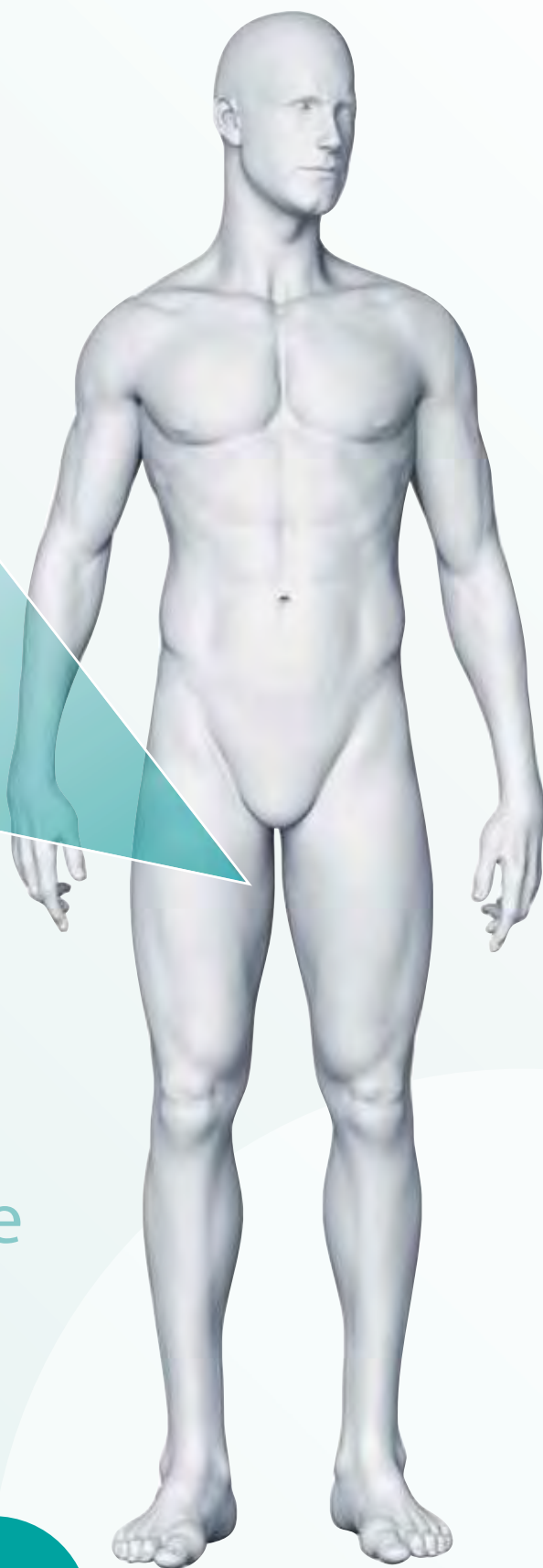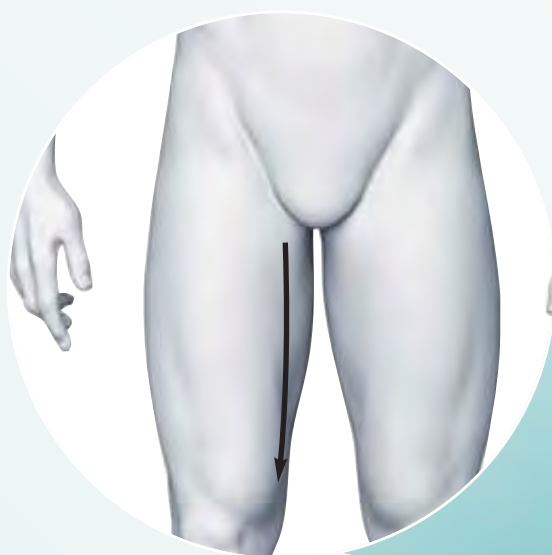# Groin



ᐱᑦᑎᑦᑎᑦᑎᑦ

Akunnaak  
Imitqutak  
Aine

# Inside of the Thigh



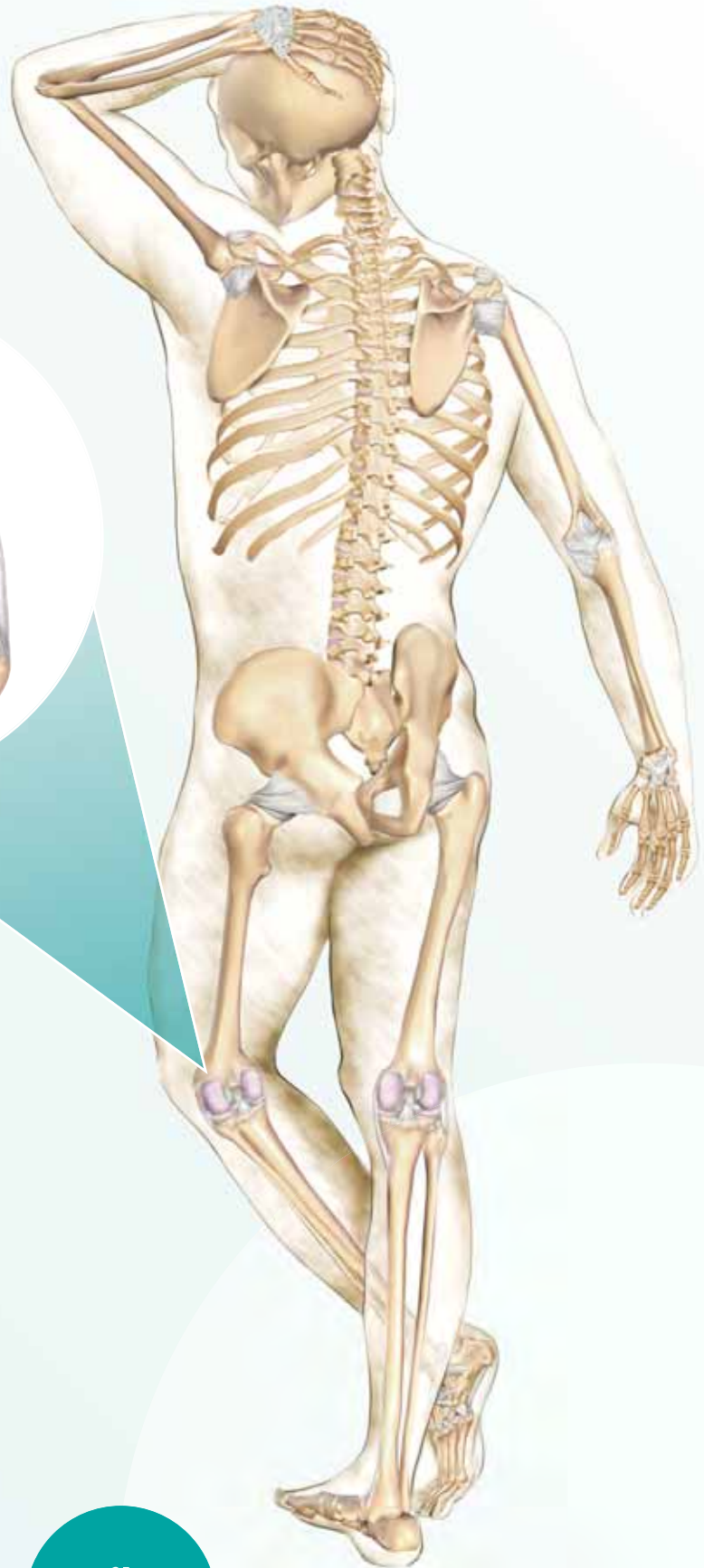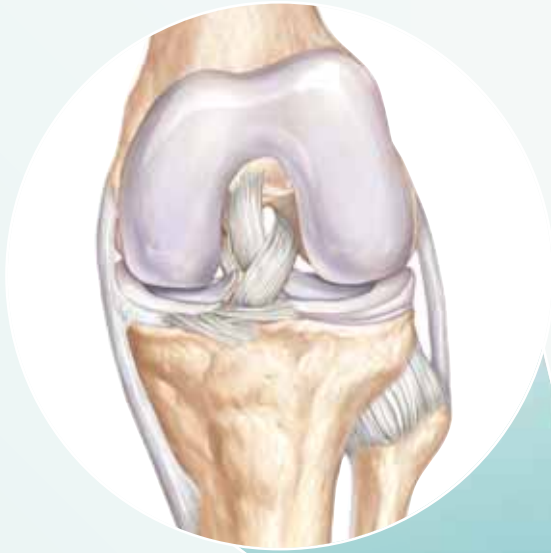Δϯϳᵇ

Ilutaak

Ilutak

Partie médiale  
de la cuisse

# Knee



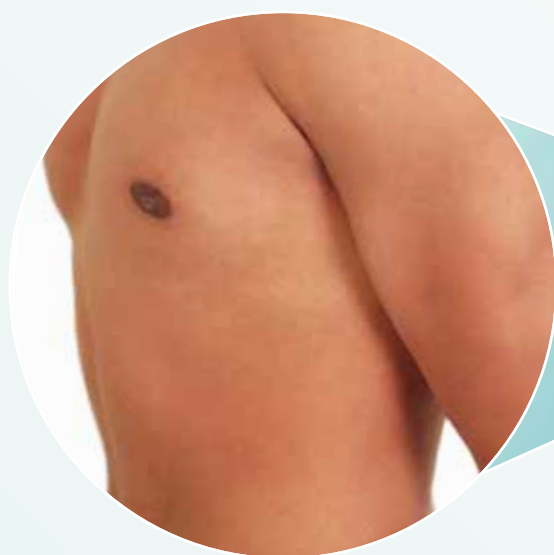ᐱᐅᐅᐅᐅ

Siiqquq

Hiitquq

Genou

# Lateral Side of the Chest



ካሪናቅ

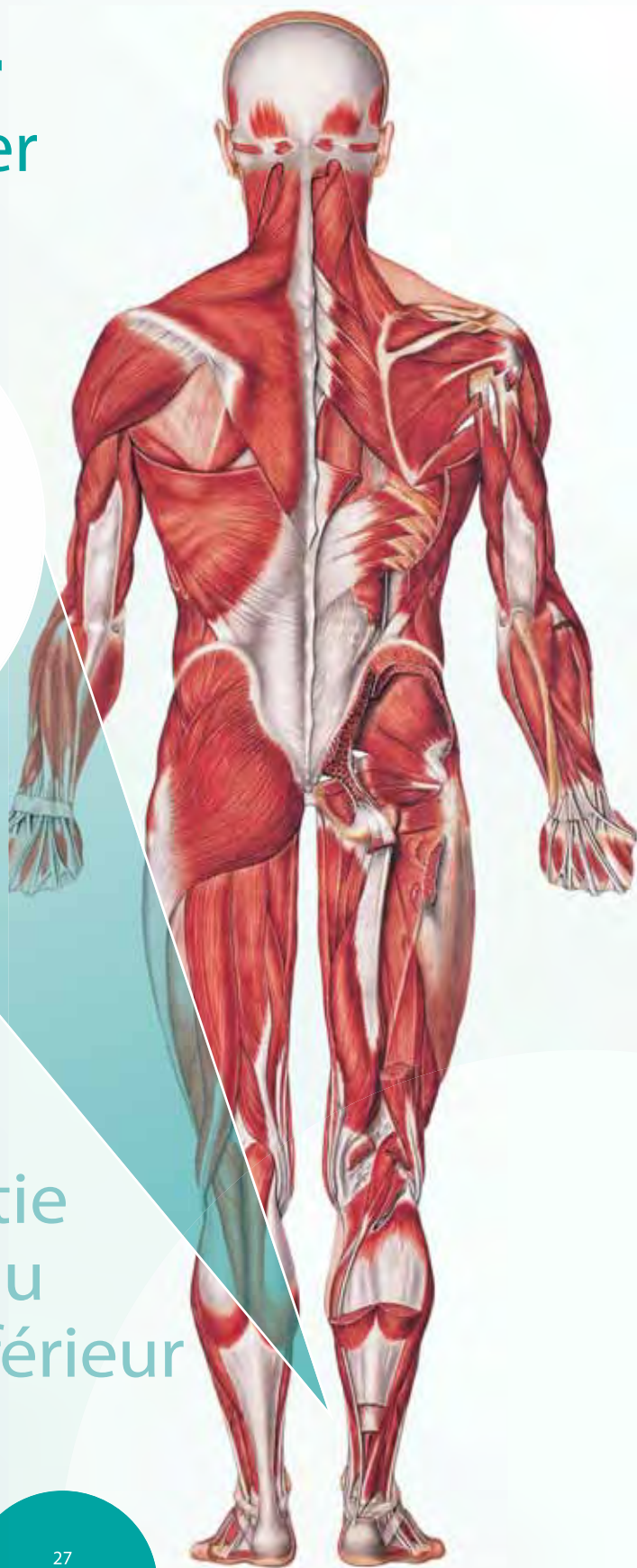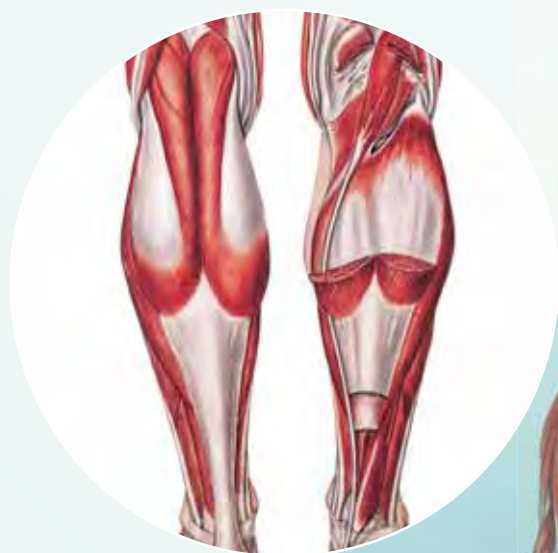
Saniraq

Haniqhuk

Partie latérale  
du buste



# Leg / Lower part of Lower Limb



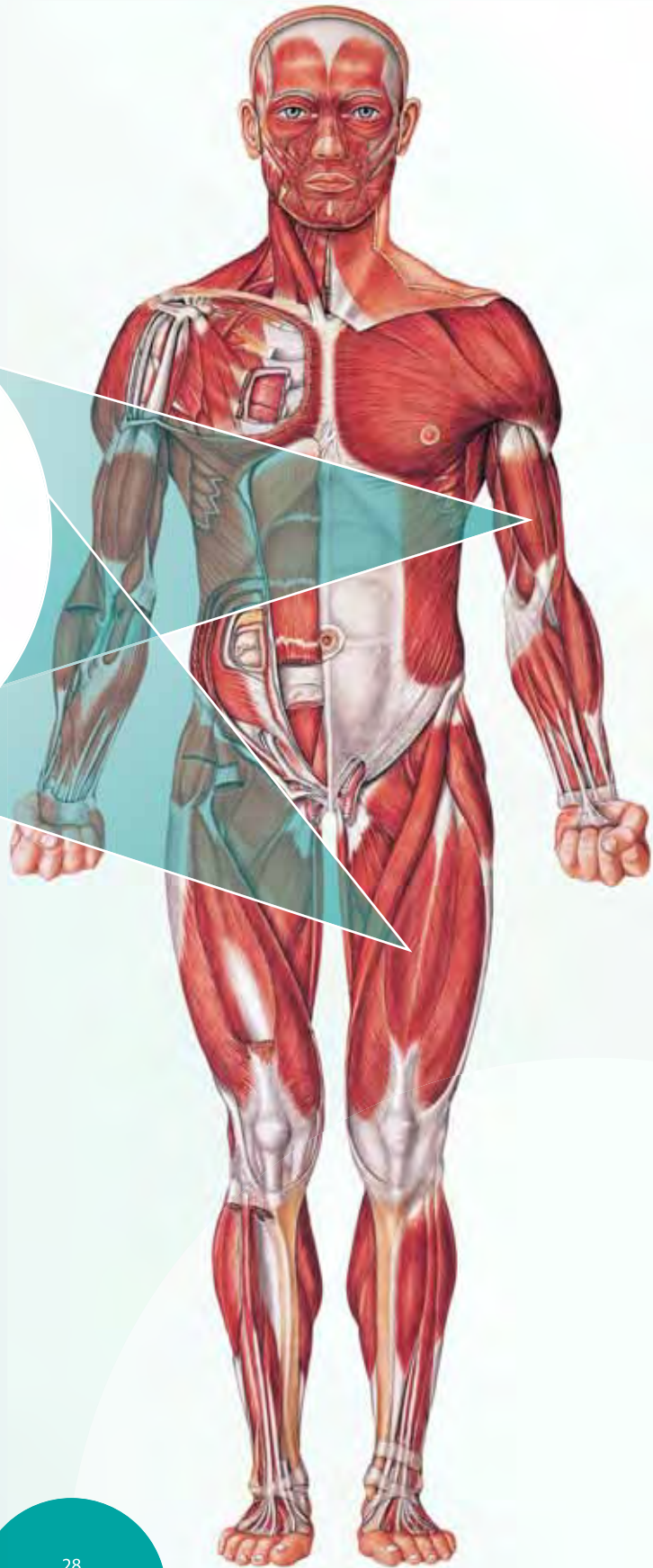
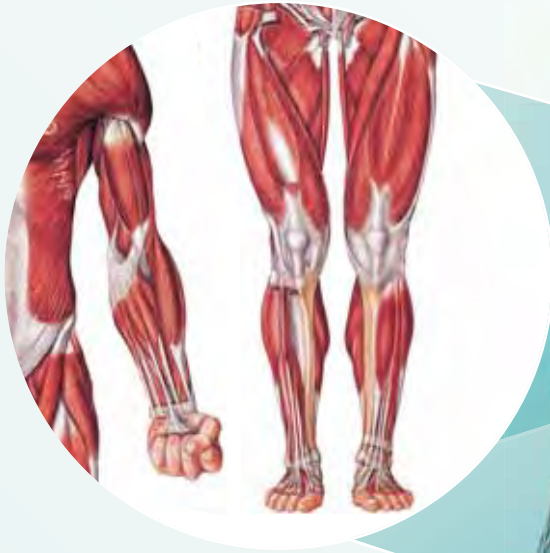ᑲᑎᑦᑲ

Kanaaq

Atiraq

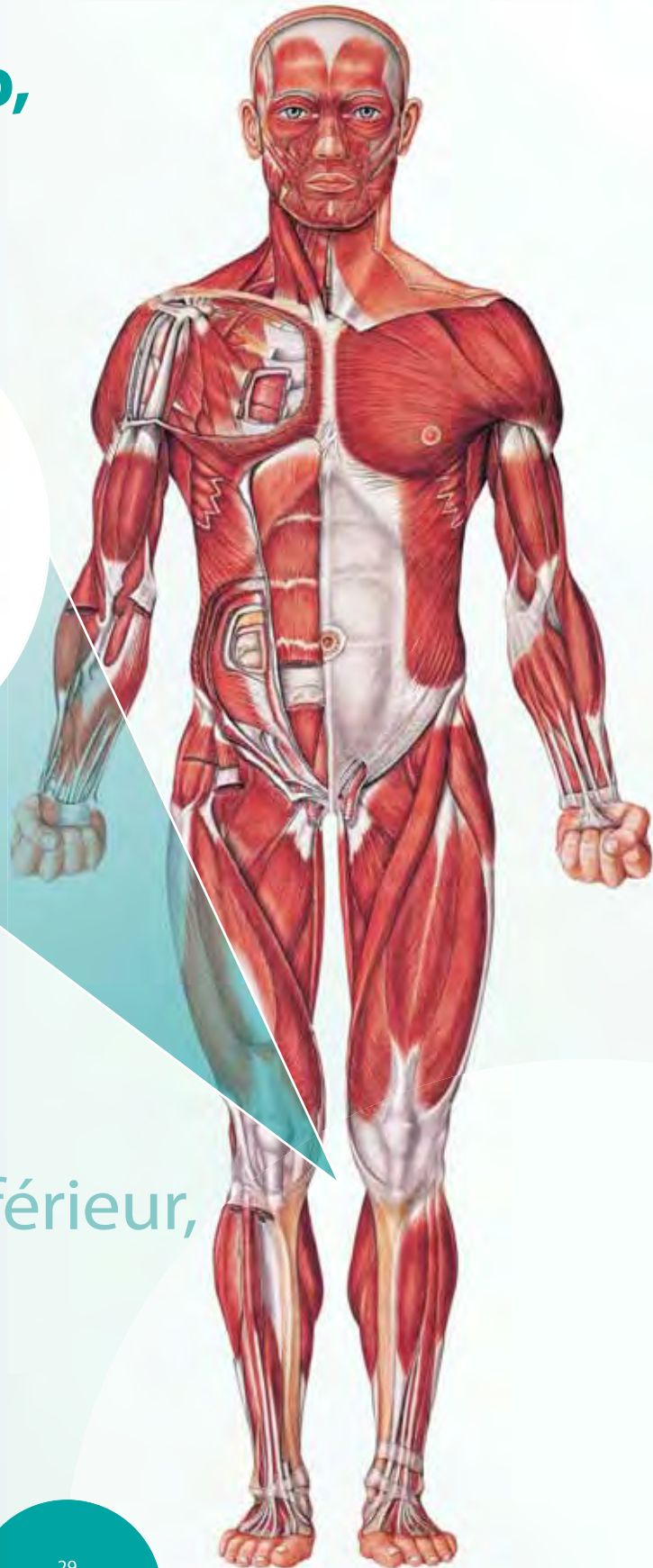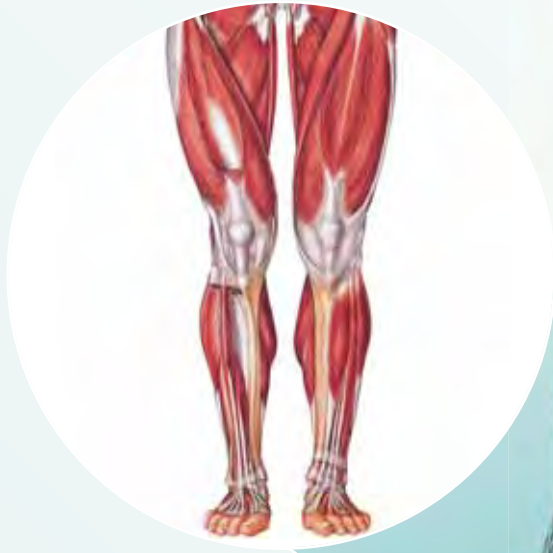Jambe, partie  
inférieure du  
membre inférieur

# Limbs



ᐱᐅᐅᐅᐅ  
Avatit  
Avatit  
Membres

# Lower Limb, Leg



♂▷

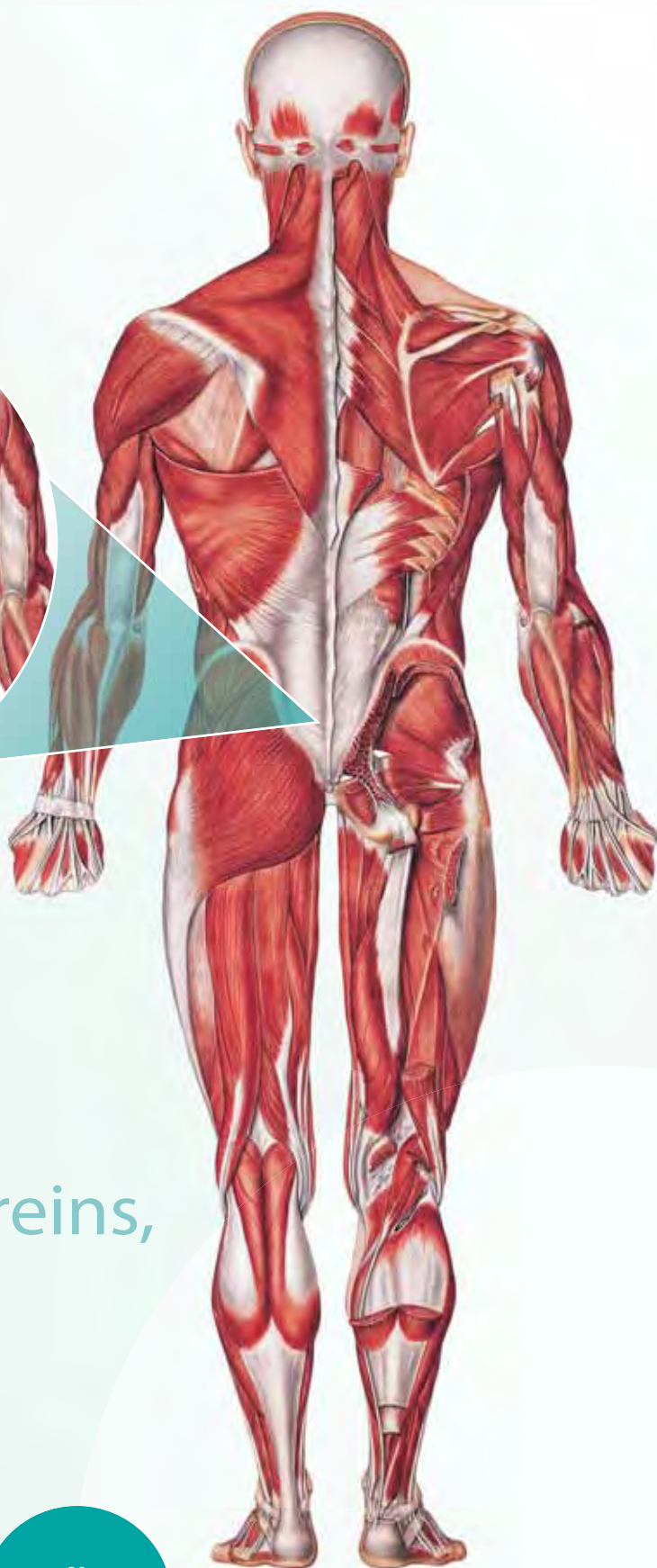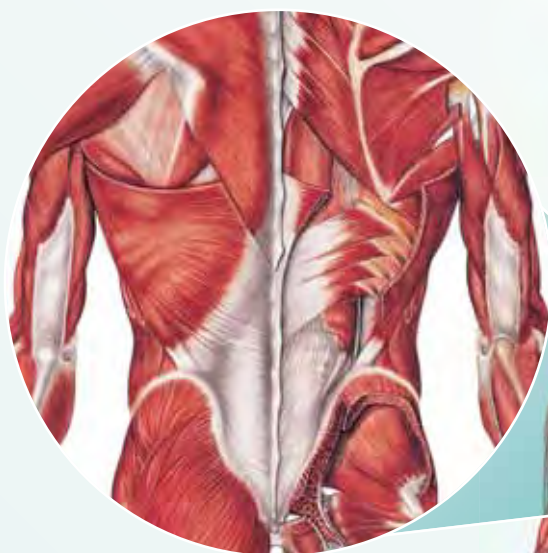Niu

Atiraq

Membre inférieur,  
jambe



# Lower Lumbar



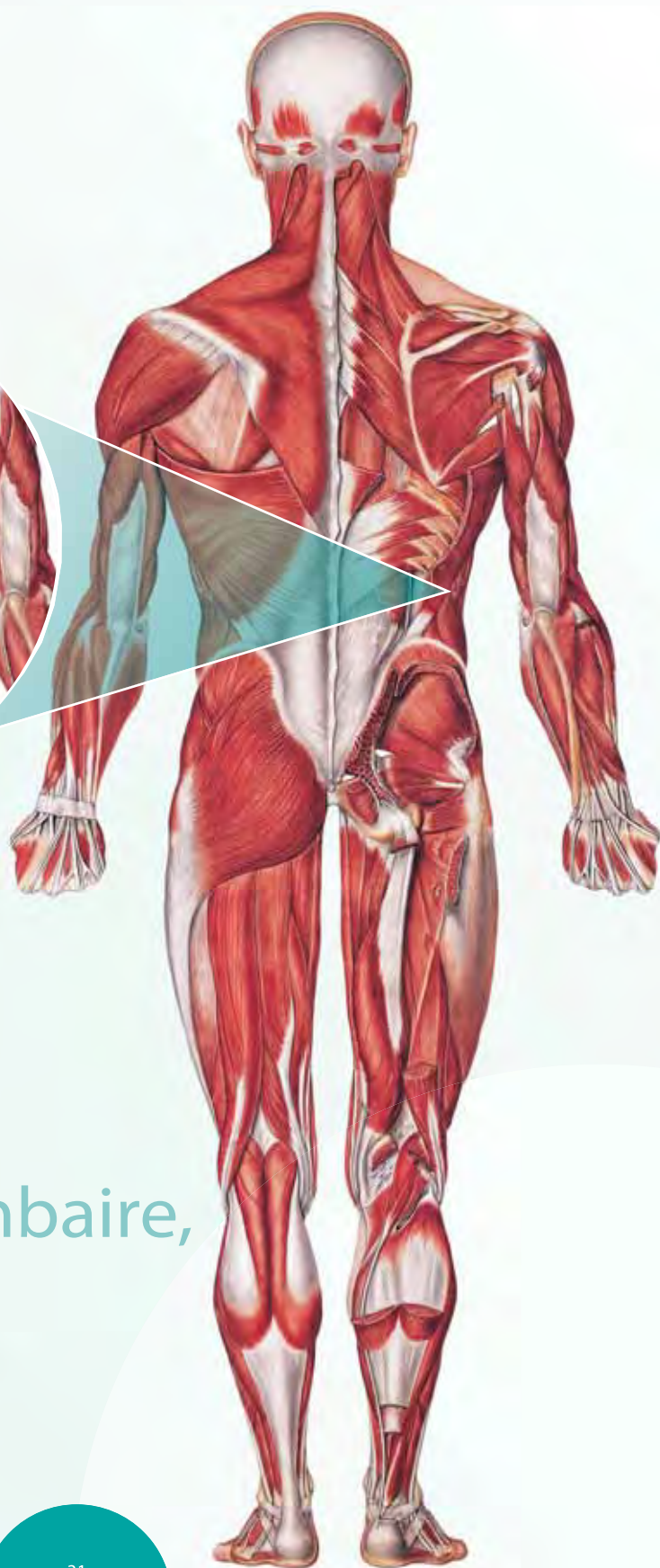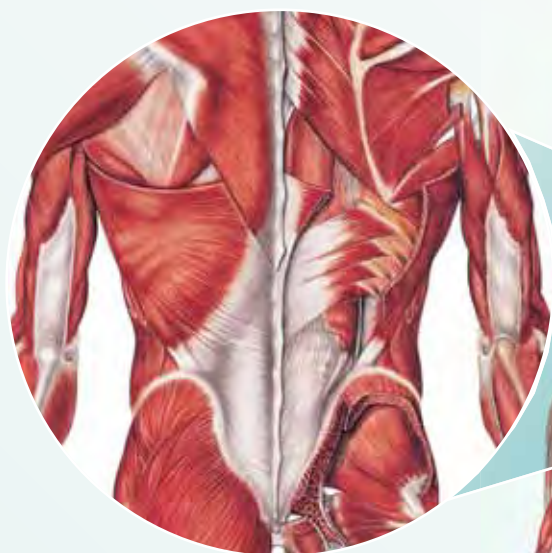ᑭᑭᑭᑭ

Qitiq

Qitiq

Chute des reins,  
taille

# Lumbar Region



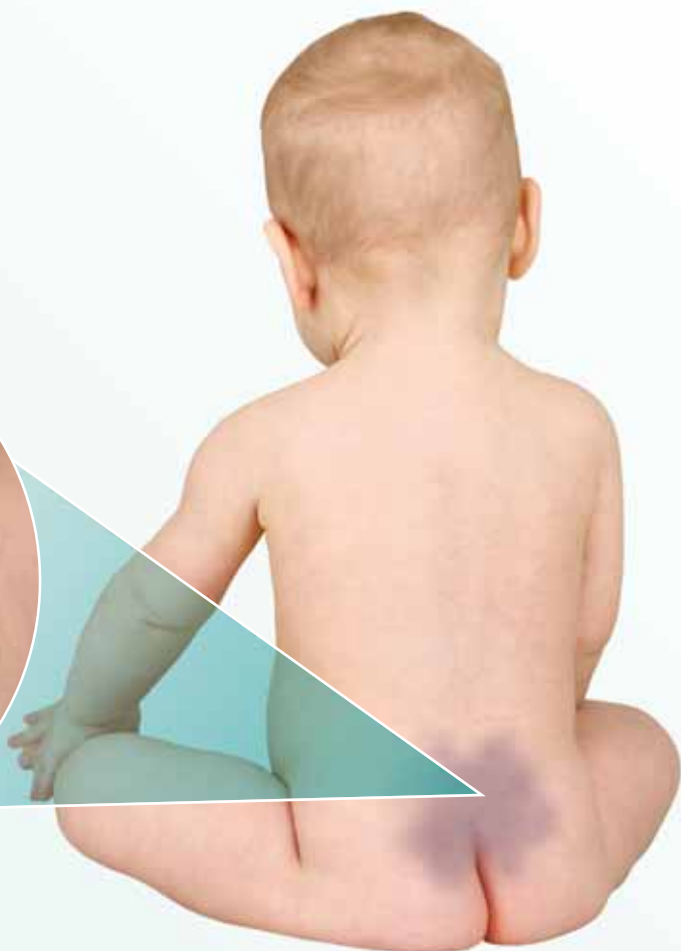
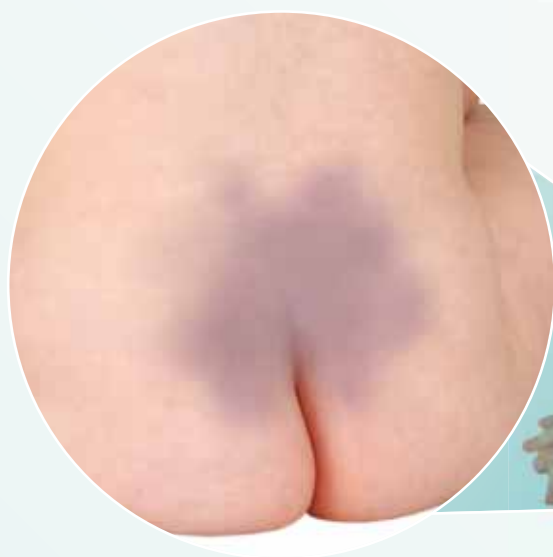ԺԿՈՏԳԵ

Kuttiniq

Kuuttiniq

Région lombaire,  
lombes

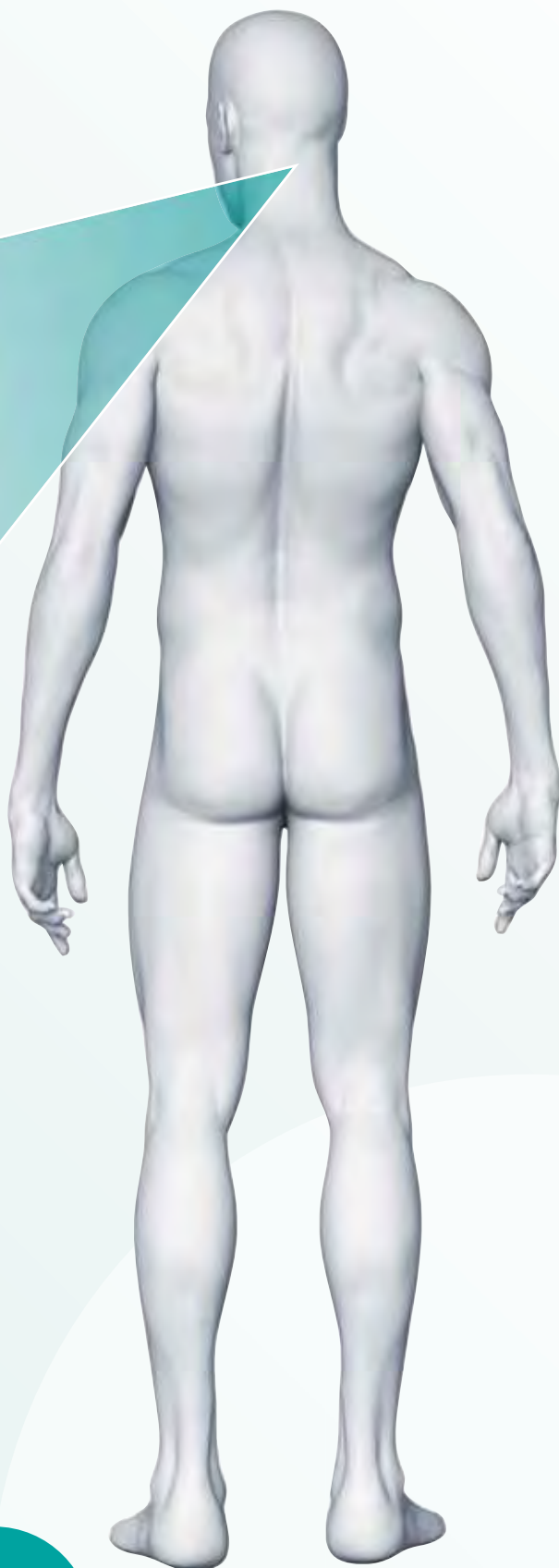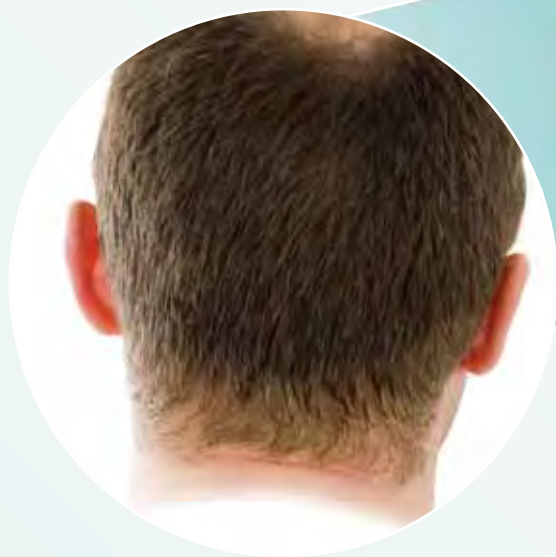# Mongolian Spot



ᠠᠨᠠᠨᠠᠨᠠᠨᠠᠨᠠ  
ᠠᠨᠠᠨᠠᠨᠠᠨᠠᠨᠠ

Itirviluani  
Sunnguujannguaq  
Tunguyurniq  
Tache pigmentaire

# Nape of the Neck



نَافِيس

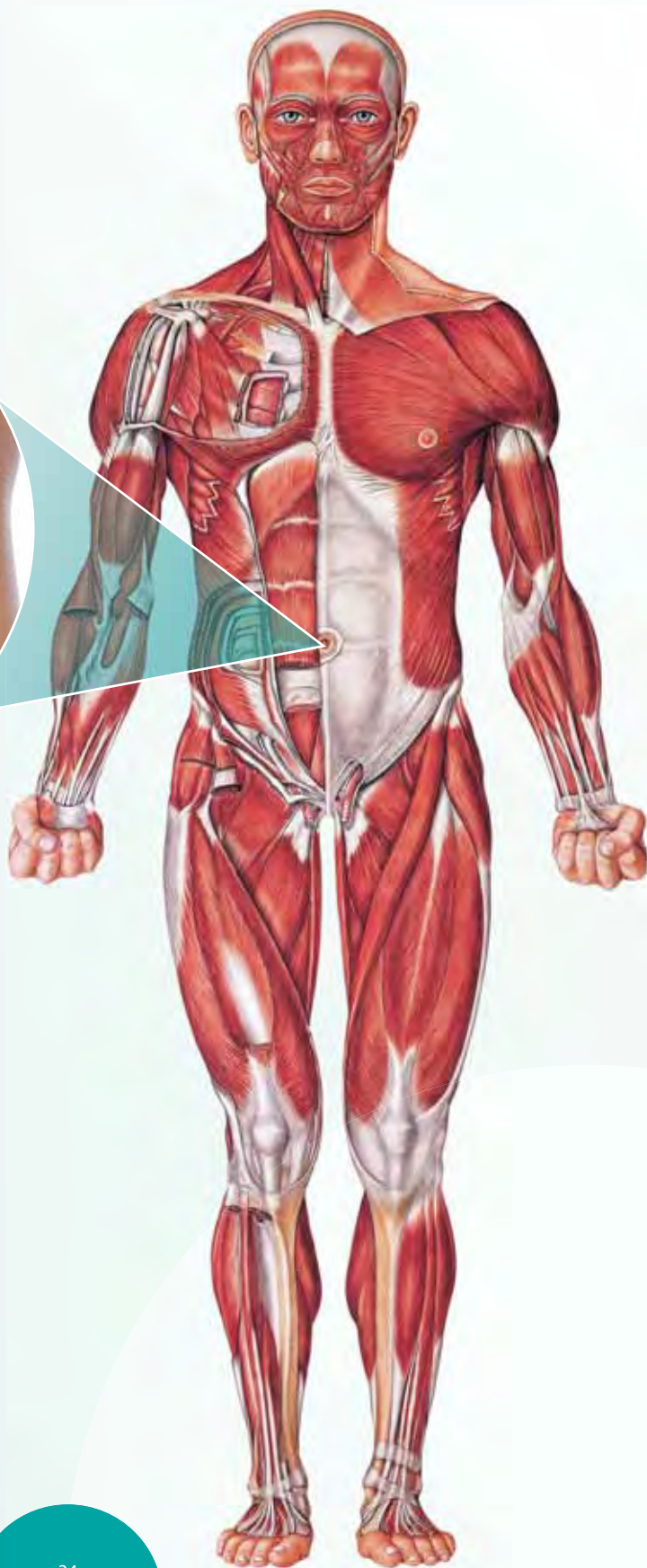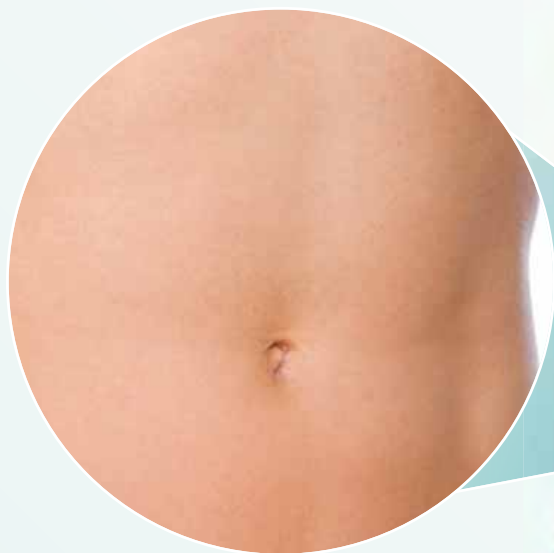Tunusuk

Tunuhuk

Nuque



# Navel / Umbilicus



ᲒᲑᲘᲗᲑ

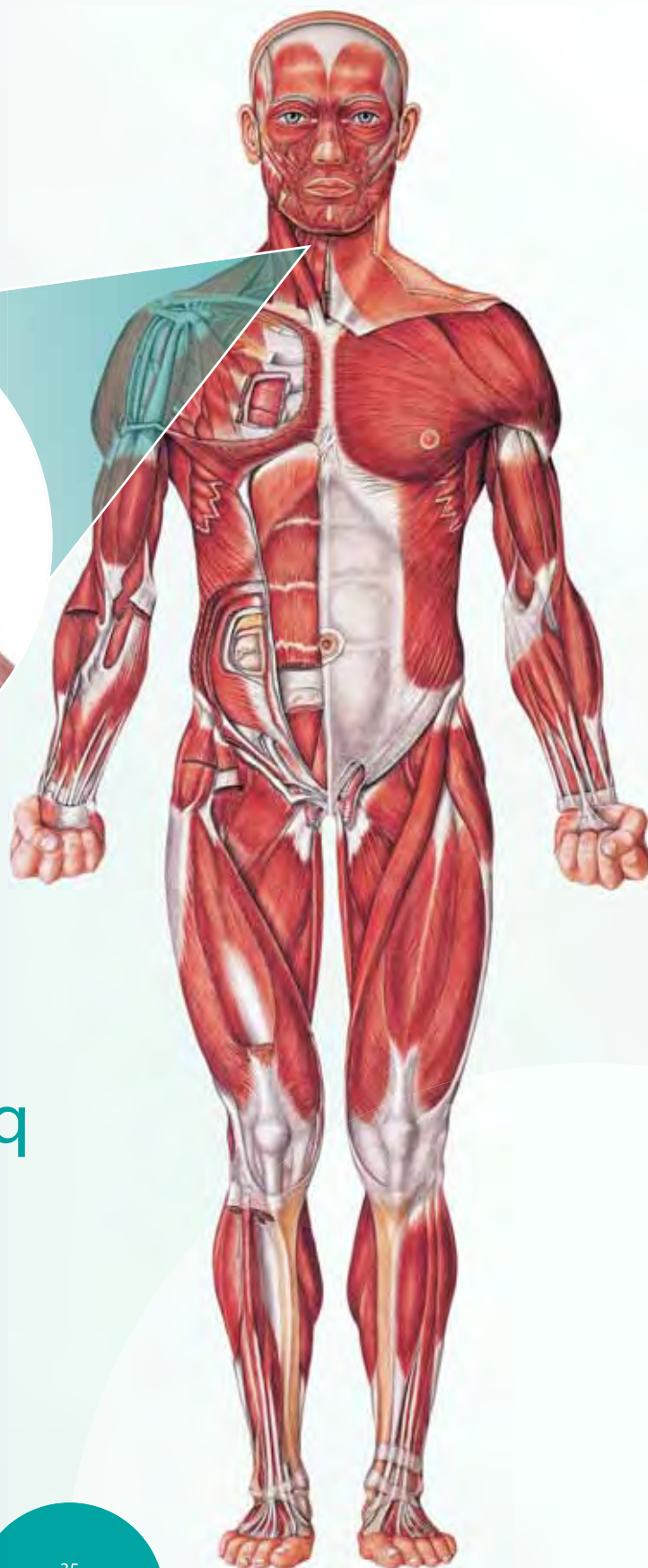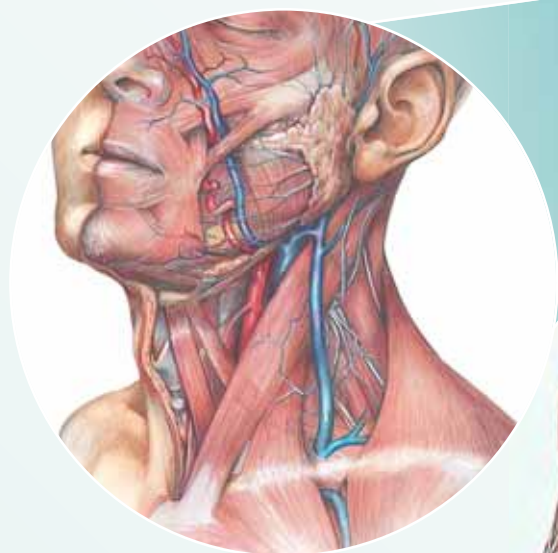
Qalasiq

Qalahiq

Nombril ou  
ombilic



# Neck



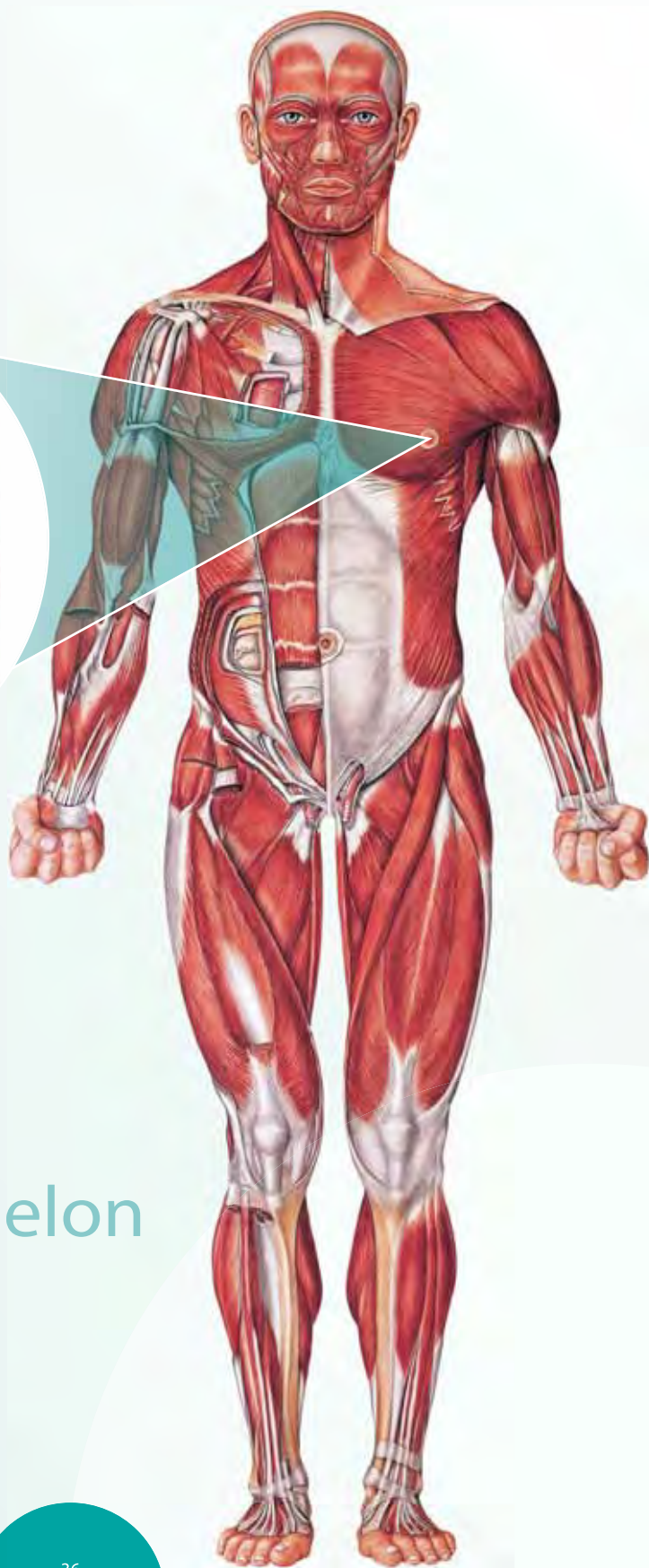
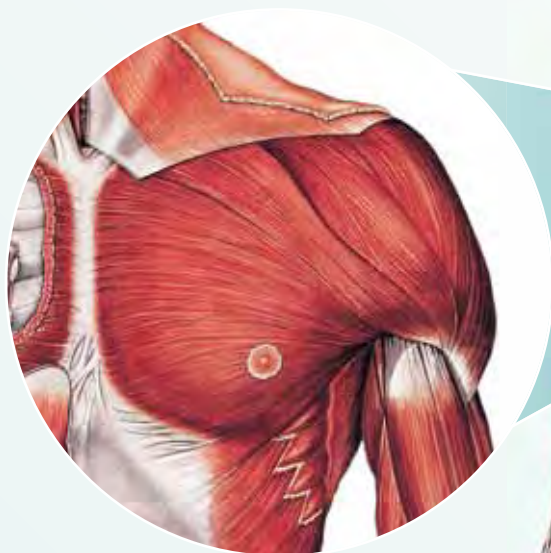
ᄒᄒᄒᄒᄒᄒᄒᄒ

Qungasiq

Qunguhiniq

Cou

# Nipple



ᐱᐱᐅ

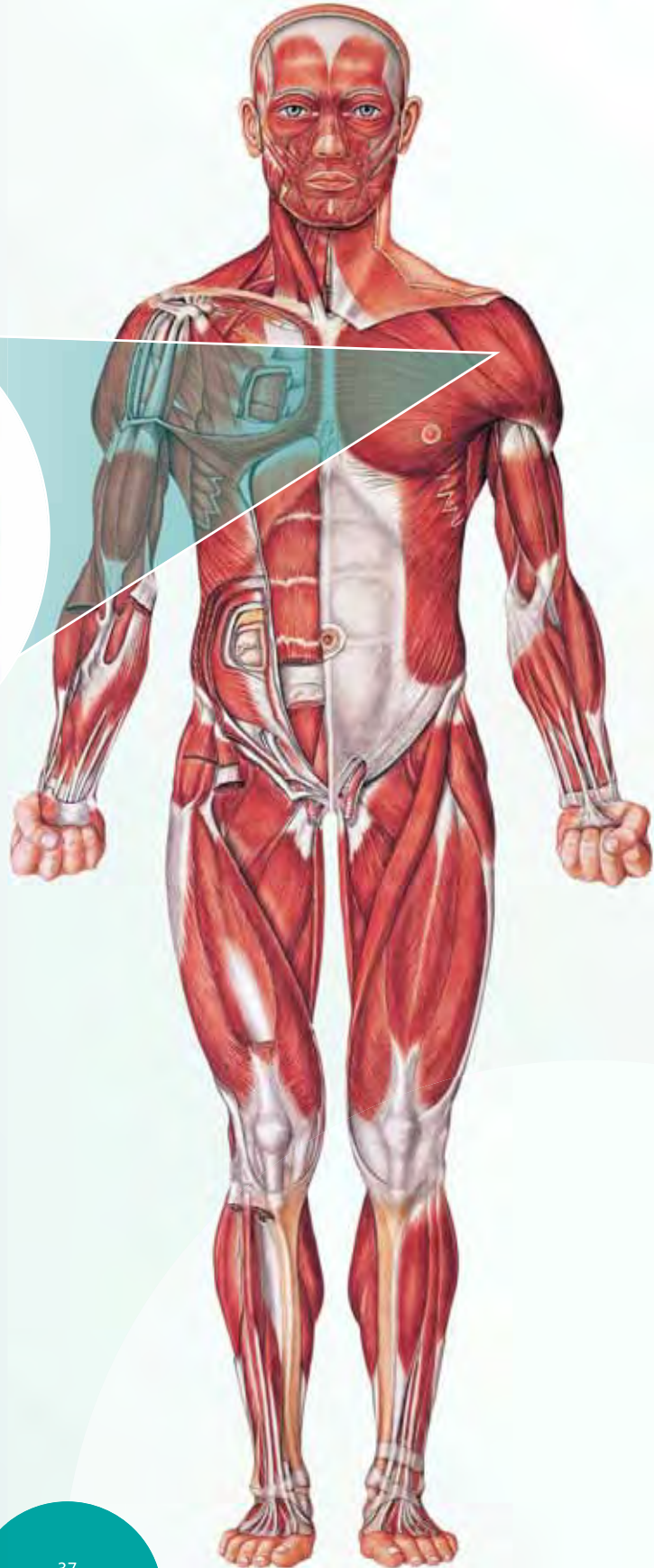
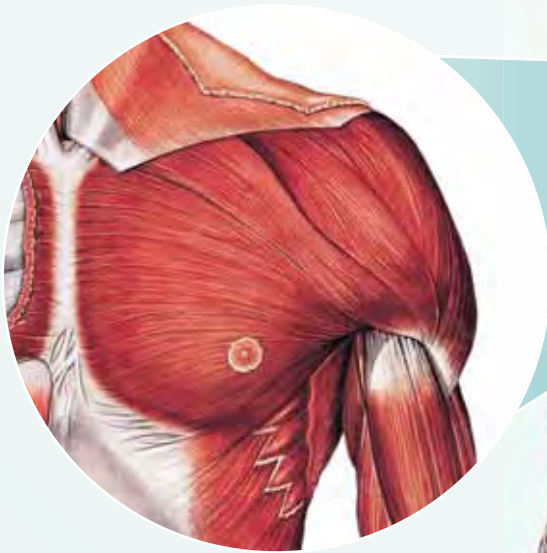
Mulik

Muluk

Téton mamelon



# Shoulder



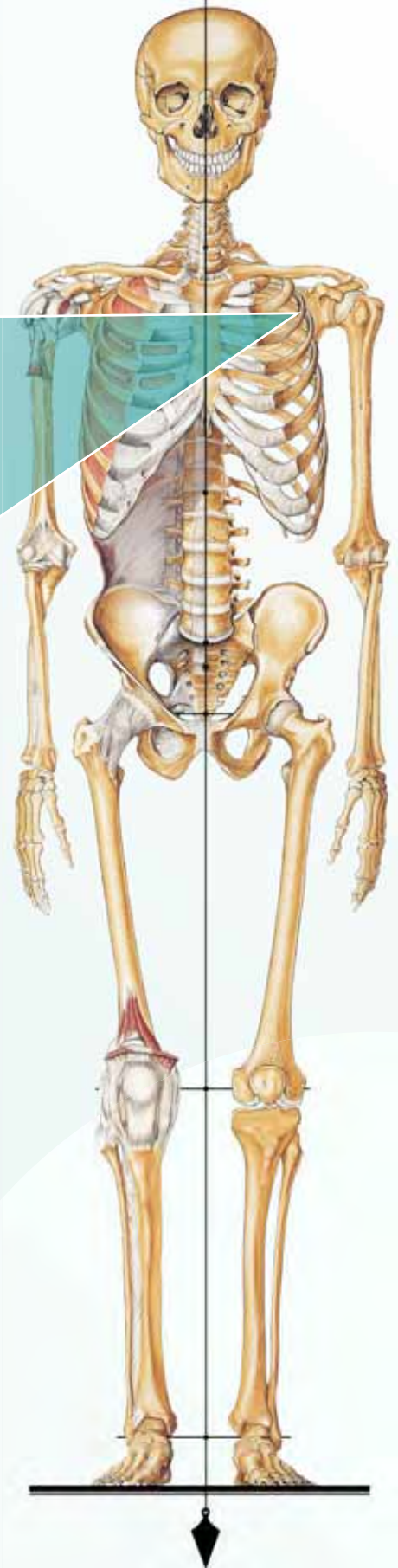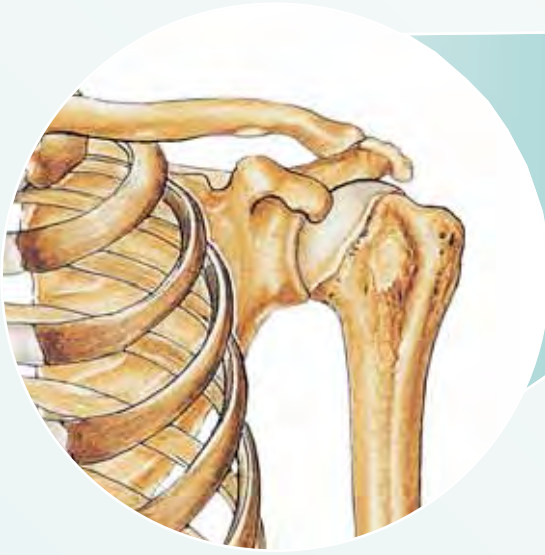
ἄΔ

Tui

Tuik

Épaule

# Shoulder Hollow

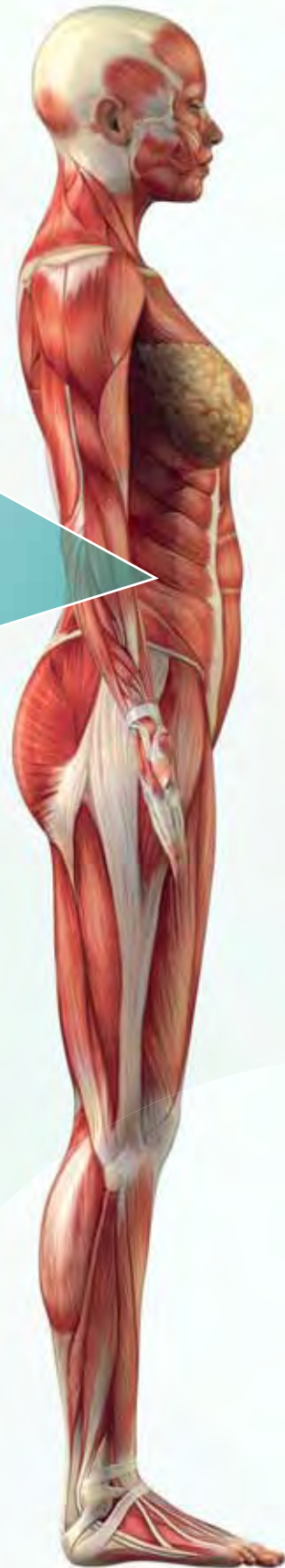
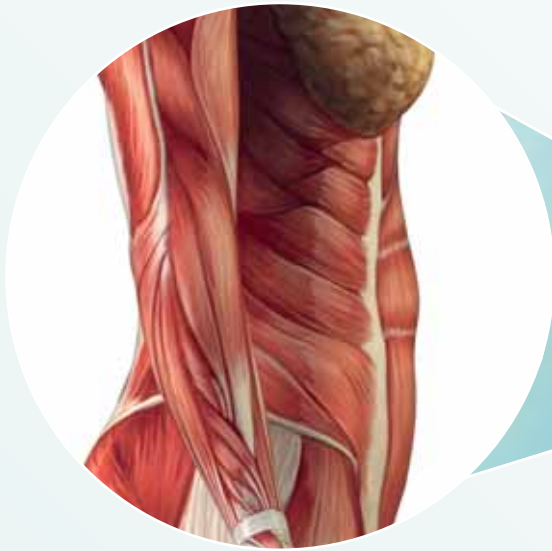
Irji

Angmaniq

Côté de la tête,  
creux de l'épaule

# Side of the Body, Flank



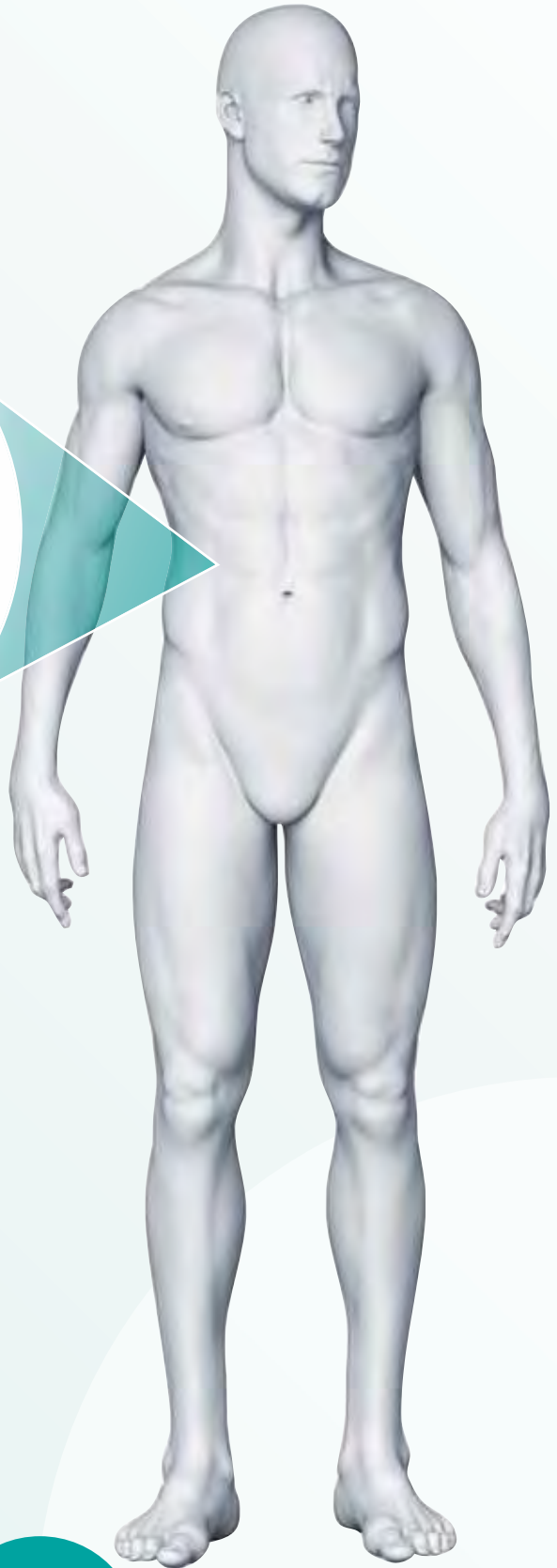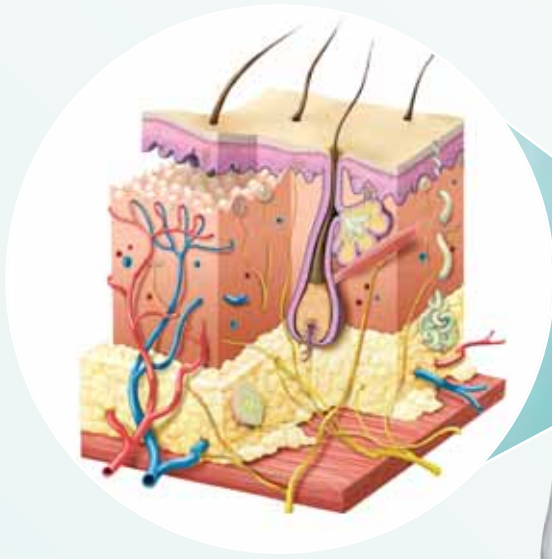
ሴናራቅ

Saniraq

Haniraq

Côté, flanc

# Skin



▷Δσ<sup>b</sup>

Uvinik

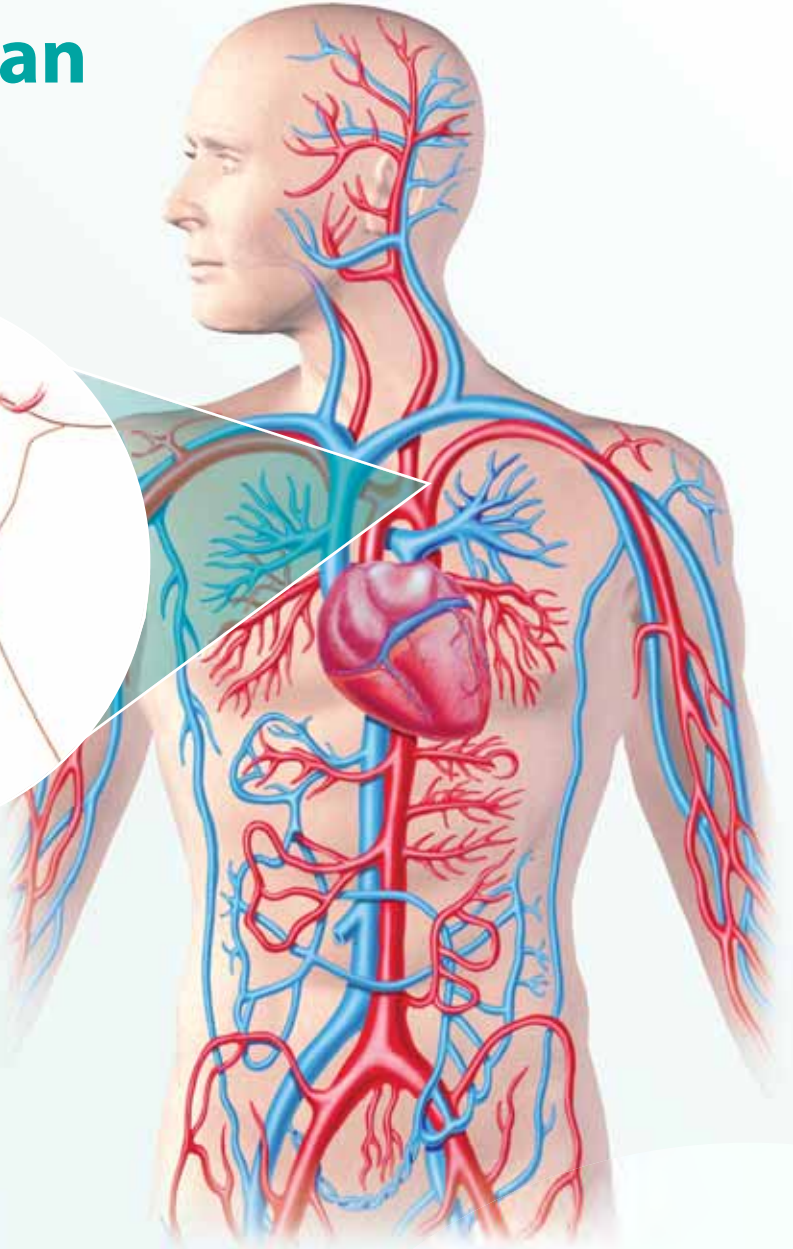
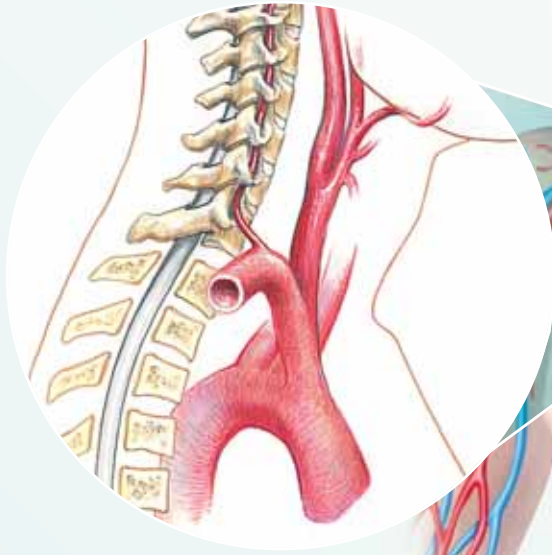
Uvinik

Peau





# Subclavian Fossa



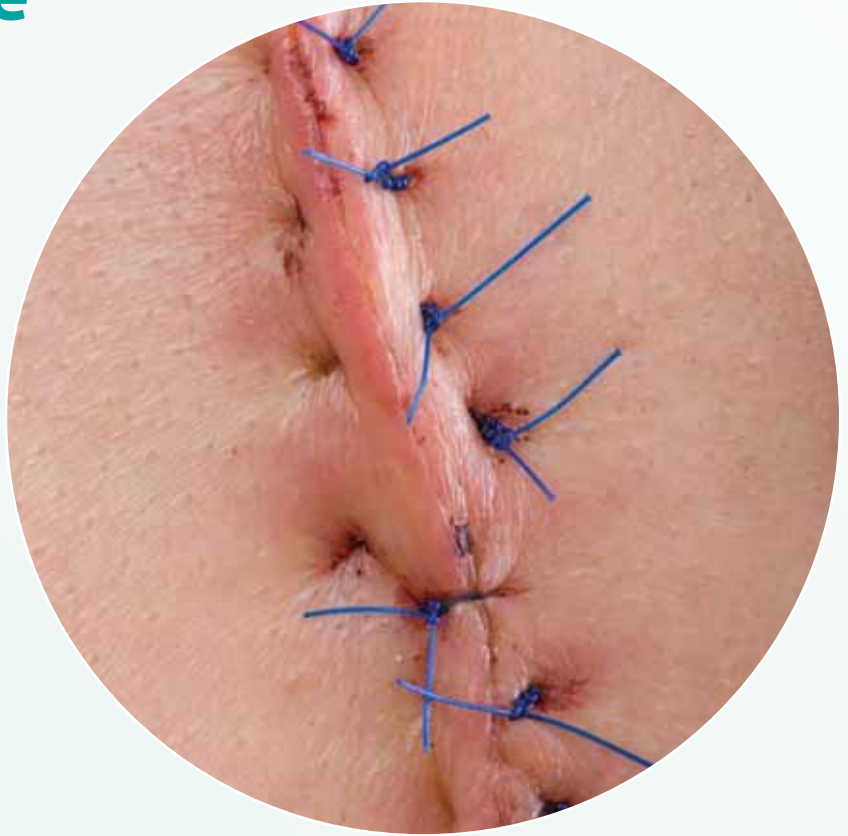
ΔρϑΔβ

Isirviik

Itirvik

Salières

# Suture



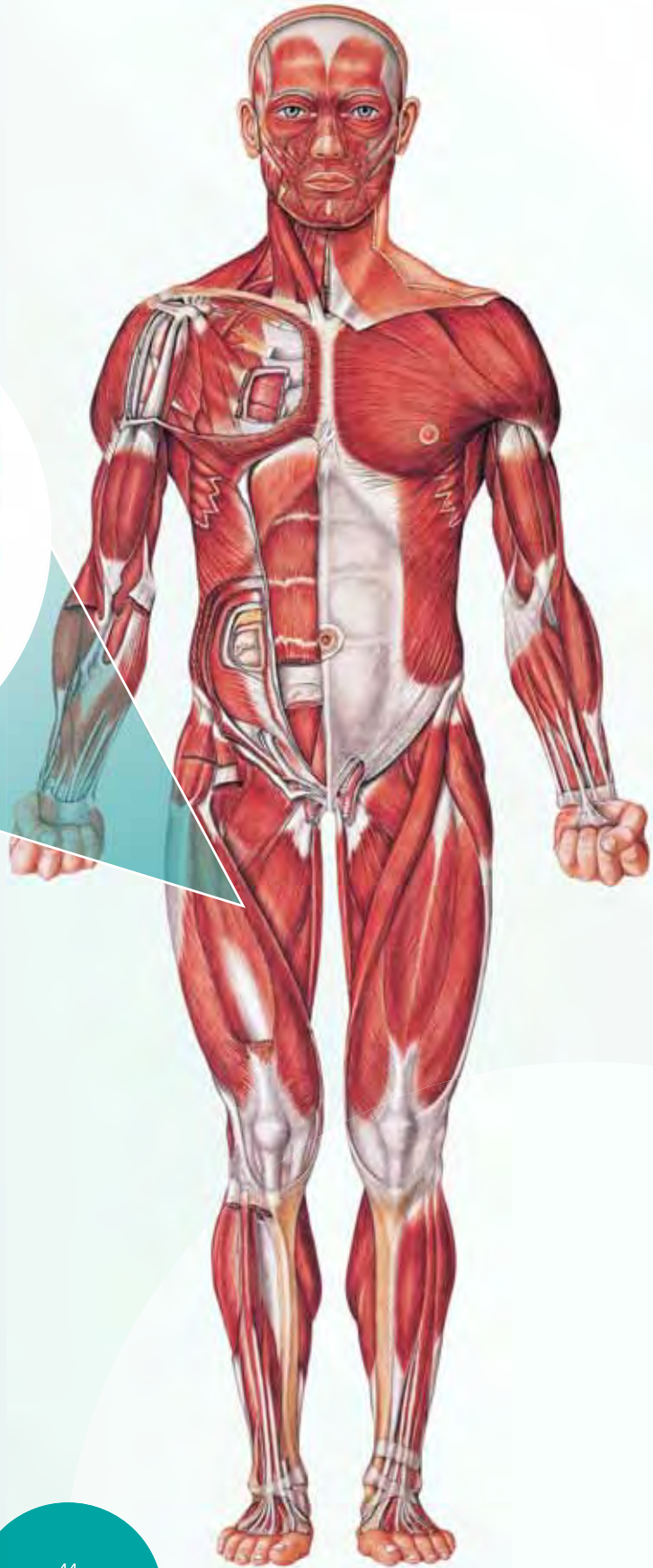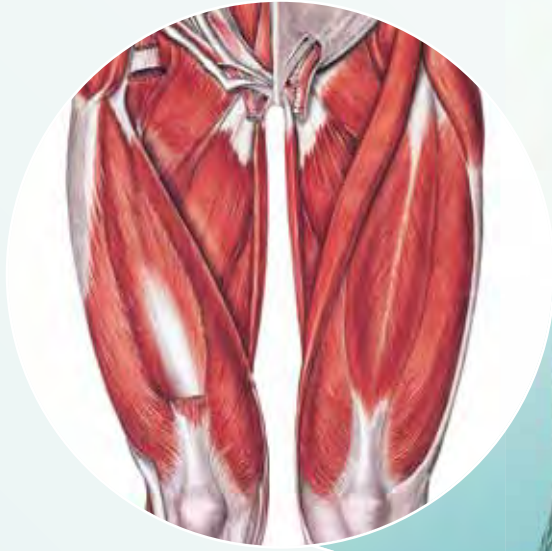𐌱𐌶

Kilu

Kiluit

Suture

# Thigh



ᠶᠢᠨᠲᠡᠭᠦ

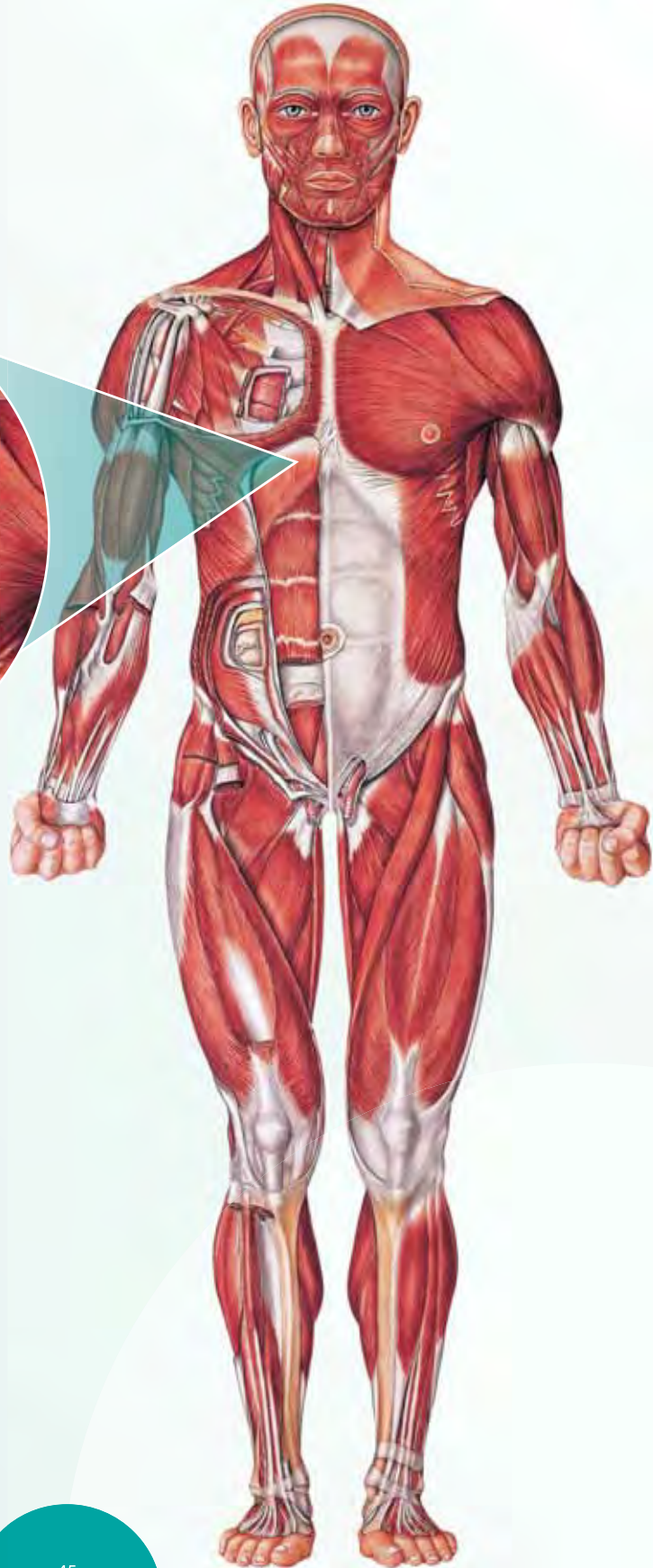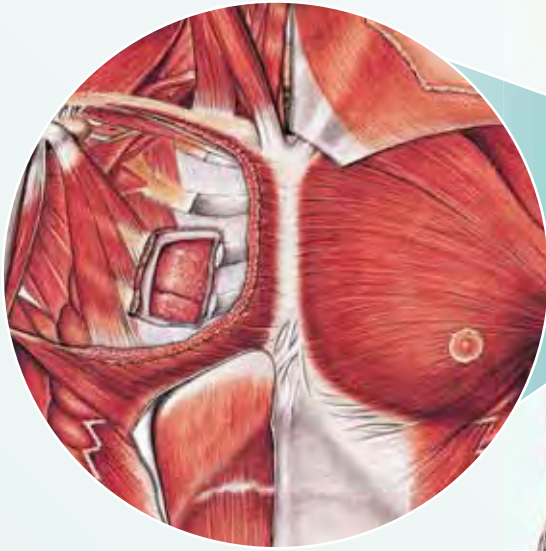
Qukturaq

Mimiq

Cuisse



# Trunk



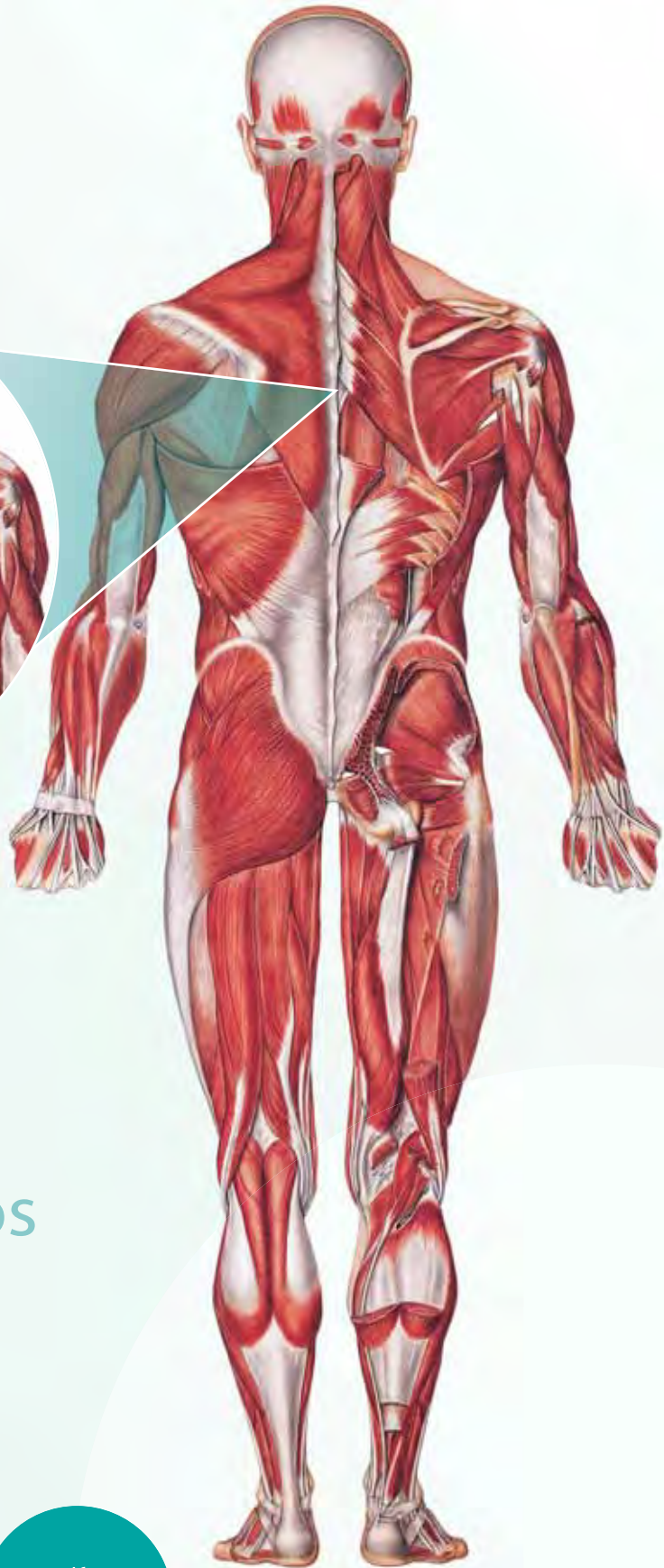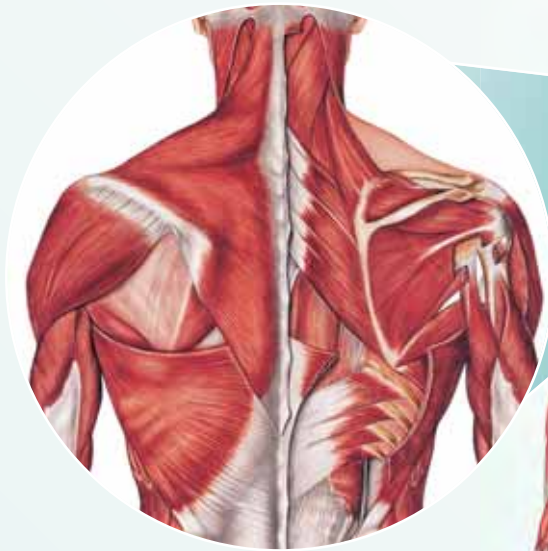ᐱᐱᐅ

Kiati

Qatiggaaq

Tronc

# Upper Back



ᐱᐱᐱᐱᐱ

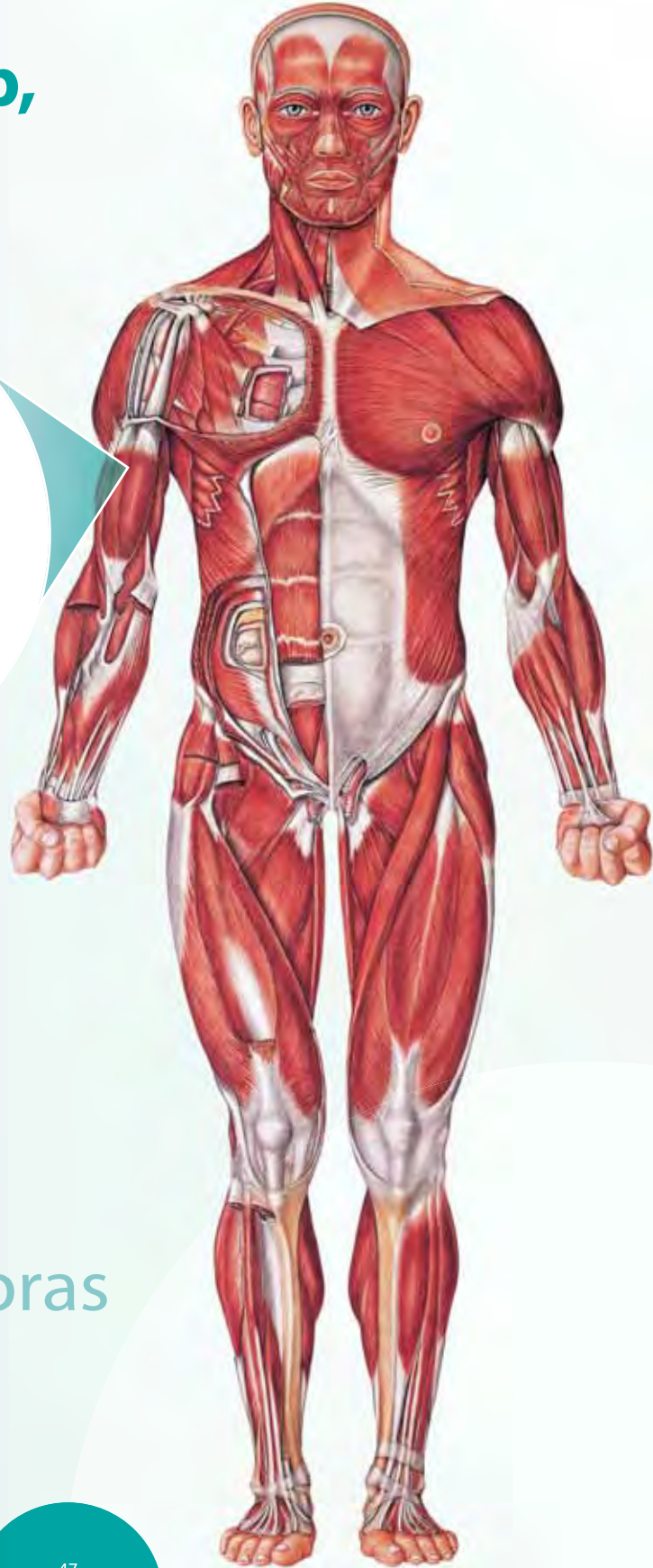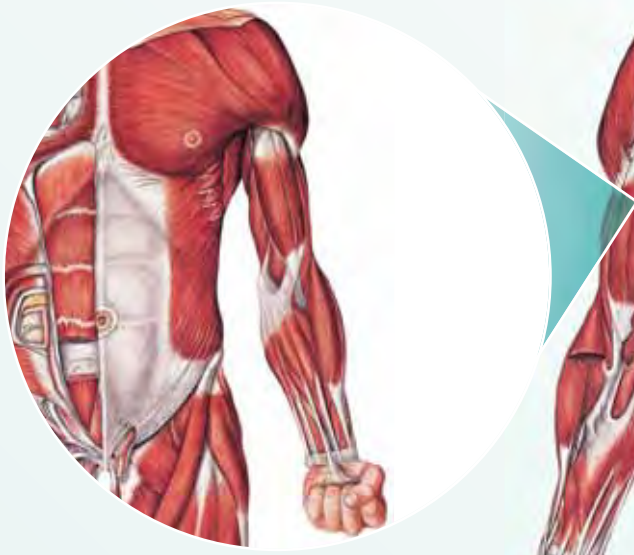Aariak

Aaridjak

Haut du dos



# Upper Limb, Arm



ᐱᐱᐱᐱᐱᐱᐱᐱ

Aksaqquq

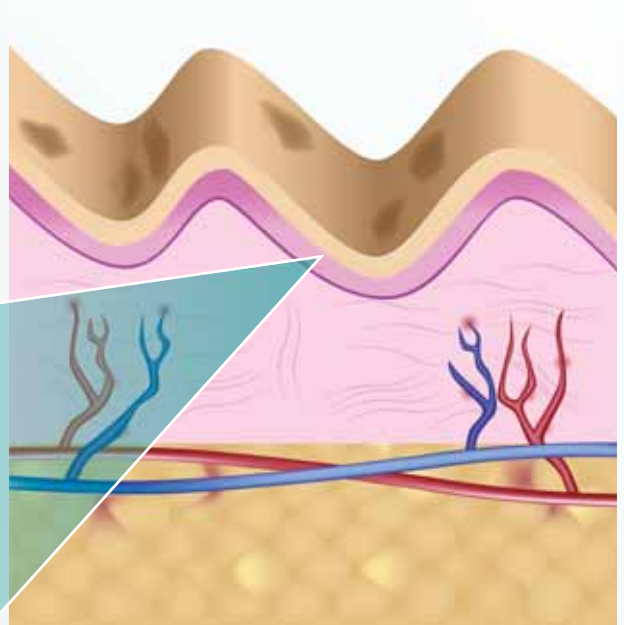
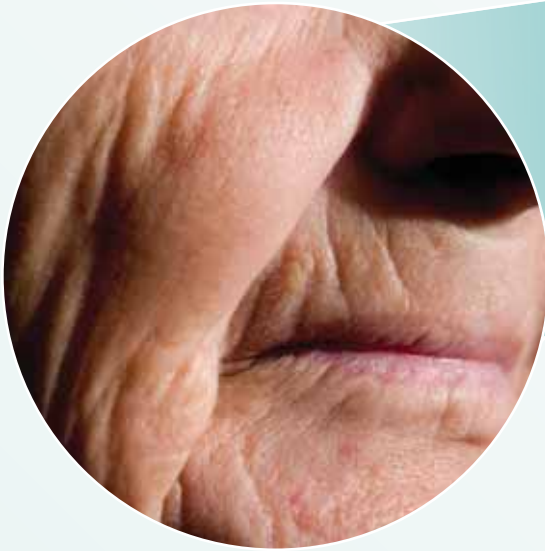Taliq

Membre  
supérieur, bras





# Wrinkle



ΔJ<sup>c</sup> 5<sup>9b</sup>

Imulluq

Imullungniq

Ride



# Feet/Hands

ᐃᓯᑲᑲᑦ / ᐃᑭᑭᐃᑦ

Isikkat/Aggait

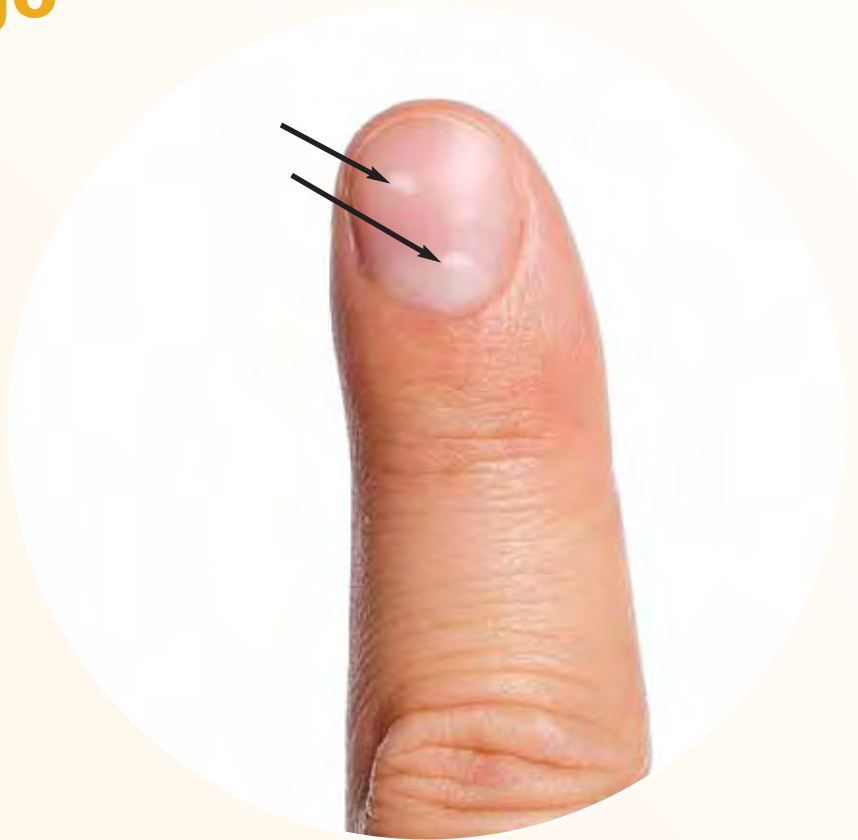
Itikkat/Algak

Pieds / Mains





# Albugo



ᠳᠦᠫᠢᠭᠤ

ᠬᠤᠴᠢᠭᠤᠨᠠᠭᠢᠨᠢᠷᠠ

Kukiup

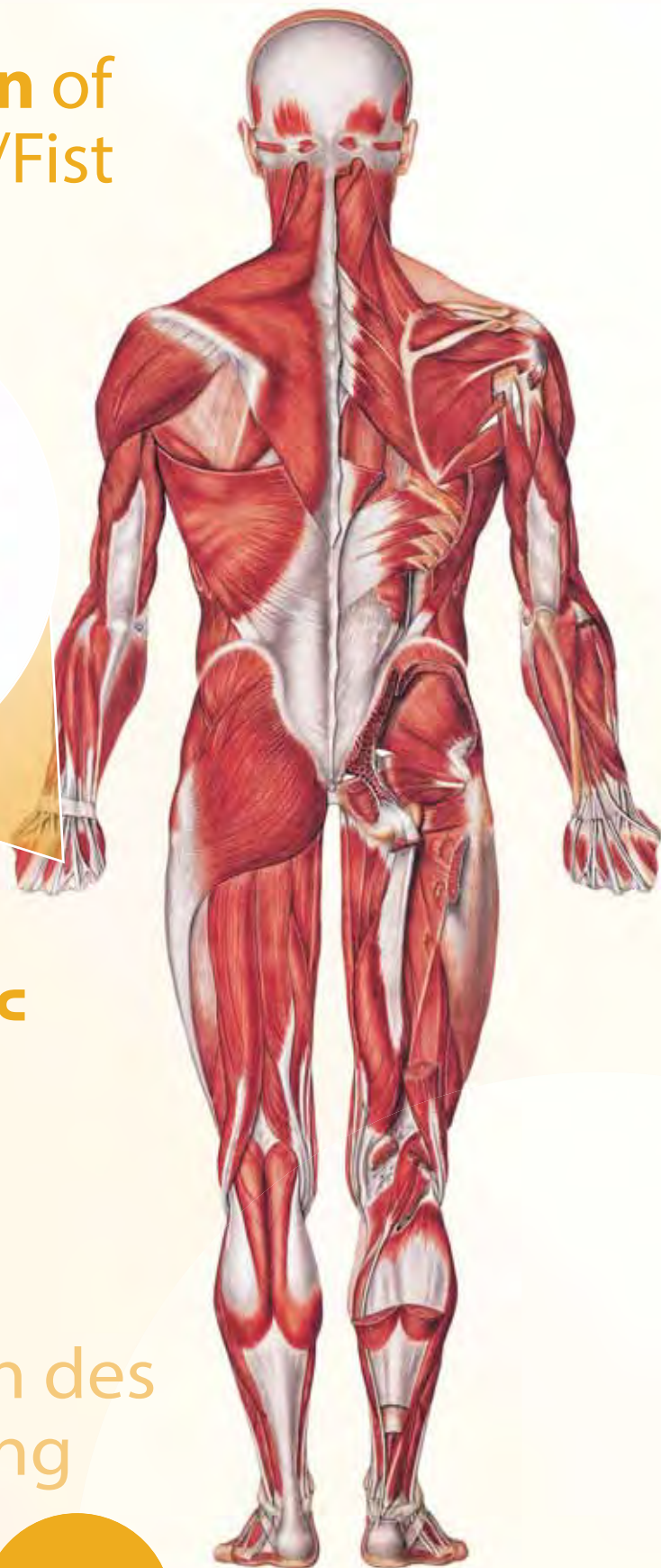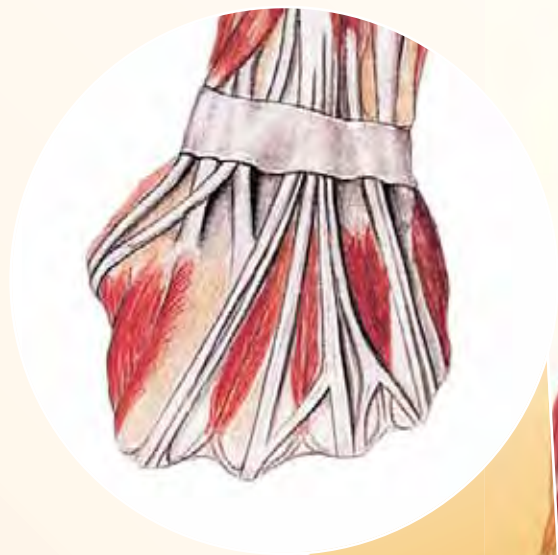Qakuqtagalaangit

Kukiup

Qakurnira

Albugo

# Articulation of the Fingers/Fist



ᐱᕐᕐᕐᐱᕐᐱ

ᐱᕐᕐᕐᐱᕐᐱᕐᐱᕐᐱ

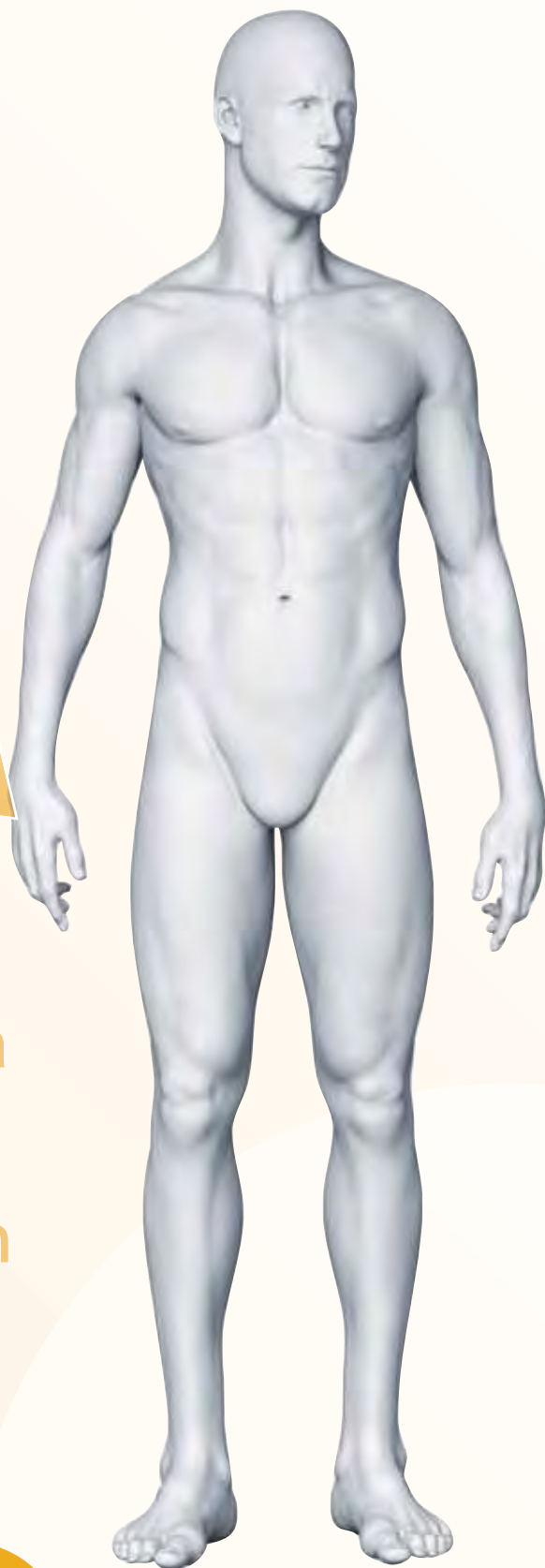Aggaup

Iqijarningit

Iqitaqtuq

Articulation des  
doigts, poing

# Back or Dorsum of the Hand



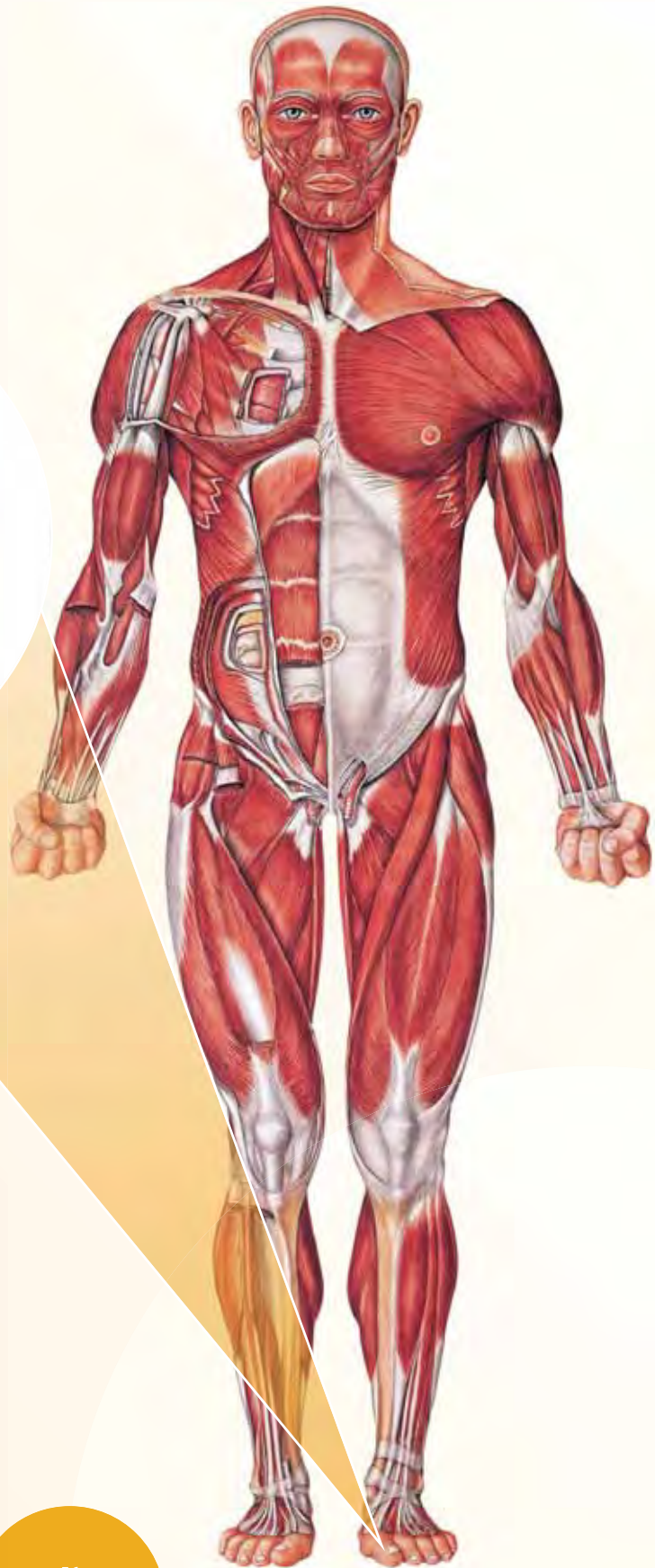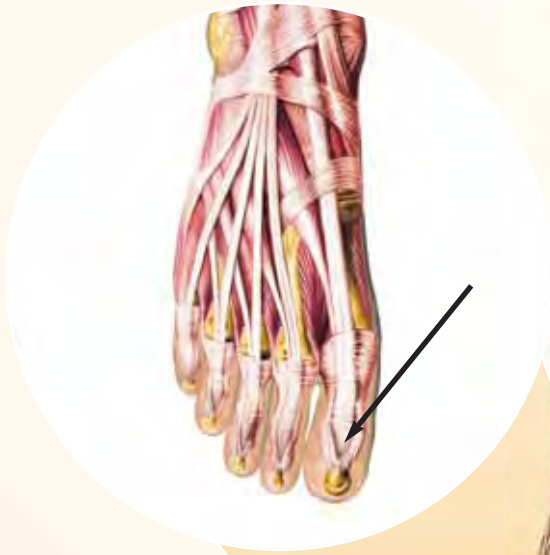ᐱᑭᑭᐱᑭ ᐅᑦᑎᑦᐱᑦ

Aggaup Tunua

Algaup Tunua

Dos de la main

# Big Toe



ᠮᠣᠩᠭᠤᠢ

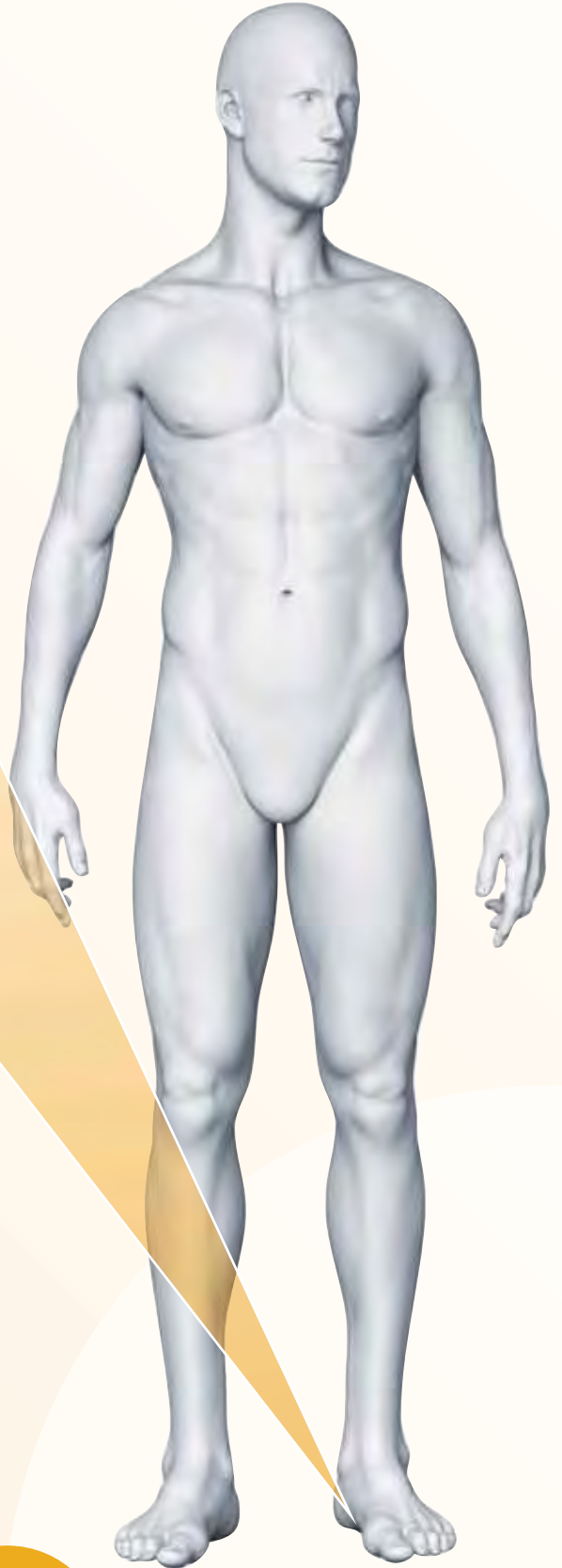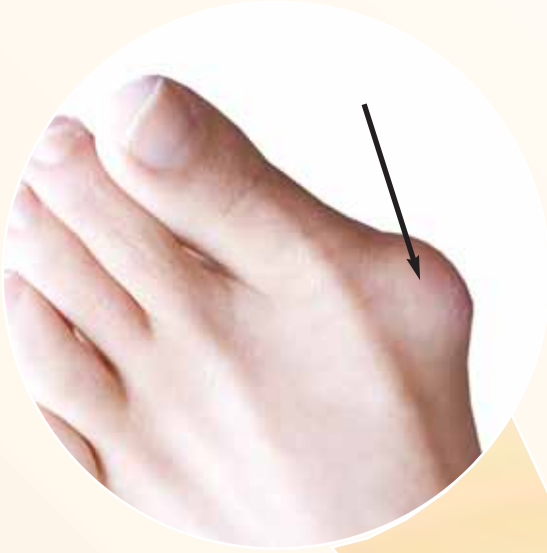Putuguq

Putuguq

Gros orteil  
(tallux)

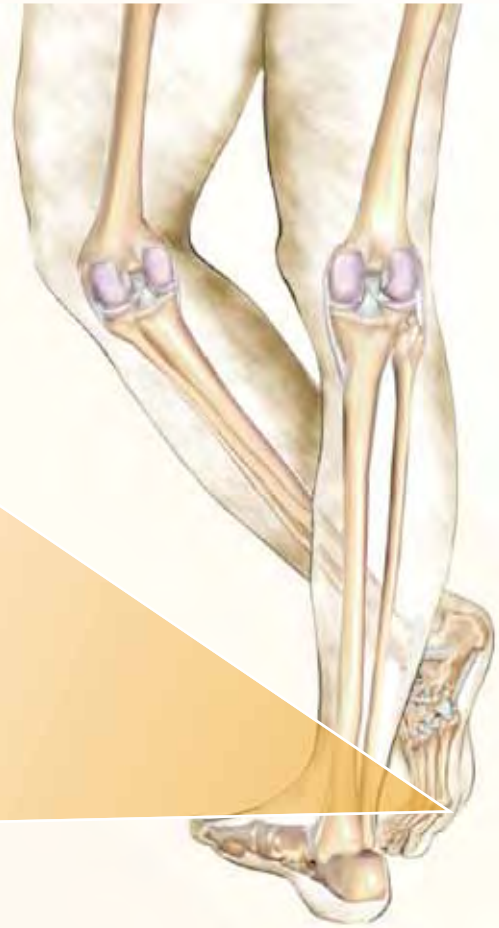
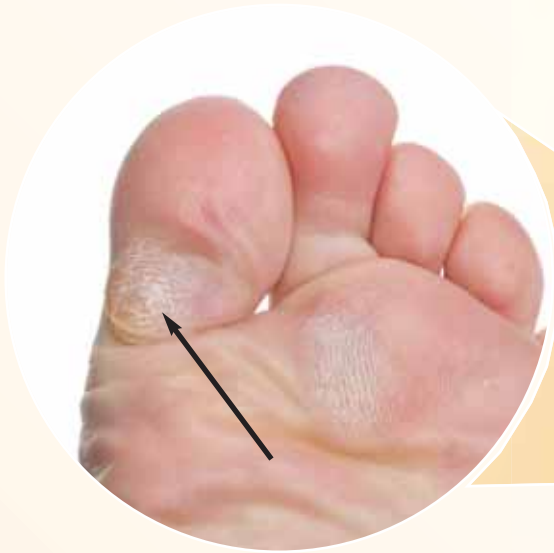
# Bunion of the Big Toe



ᐱᓐᓂᓴᕐᓴᓐ  
Pingaluk  
lhugluk/  
Haunaiyaq  
Racine du  
gros orteil

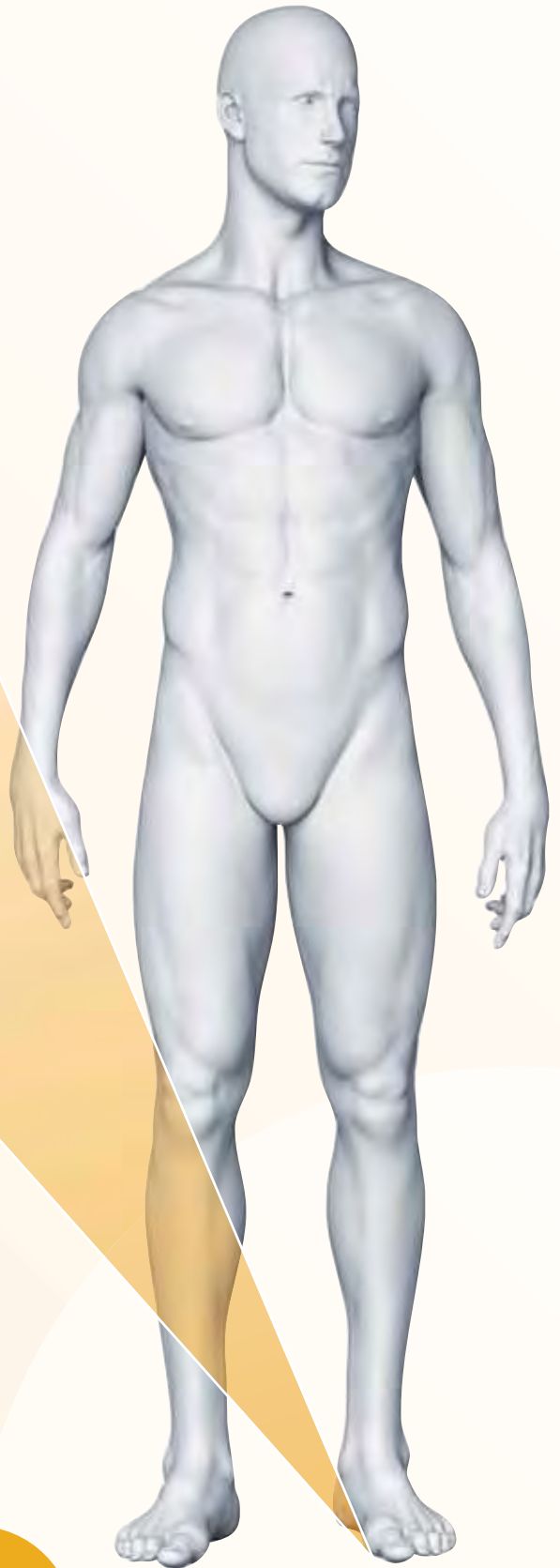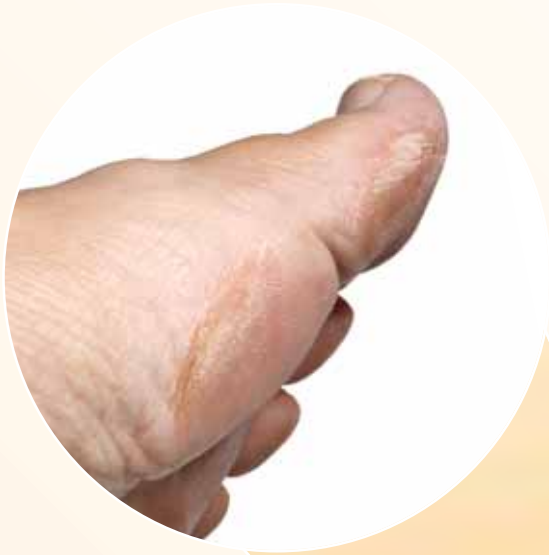# Callus, Hard Skin



ᐱᐸᐸᐸᐸᐸ ᐱᐸᐸᐸᐸᐸ ᐸᐸᐸᐸ

Aggangmilu Isigangmilu Kauk  
Alurnak  
Durillon

# Corn, Callus

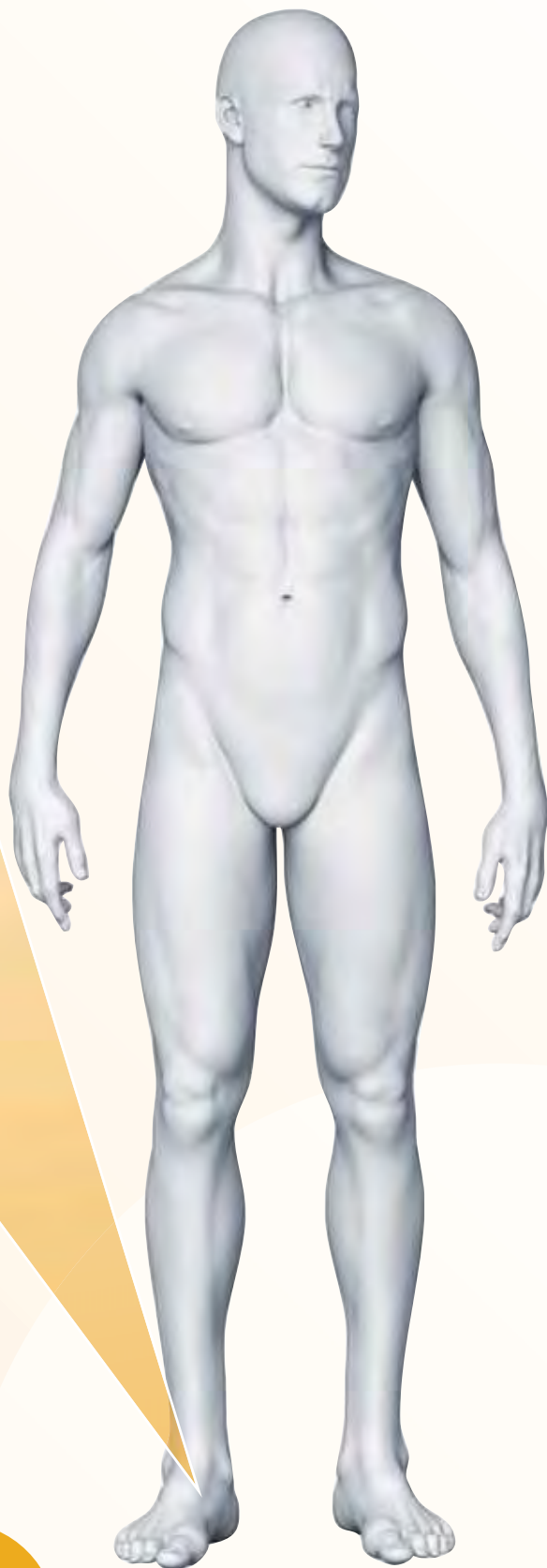
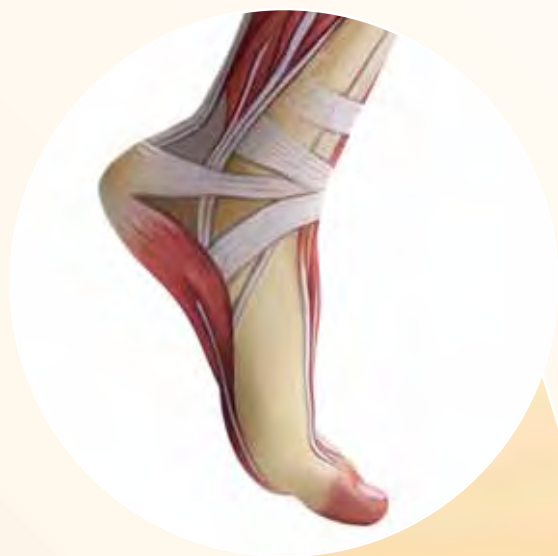
ΔΡΥΛΨΓ βΔβ

Isigangmi  
Kauk

Ammiktuq  
Cor durillon

# Dorsum of the Foot



Aluup

Tunnganinga

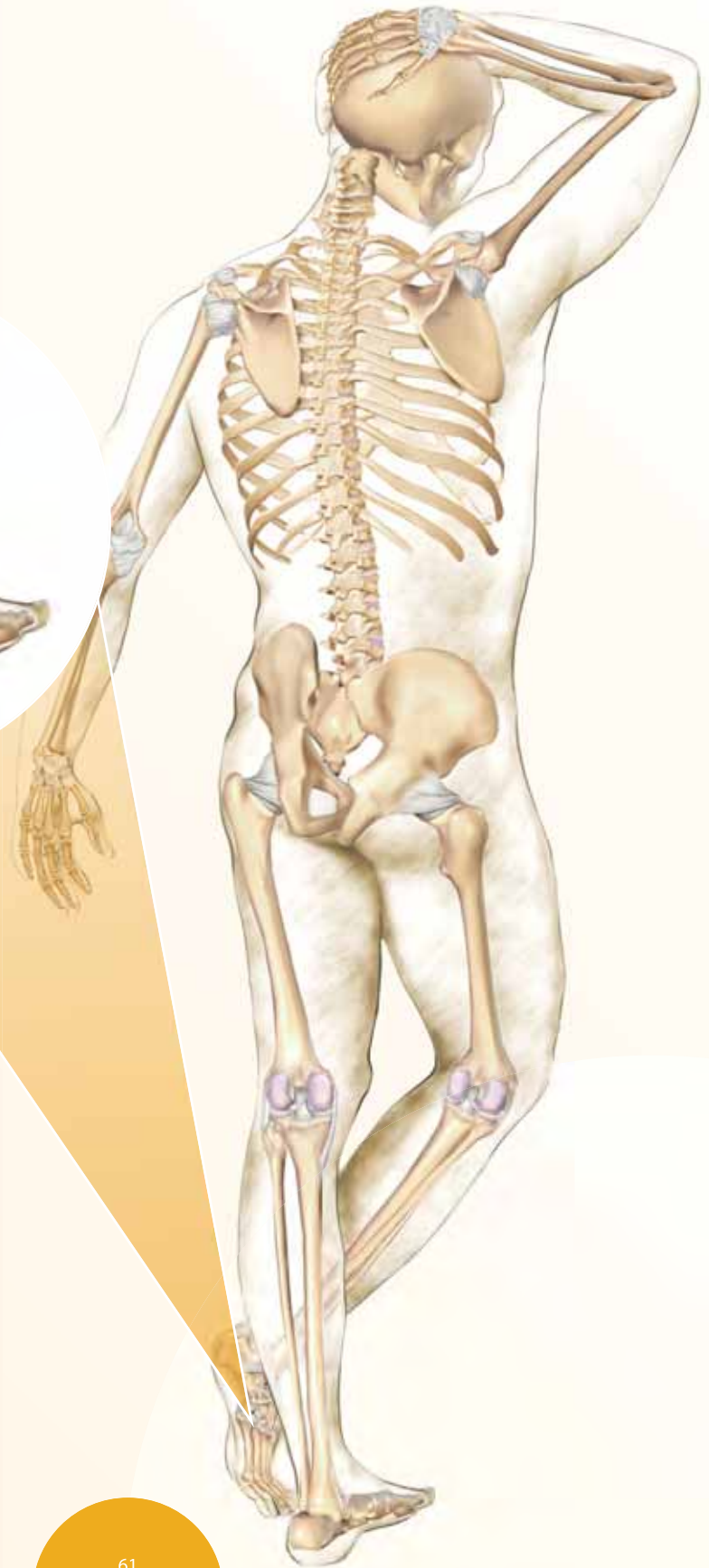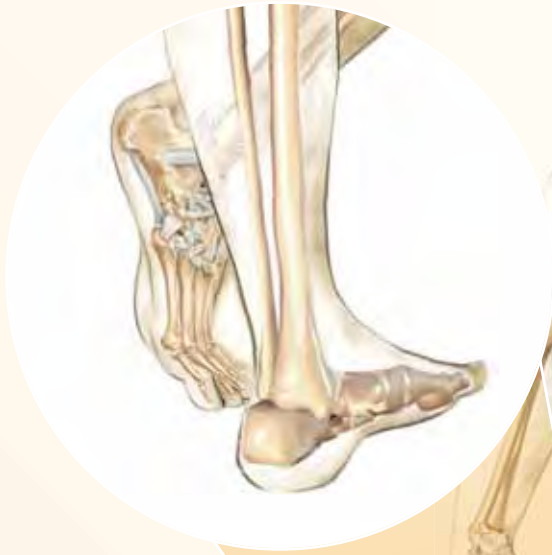Aluq

Partie externe

du pied



# Feet



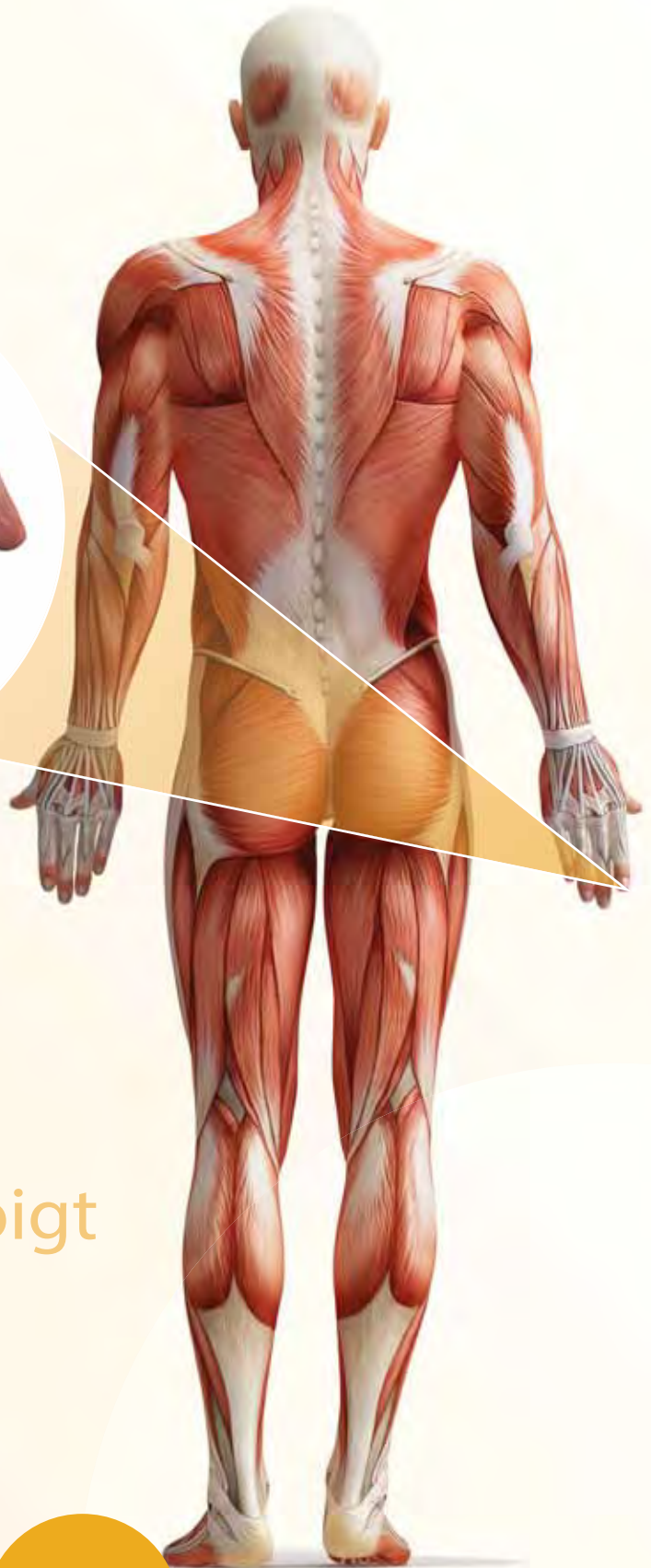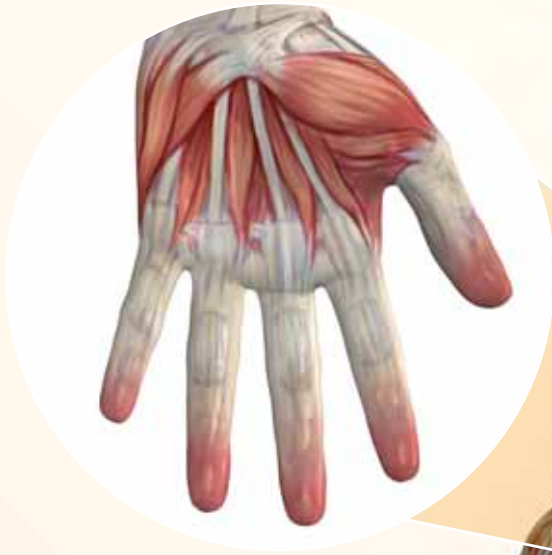ΔΡΥΔΕ

Isigait

Itikkak

Pieds

# Finger Tips



LDQΔ<sup>c</sup>

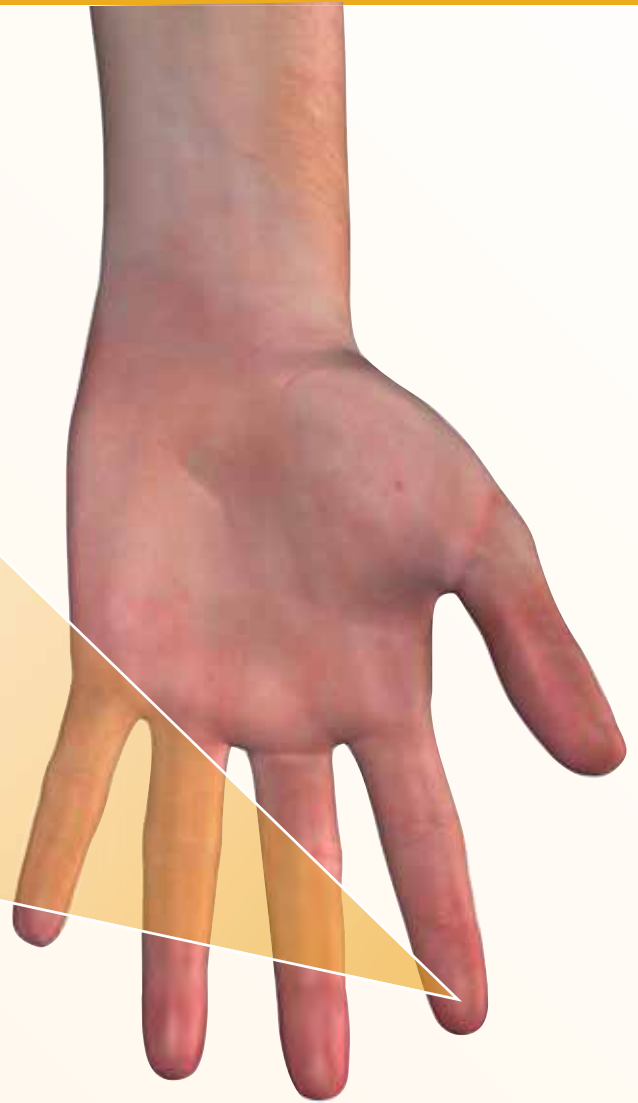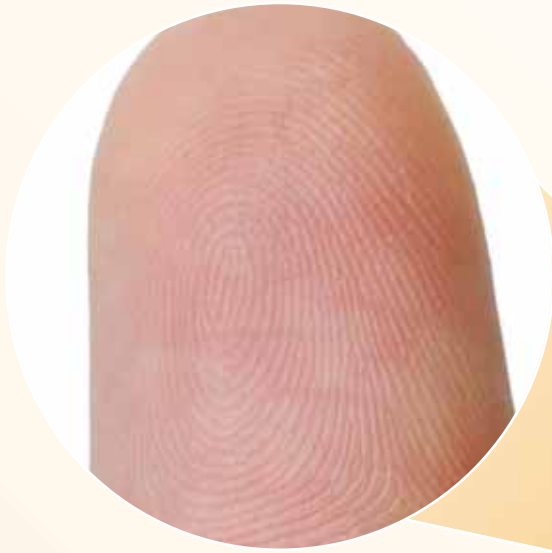Maunait

Maunat

Bout du doigt



# Fingerprint



σ▷L<sup>b</sup>

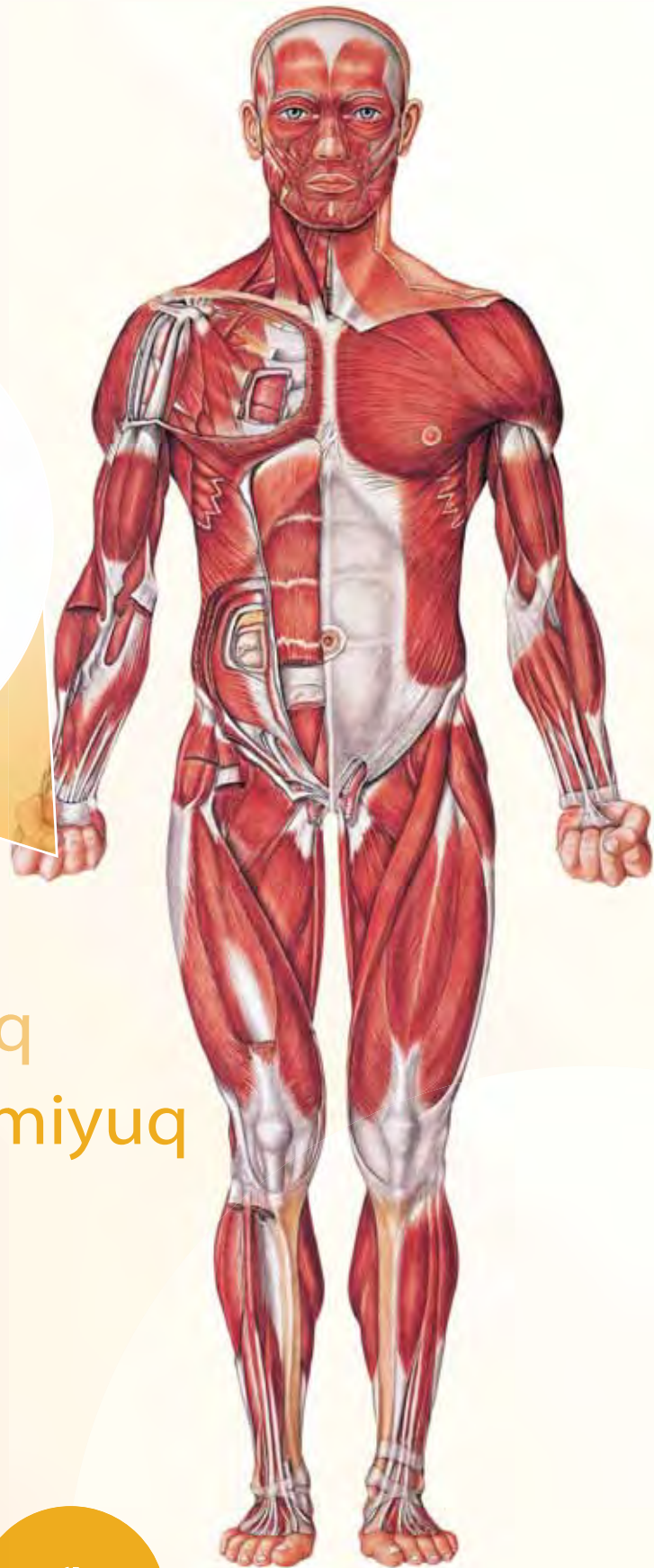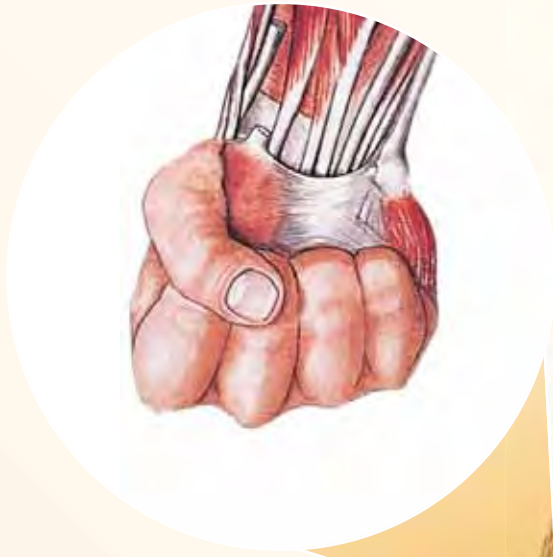
Niumak

Algaup Ipait

Empreinte  
digitale



# Fist



ᠨᠵᠯᠦᠷᠠᠭᠦᠨ

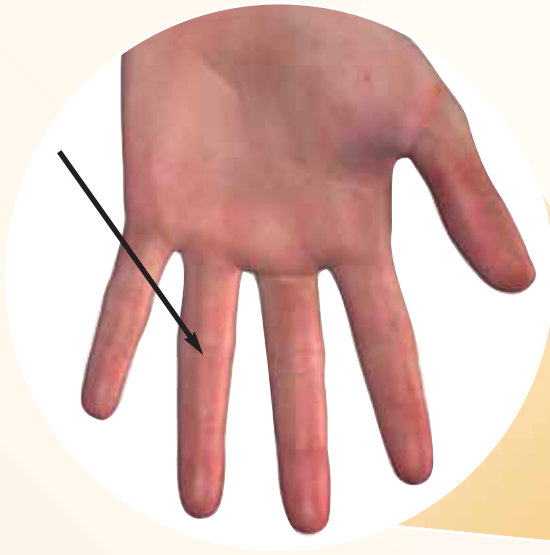Tigummijuq

Algak Iqimmiyuq

Poing



# Fourth Finger



ΓΡϸϻϷ

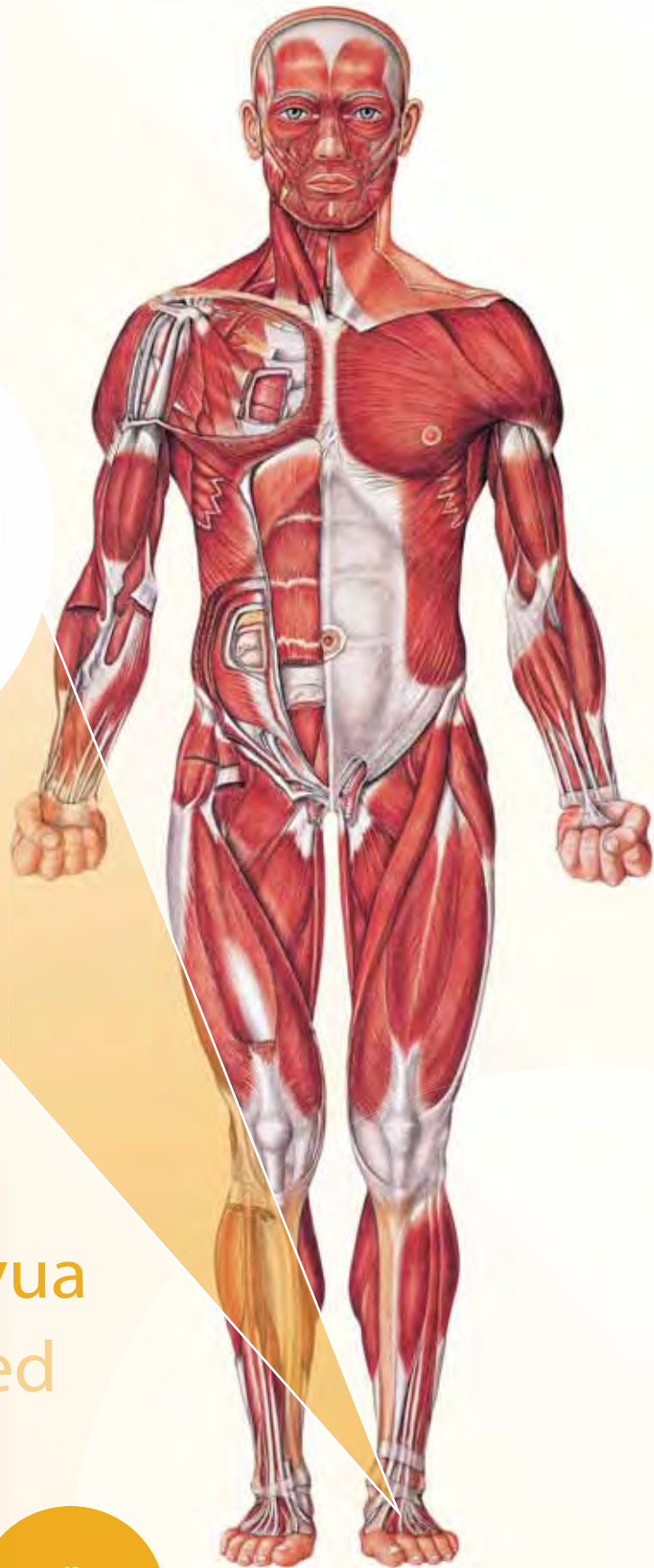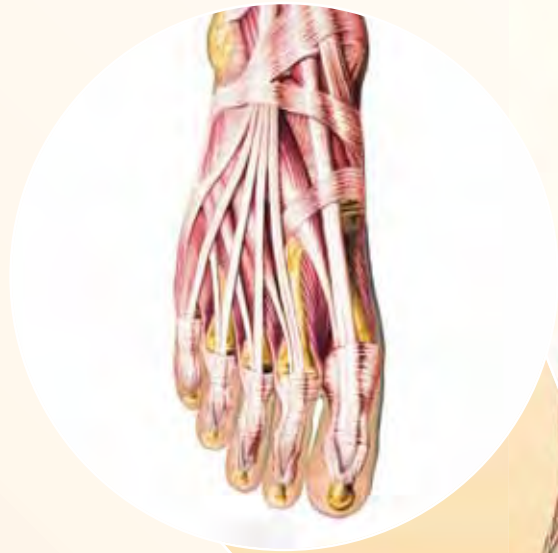Mikiliraq

Mikiliraq

Annulaire



# Front of the Foot

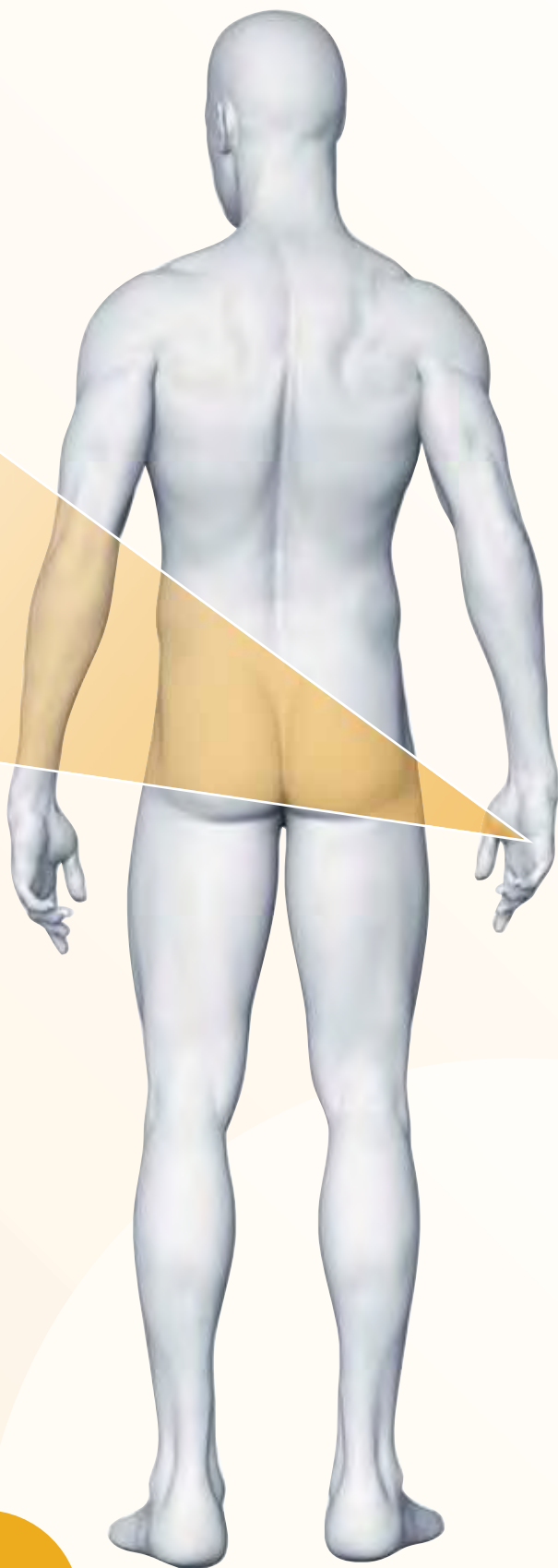

Δῖλδῖ  
ῖḅḅḅḅḅḅ

Isigaup  
Qallininga  
Itikkap Nuvua  
Bout du pied



# Hand Edge



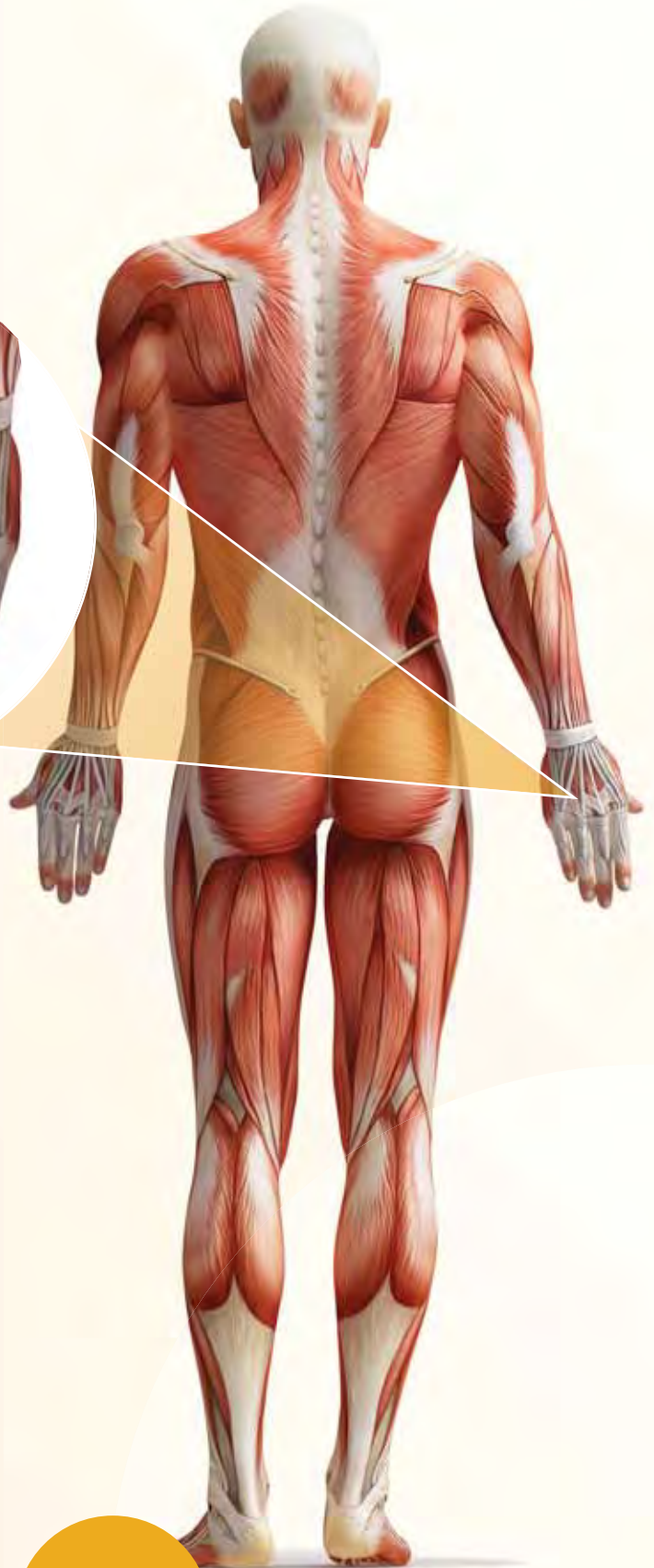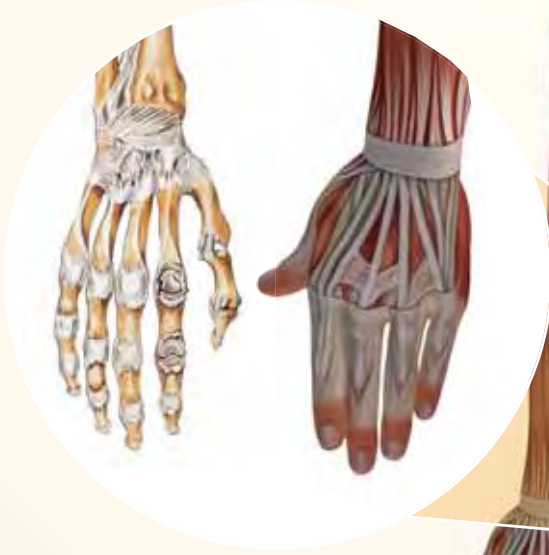ᐱᕐᕐᕐᕐᕐ  
ᐱᕐᕐᕐᕐᕐ

Aggaup  
Arvanga

Arvaq

Tranchant  
de la main

# Hands



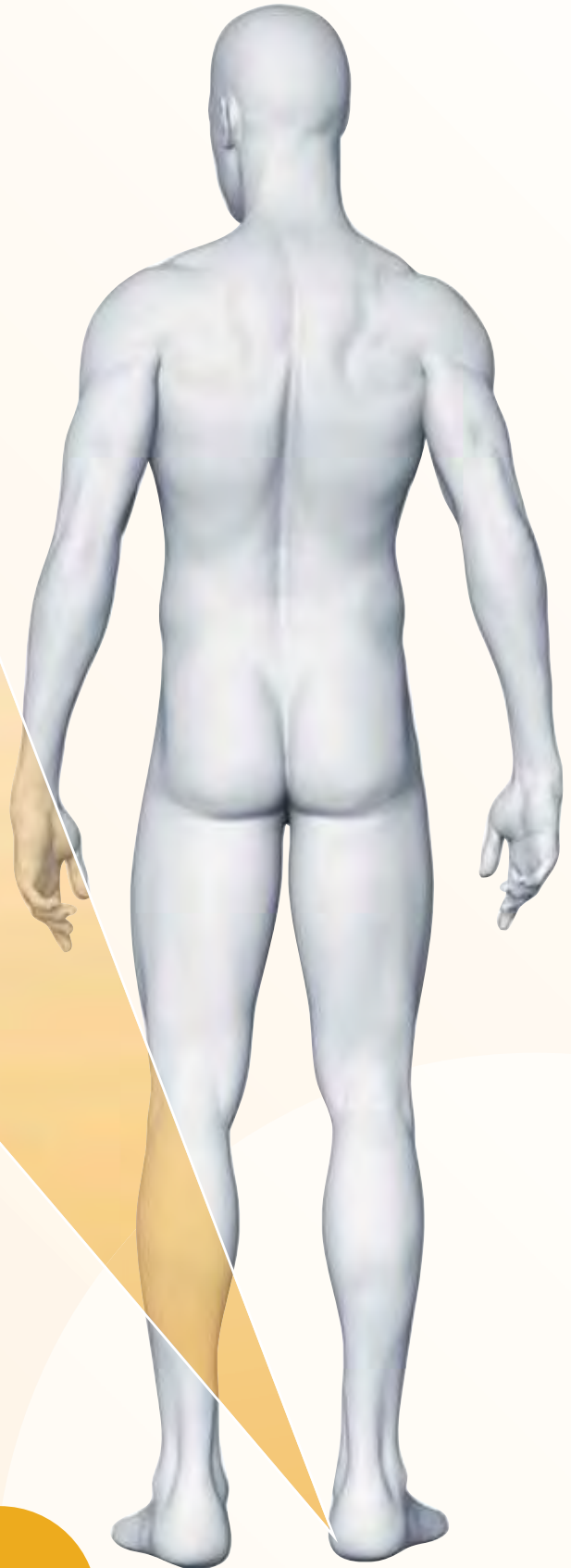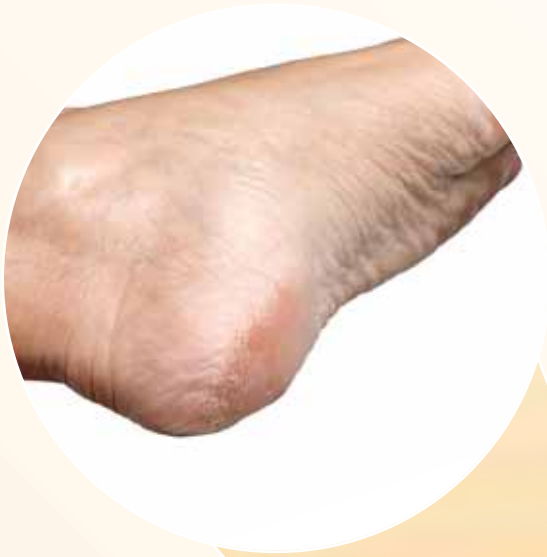◀◡◡Δ◡

Aggait

Algak

Mains

# Heel/ Back



ᐃᓄᓂ

Kingmik

Kingmitquq

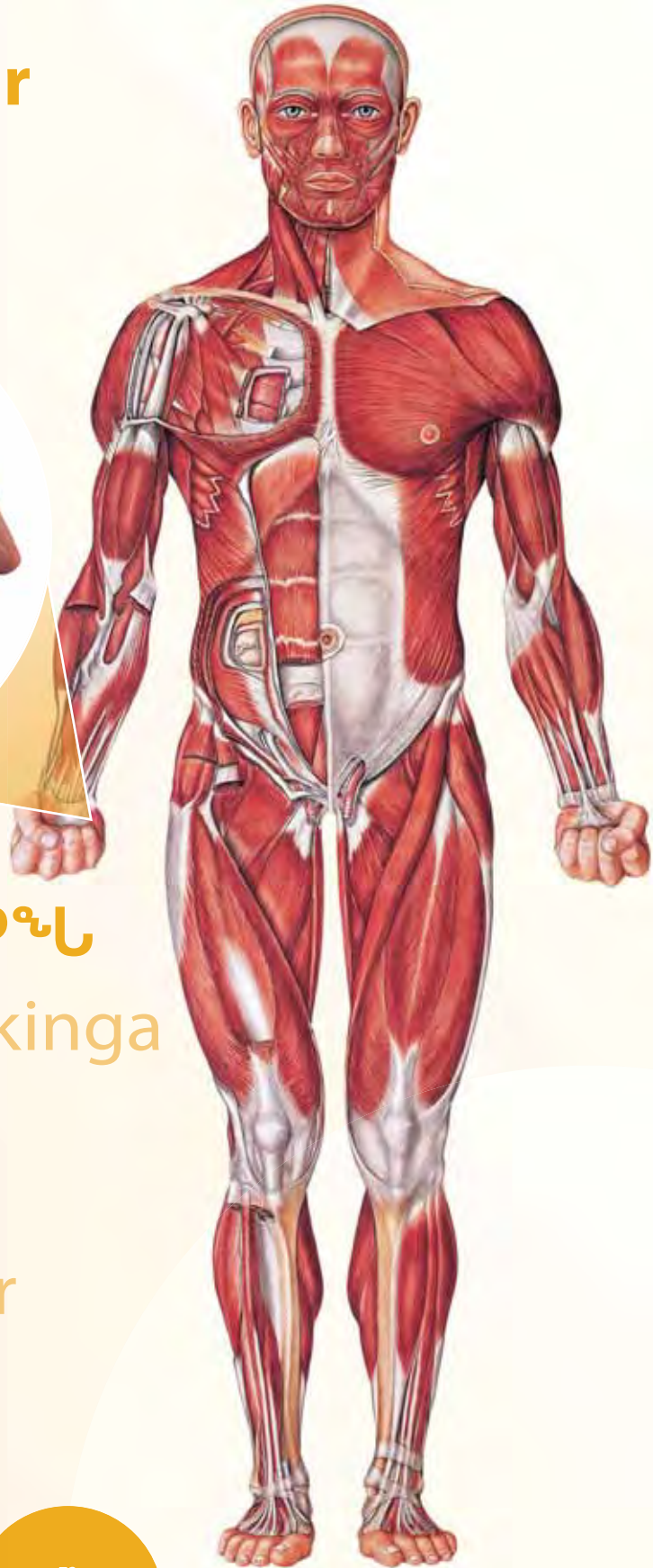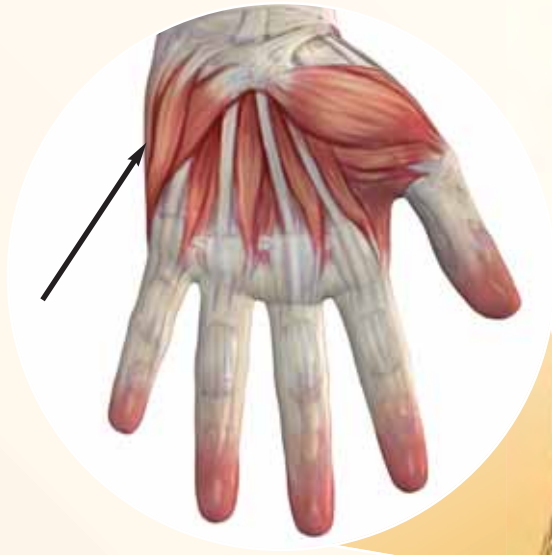Talon

(postérieur)





# Hypothenar



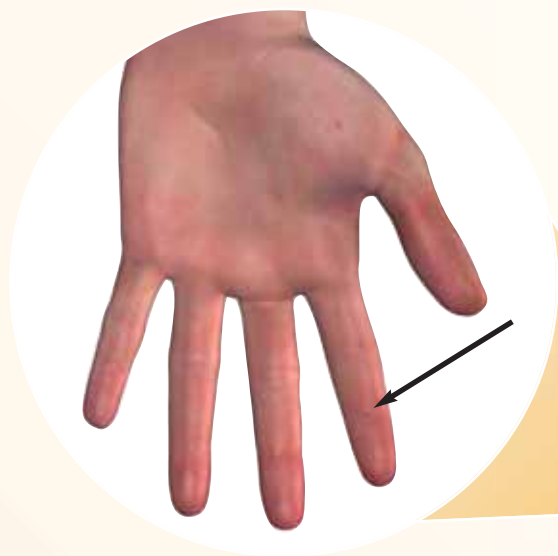ՀԳԸԾԿ ԾՐՆԼ

Arvaup Nukinga

Arvaq

Éminence  
hypothenar

# Index Finger



ИРҶБ

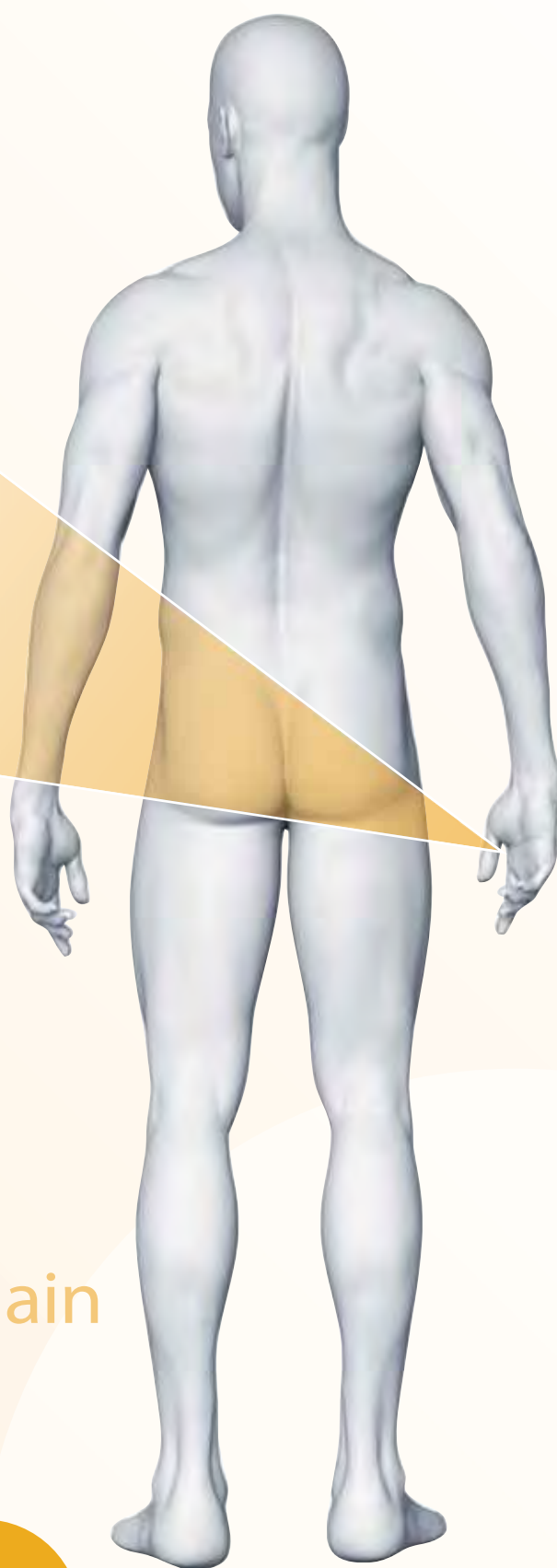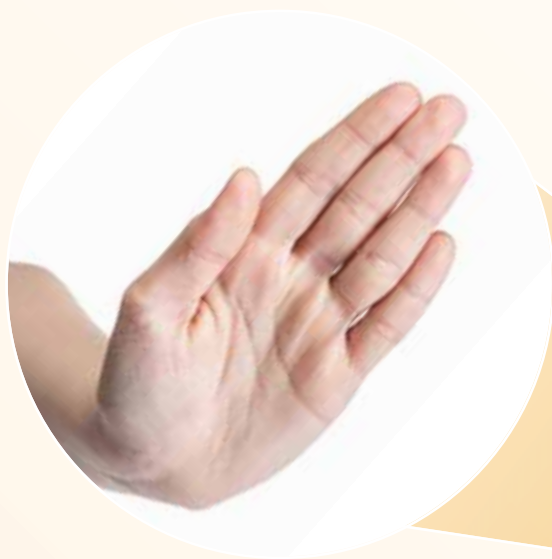Tikiq

Tikiq

Deuxième  
pouce



# Lines of the Hand



ᐱᐅᐅᐅᐅᐅᐅ

Savuujaq

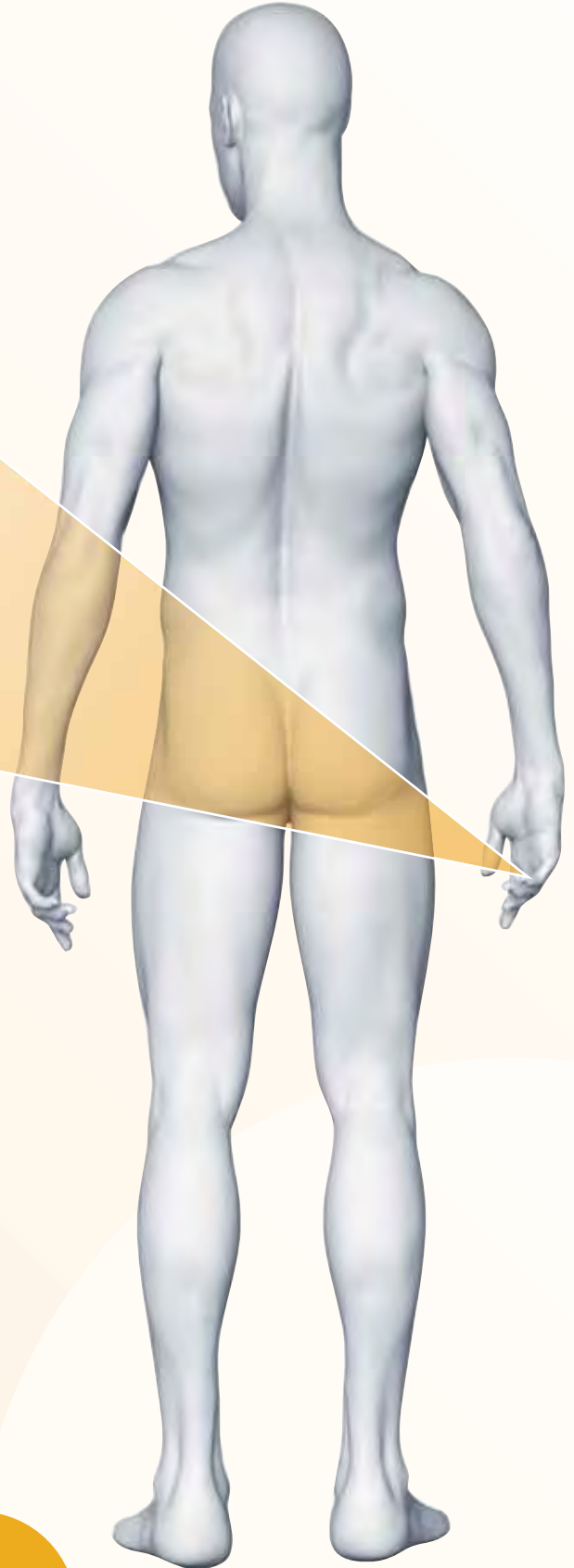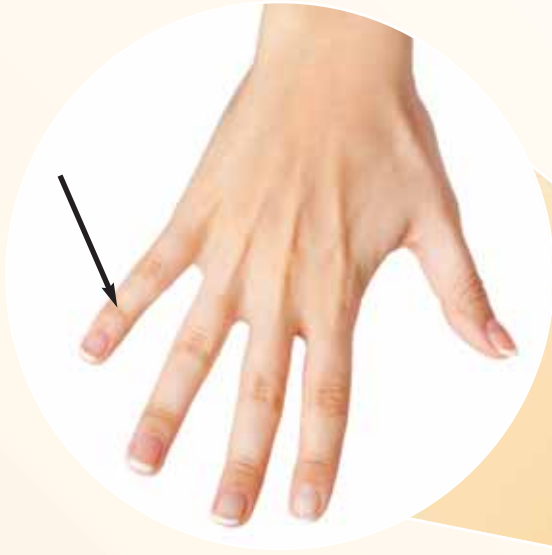Itimaup

Iqinganiit

Lignes de la main



# Little Finger



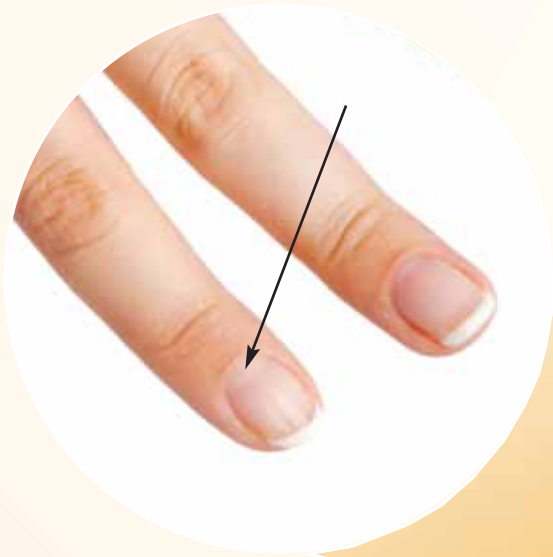Δ ς ρ ς β ρ ς β

lqiqquq

lqitquq

Auriculaire

# Lunule / Half-Moon of Finger Nail



ᑳᑭᑭᑭᑭ

ᑭᑭᑭᑭᑭᑭᑭᑭ

Kukiup

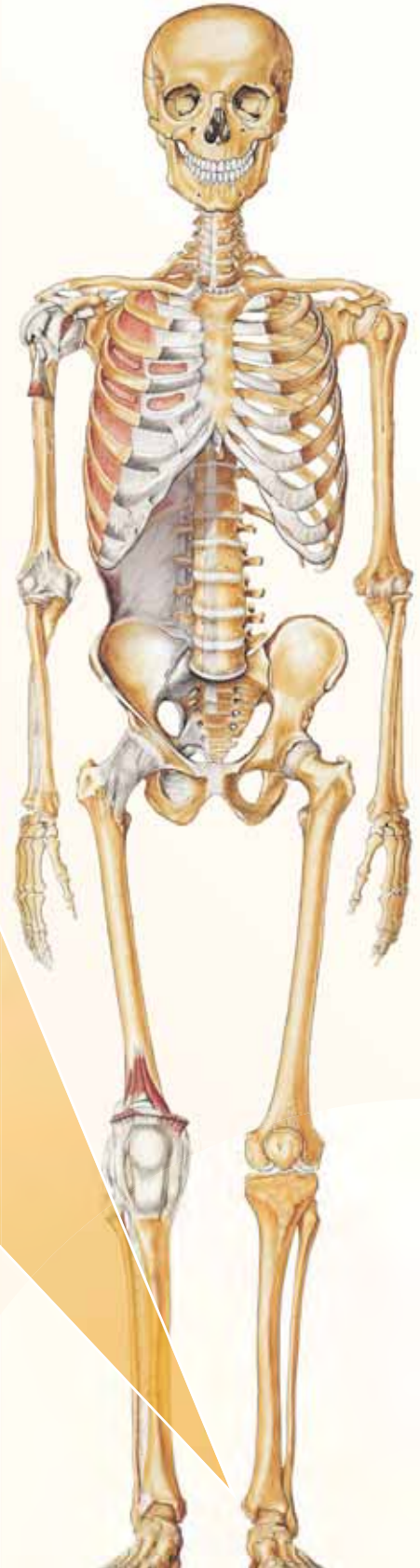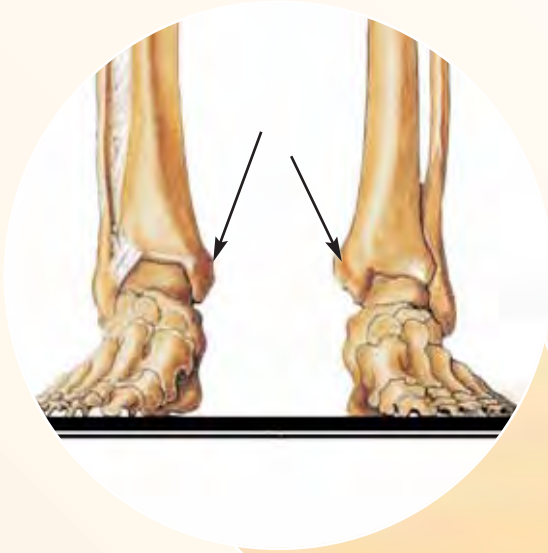
Qaullurninga

Kukiup

Qangatania

Lunule

# Malleous



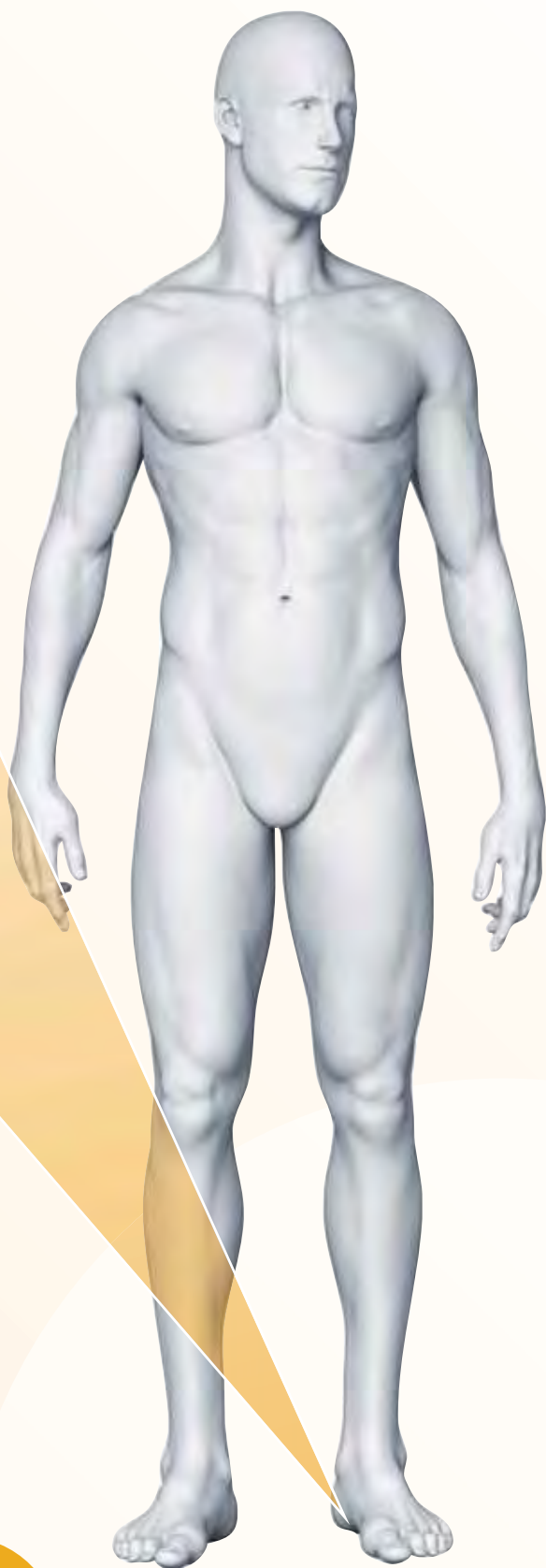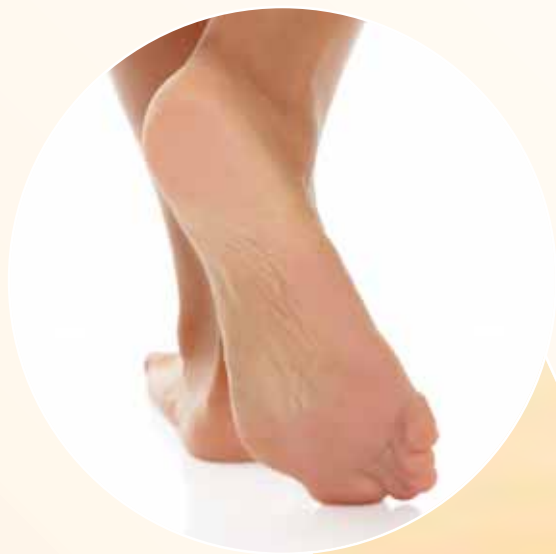ᠠᠨᠨᠭᠠᠴ

Qanngaq

Hingirniq

Cheville

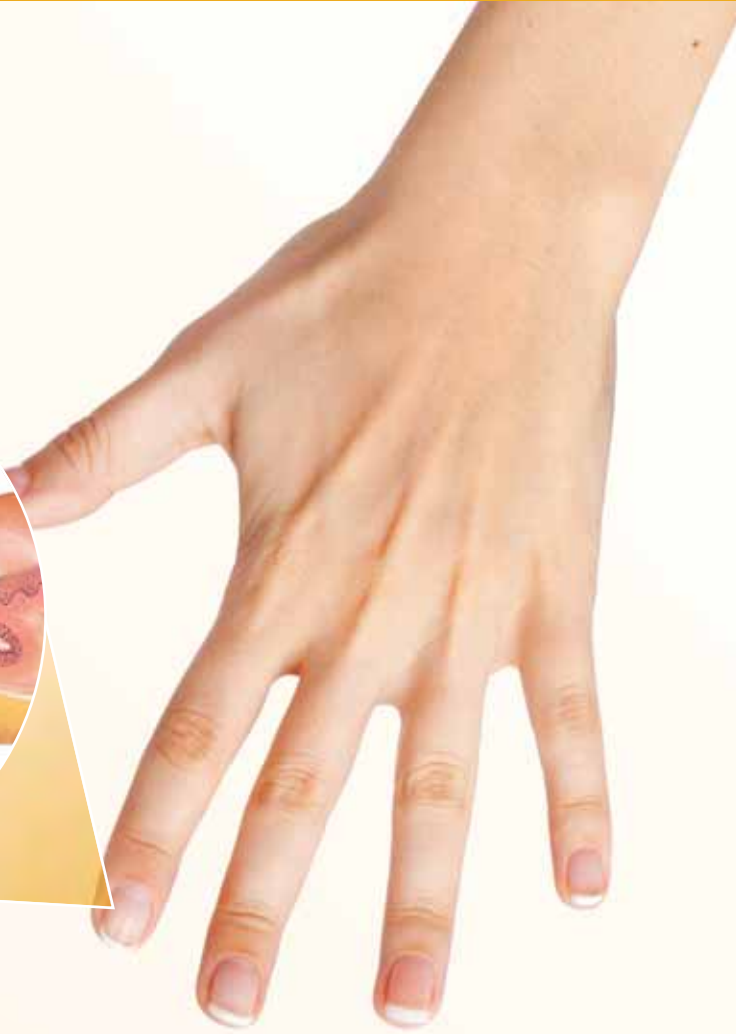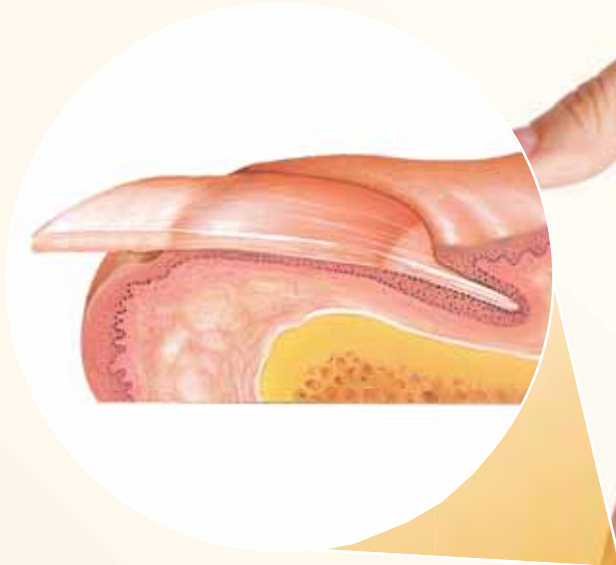
# Middle of the Sole of the Foot



σηΛσ<sup>9b</sup>  
Nirimaniq  
Allup Qitqa  
Milieu de la  
plante du pied



# Nail



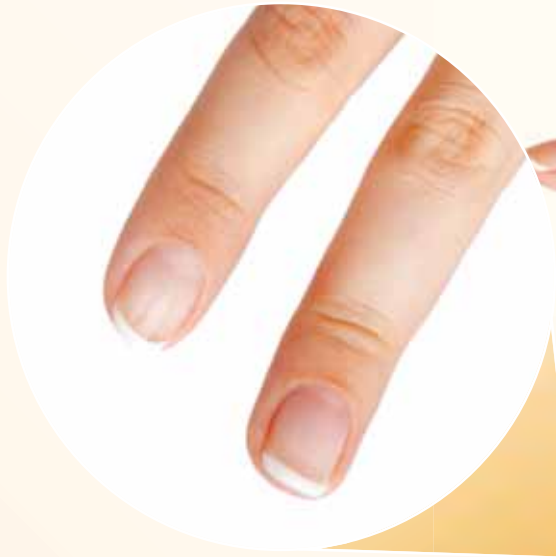дрб

Kukik

Kukik

Ongle

# Nail Tip



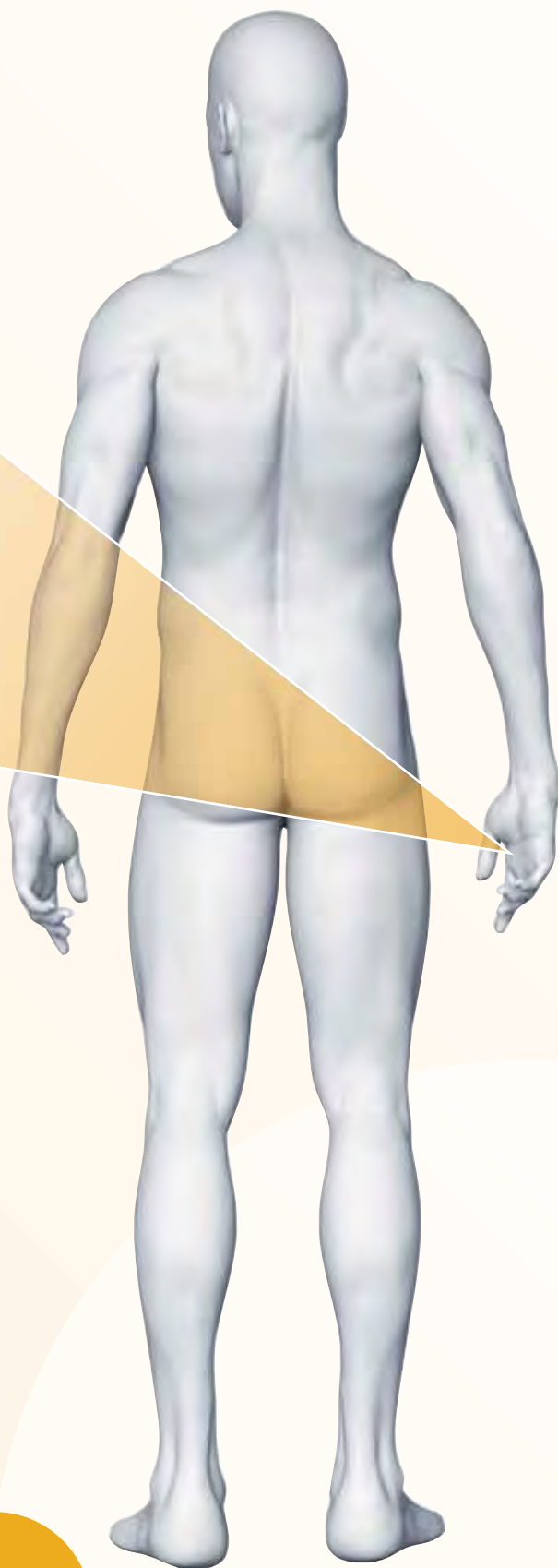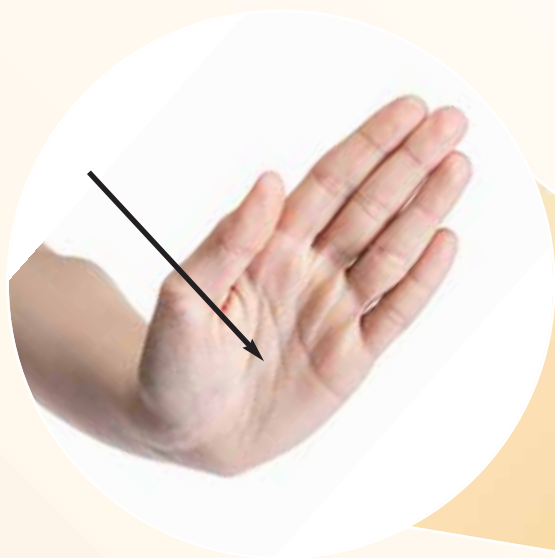ᑲᑭᑭᑭᑭ ᑭᑭᑭ

Kukiup Sinaa

Kukiup Nuvua

Bout de l'ongle

# Palm of the Hand



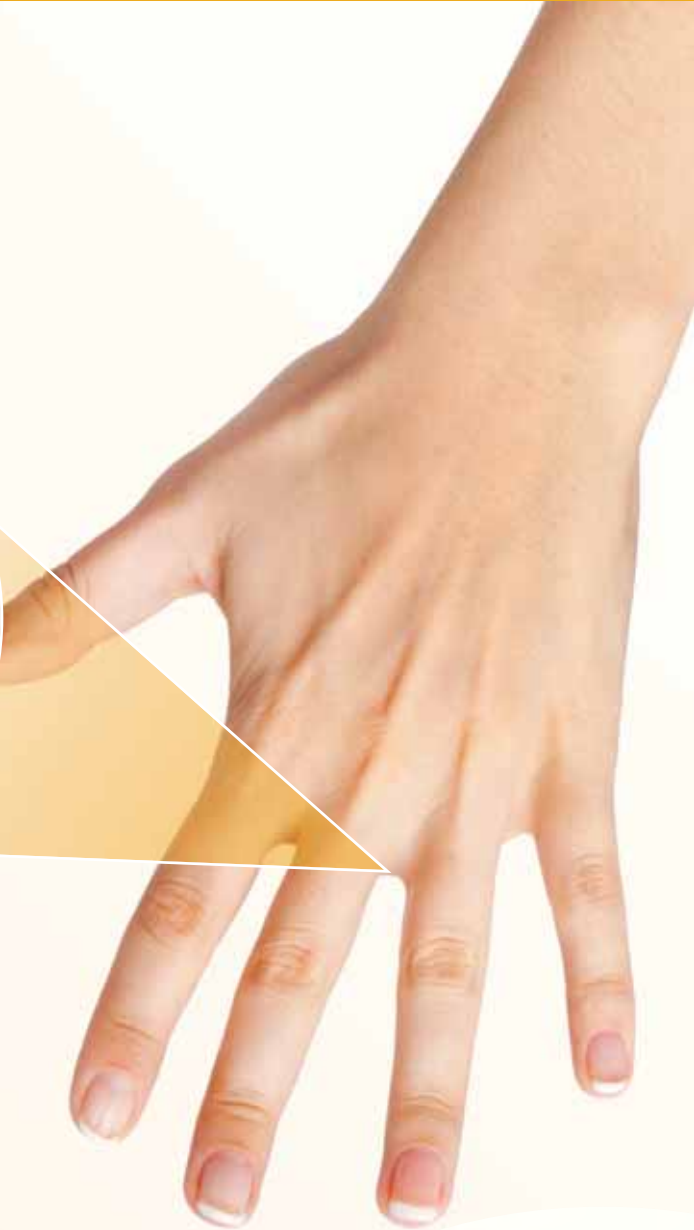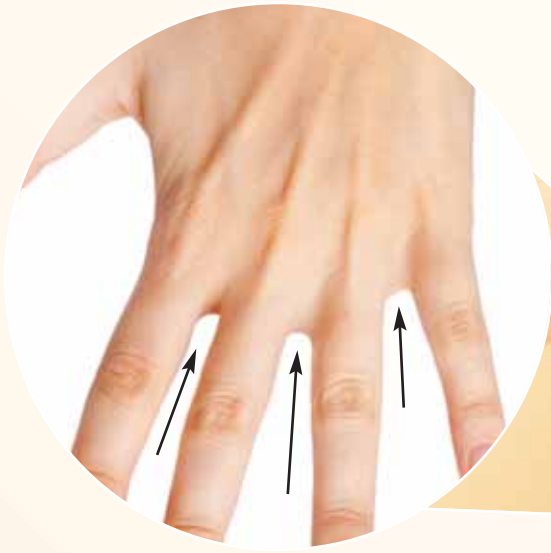ΔΟΛ<sup>6</sup>

Itimak

Itimak

Paume de  
la main

# Part Between Fingers



ᑦᑯᑦᑲᑦᑲᑦᑲᑦ

Qunnaujaat

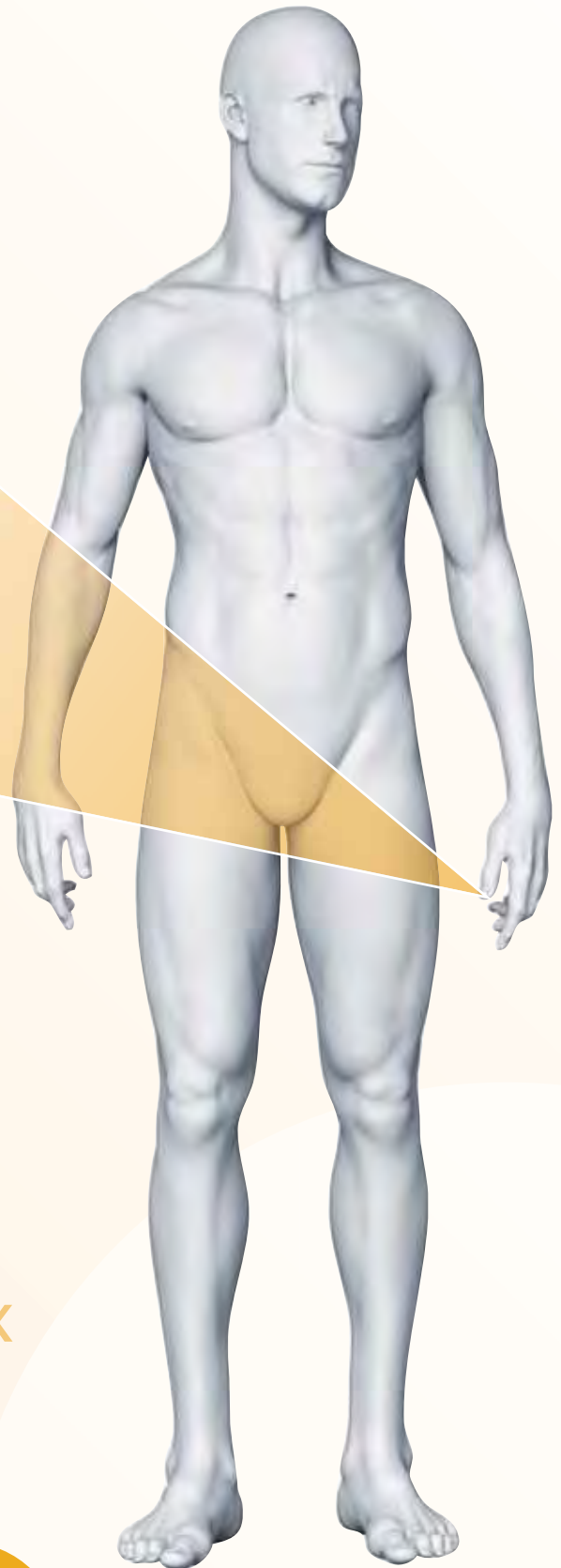

Algaup

Quppauyaangit

Entre-Doigts



# Pinscher

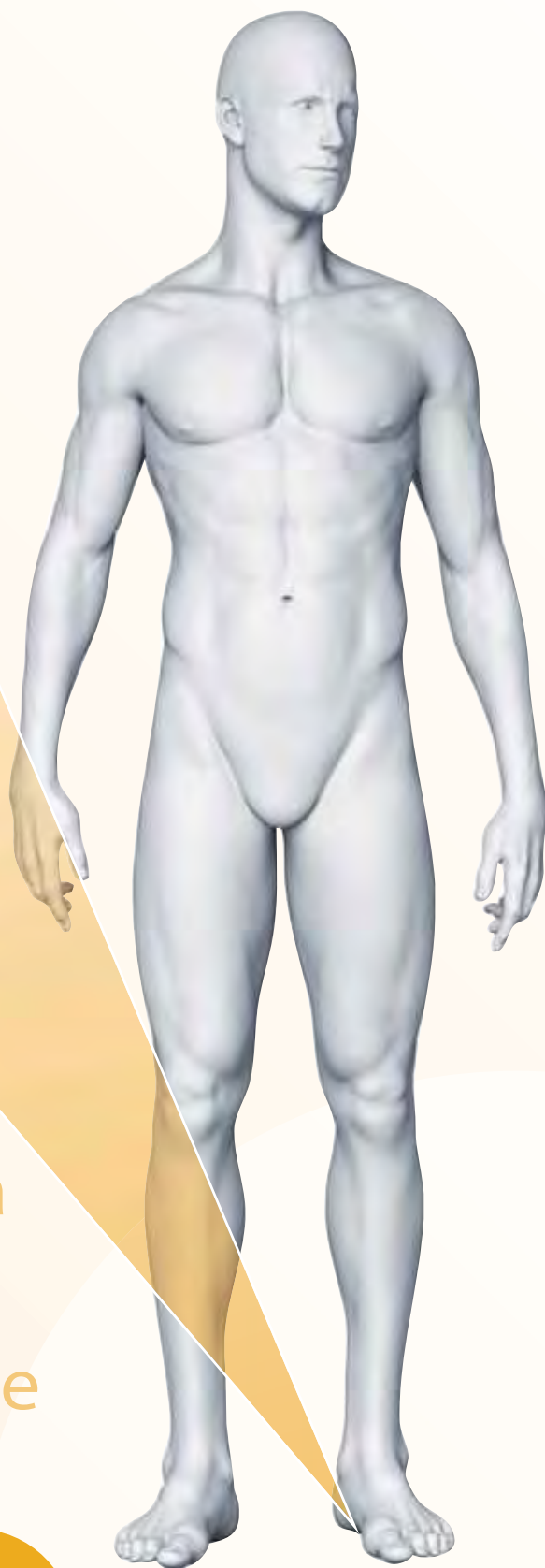
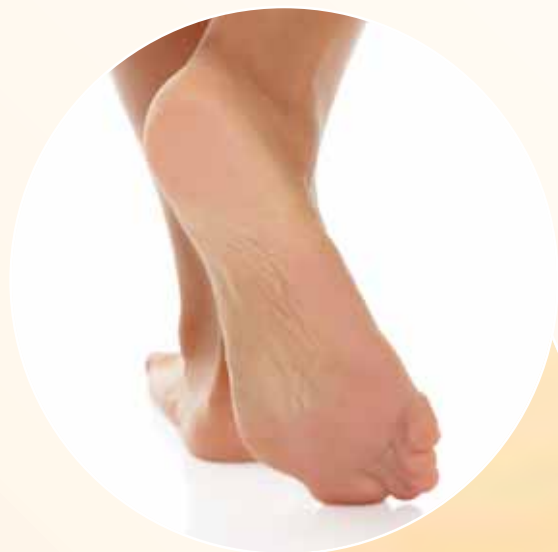
Pujjuk

Puudjuk

Bout du doigt  
pouce et index  
(pince)

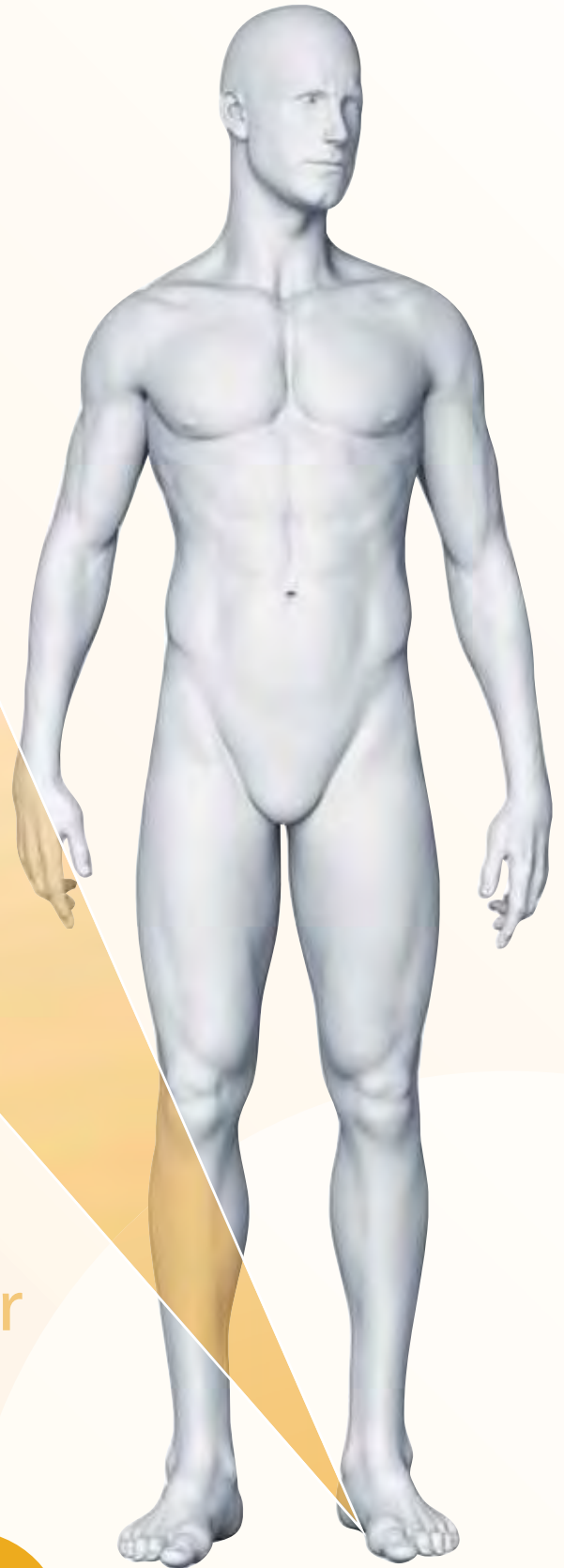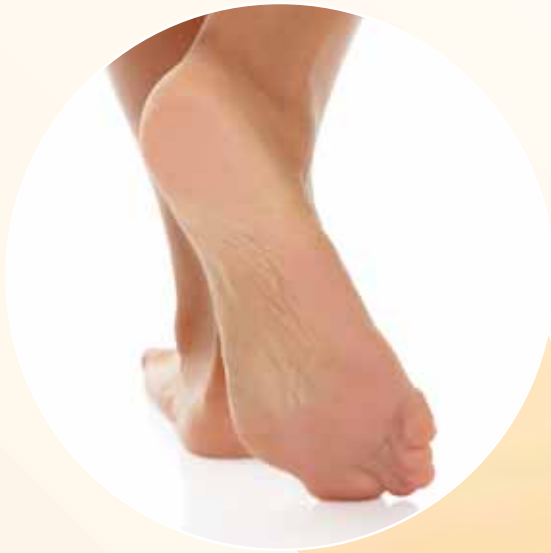# Plantar Arch / Vault



ΔΡΥΣΔ<  
ፍጅግረርፀግረ

Isigaup  
Qangataninga  
Alurnaqq  
Voûte plantaire

# Plantar Surface



ᐱᐱᐱᐱᐱᐱ

Aluq

Itigaup

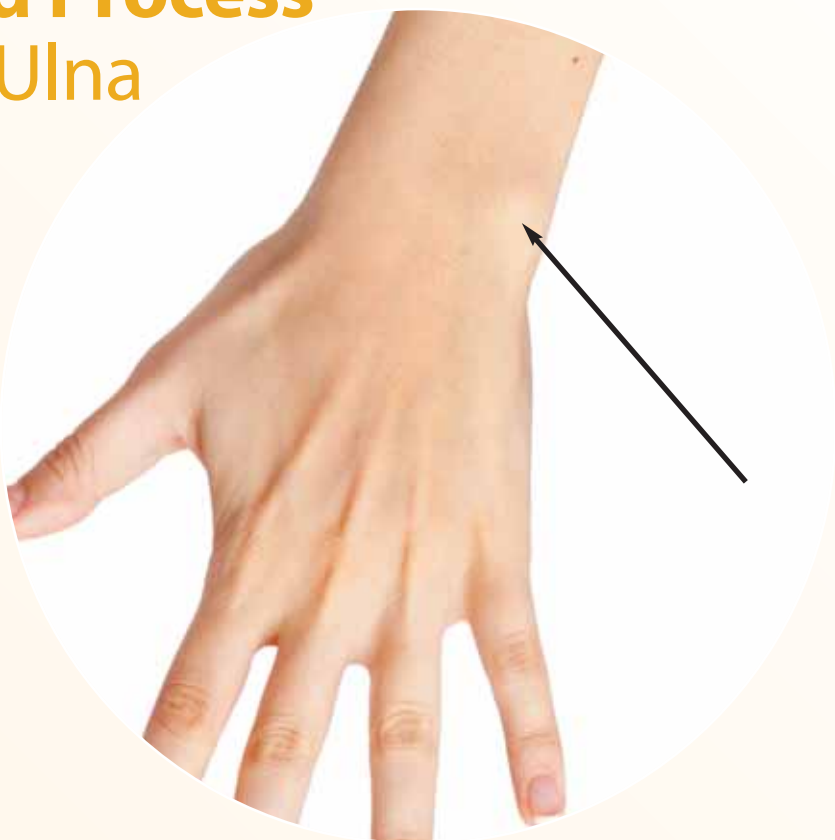Maunaa

Talon antérieur





## Styloid Process of the Ulna



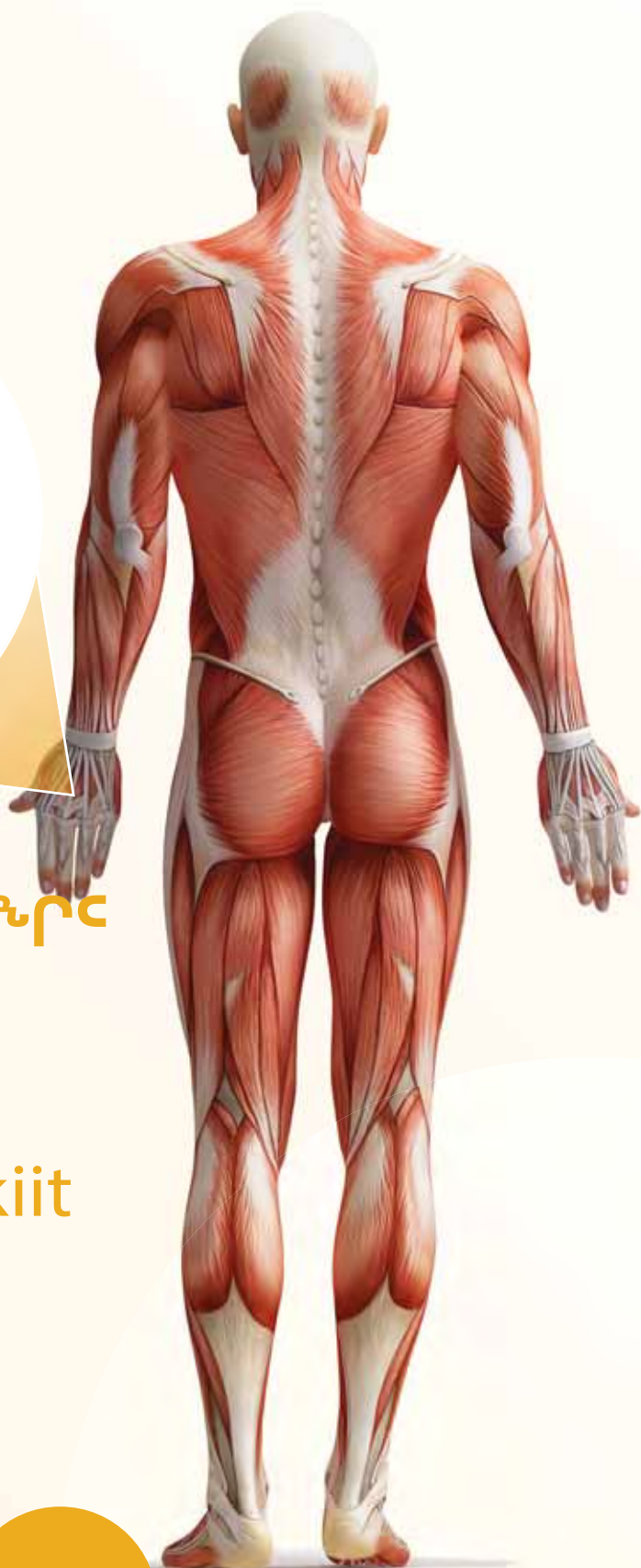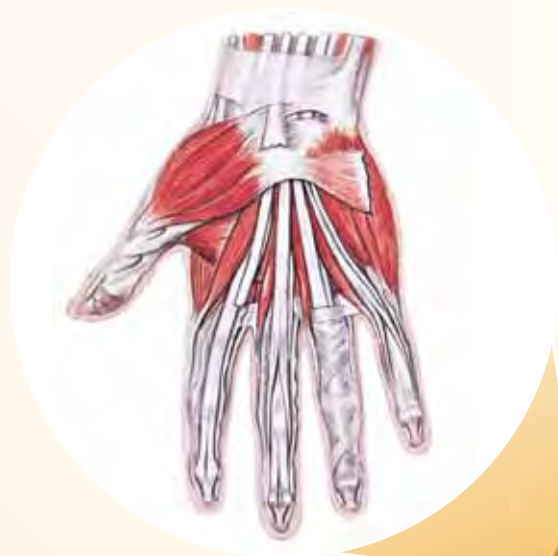ᐱᕐᕐᕐᕐᕐ  
ᕐᕐᕐᕐᕐᕐᕐ

Aggaummi  
Qattingniq

Algautip Ihuglua

Bosse du poignet  
(tête de l'ulna)

# Tendon of the Hand



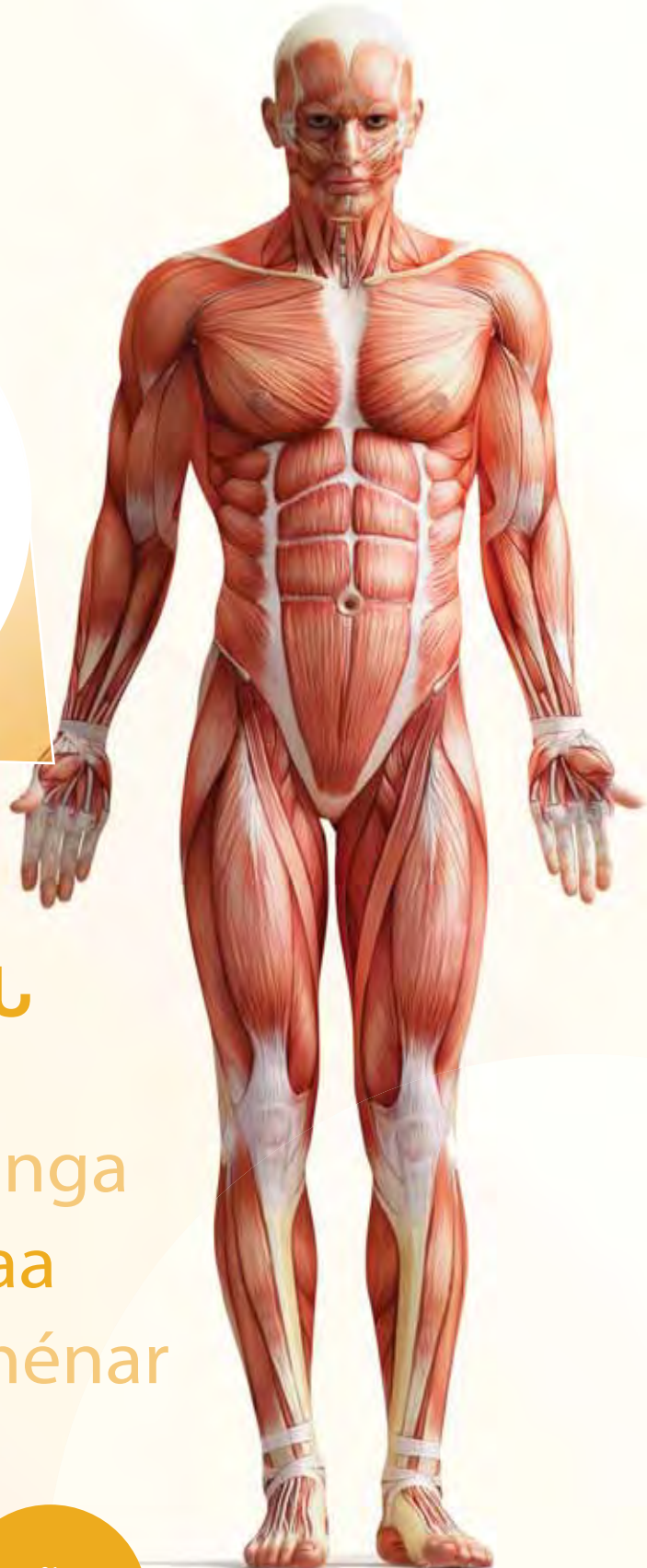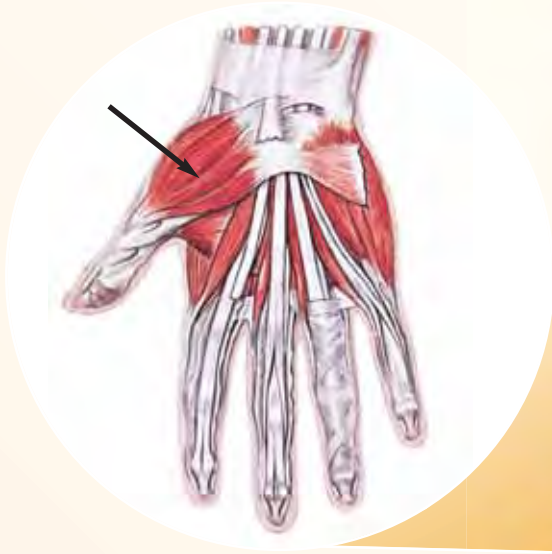ᐱᕐᕐᕐᕐᕐᕐ ᐃᕐᕐᕐᕐᕐᕐ

Aggaup  
Nukingit

Algaup Nukiit

Tendon de  
la main

# Muscle Thenar



ԺԷ ՀԿ

ԺԳԵԵՆԸՍԺՍԵ

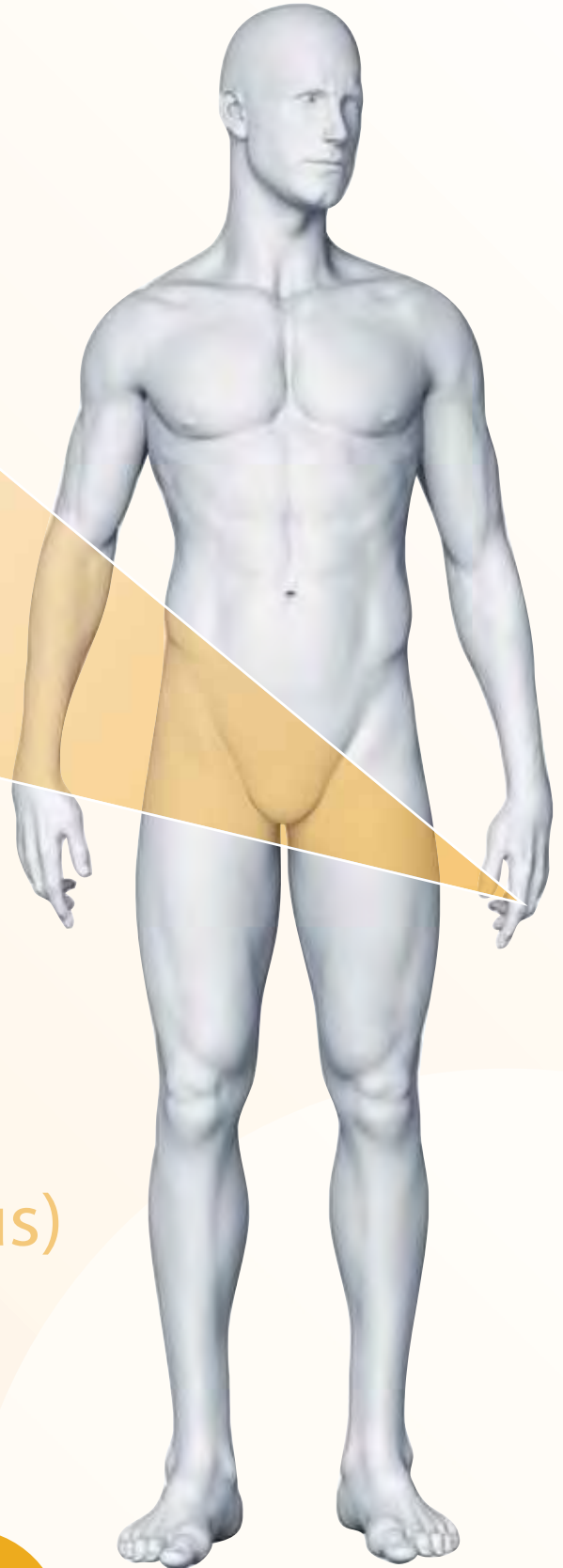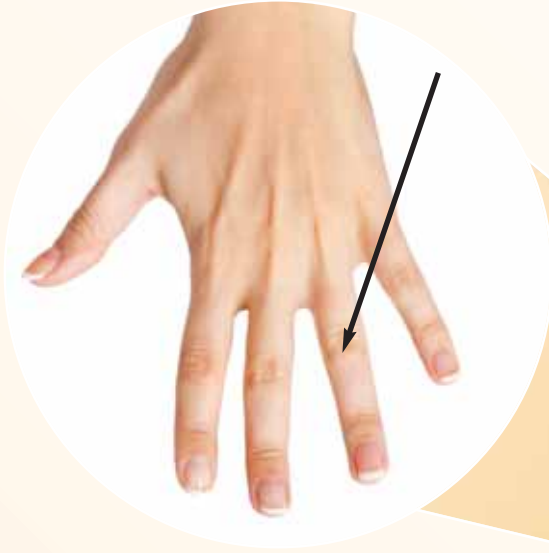Kulluup

Niqqaringninga

Kublup Niqaa

Éminence thénar

# Third Finger



ᄁᄁᄁᄁᄁᄁ

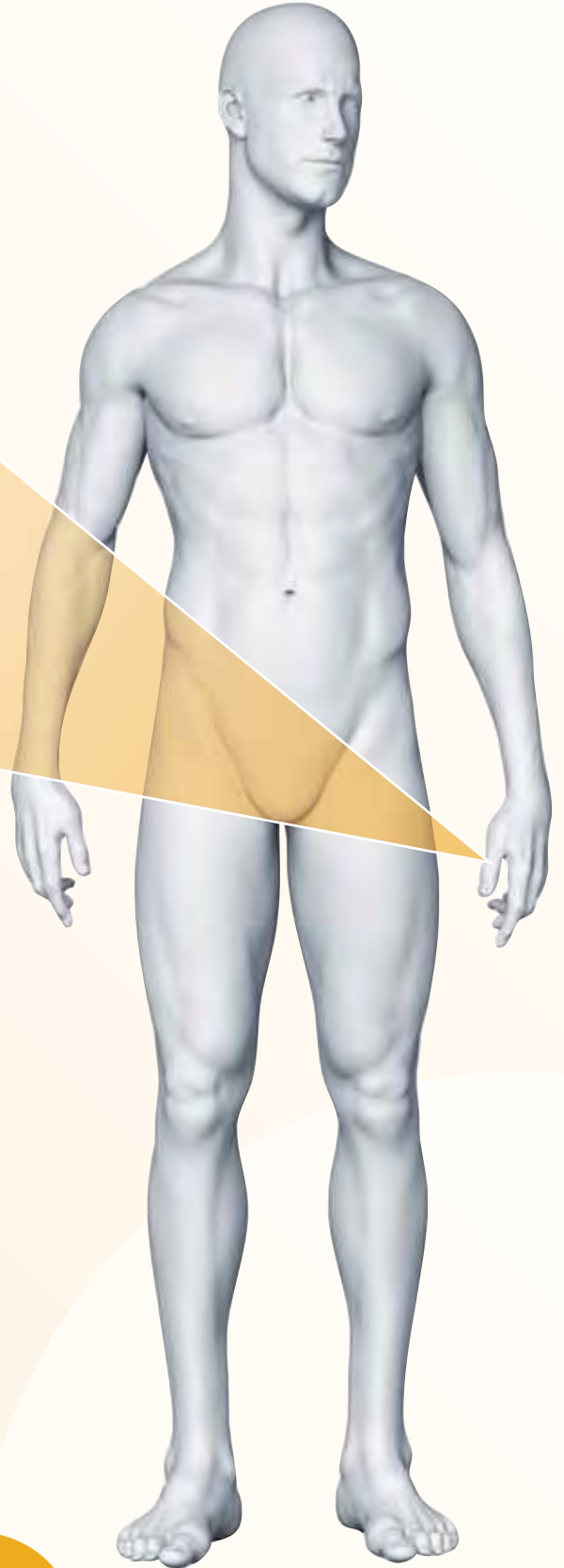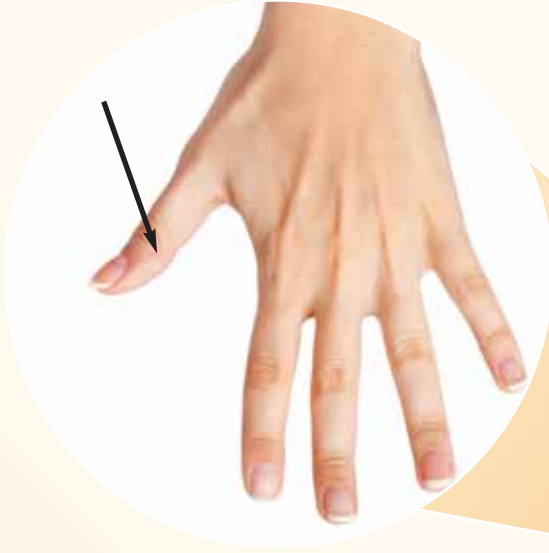Qitiqlıq

Qitiqlıq

Majeur (médius)



# Thumb



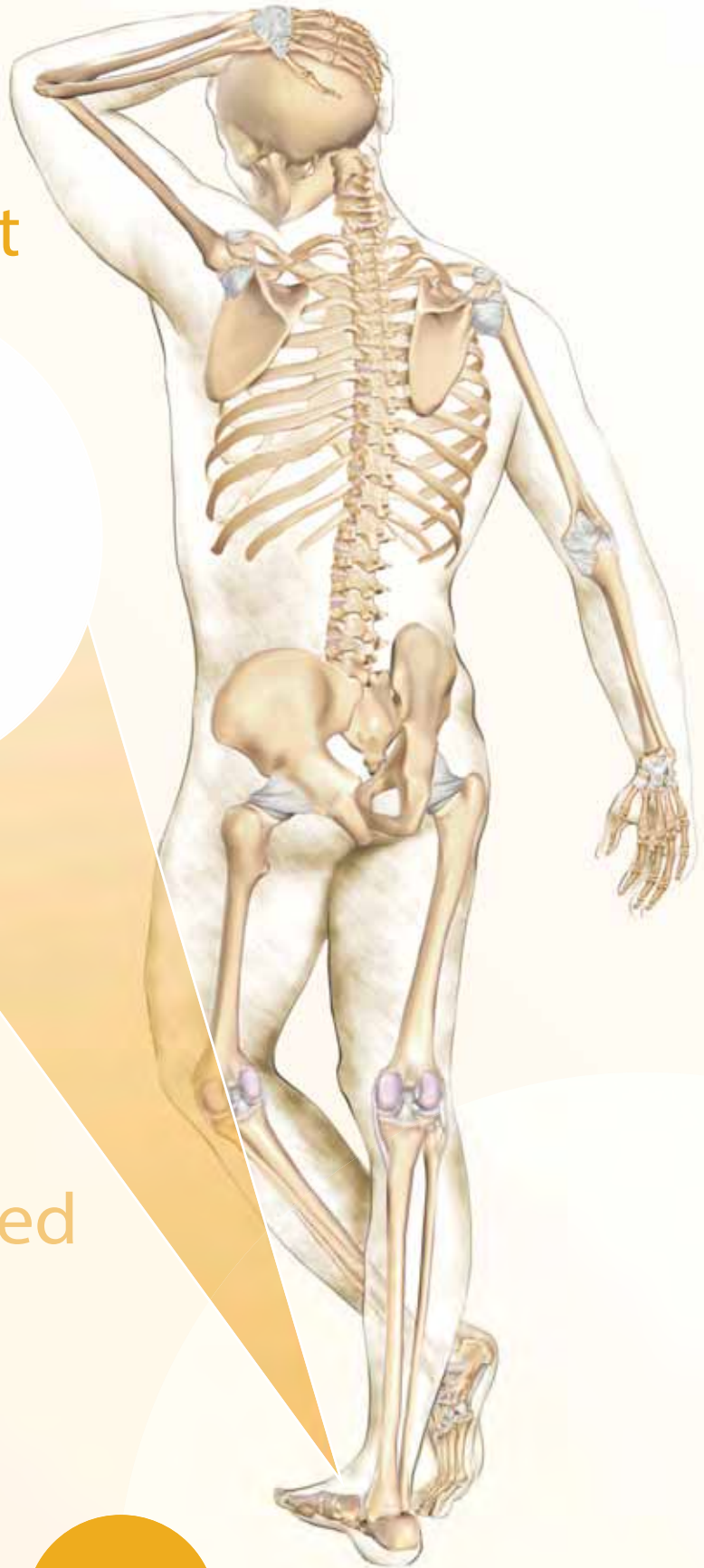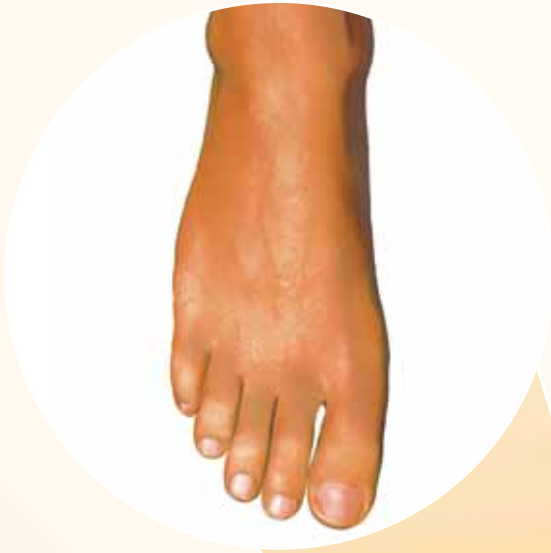كُـلـلـو

Kullu

Kublu

Pouce

# Top or Dorsum of the Foot



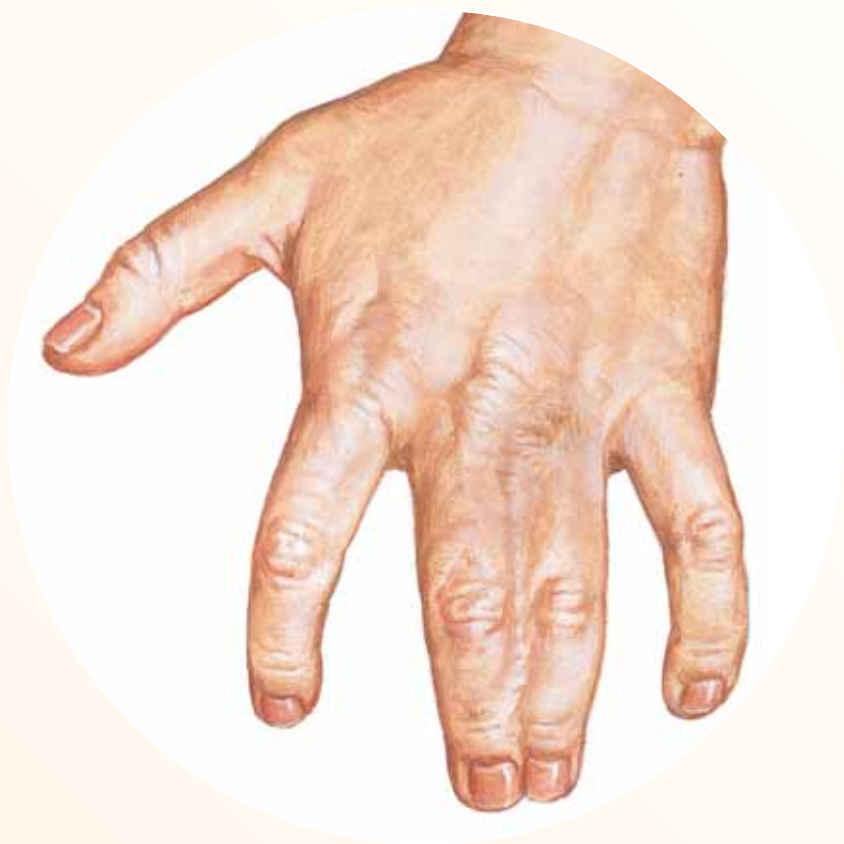ᄃᄆᄇᄈᄉᄊ

Qalliniq

Qalliniq

Dos du pied

# Web



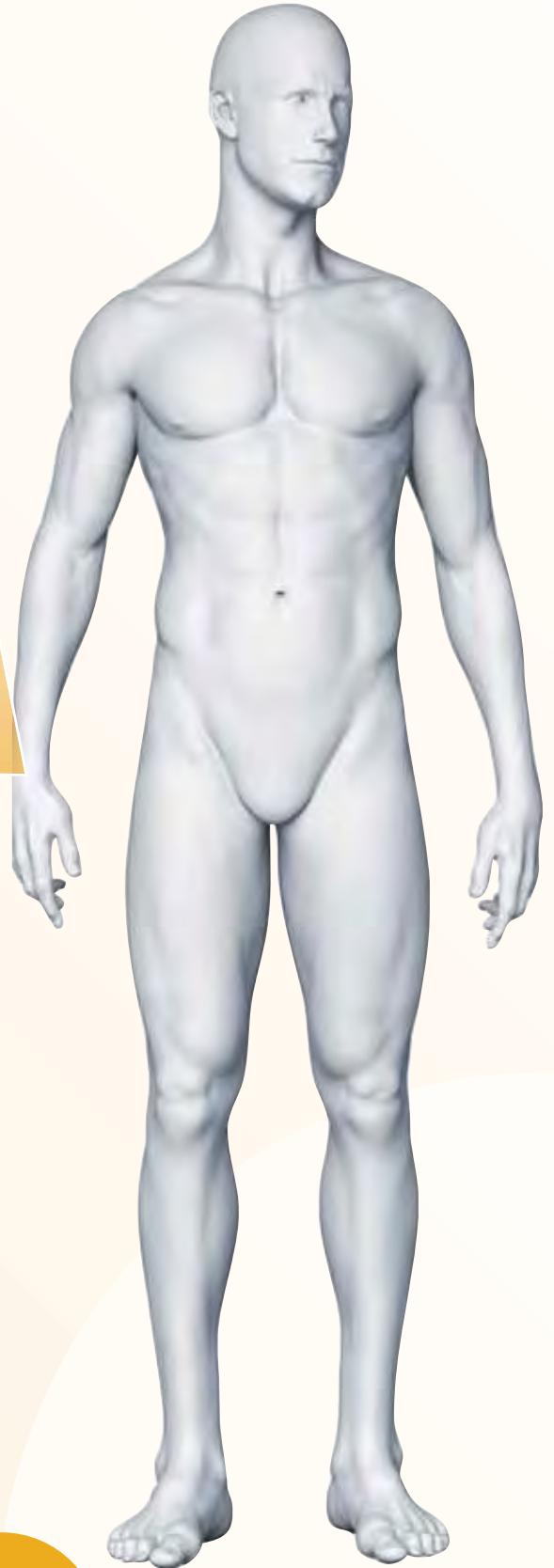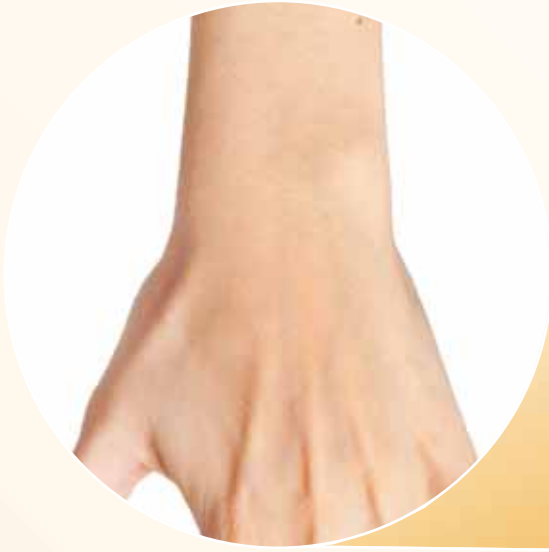ᐱᑭᐱᑦᑎᐱᑦᑭ ᐱᑭᐱᑦᑎᐱᑦᑭ  
ᑎᑭᑭᑦᑎᑭᑦᑭ

Aggaup qunnaujaangik  
Nipinngajuuk

Algaup quppiuyanga  
nipin'ngayuk

Palmure

# Wrist



◀◡◢▶◣

Aggaut

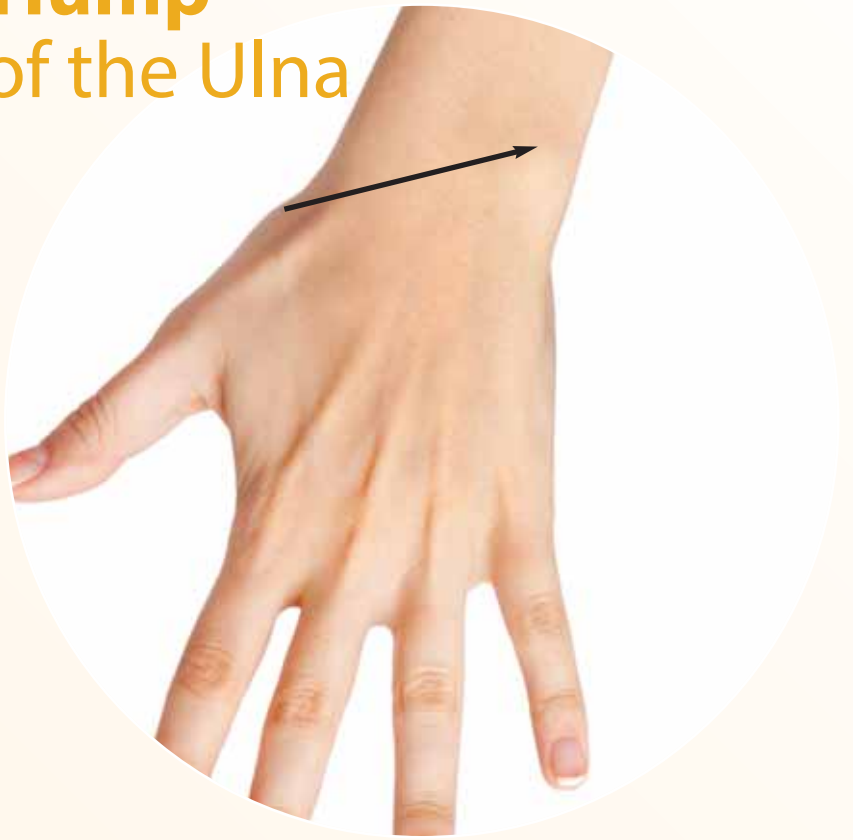Algaut

Radius et  
avant-bras,  
poignet



# Wrist Hump

## Head of the Ulna



ᐱᕐᕐᕐᕐᕐᕐᕐᕐ  
ᕐᕐᕐᕐᕐᕐᕐᕐᕐ

Aggautiup  
Qattiktunga

Algautip Ihuglua

Bosse du poignet  
(tête de l'ulna)



# Genitals/Reproductive

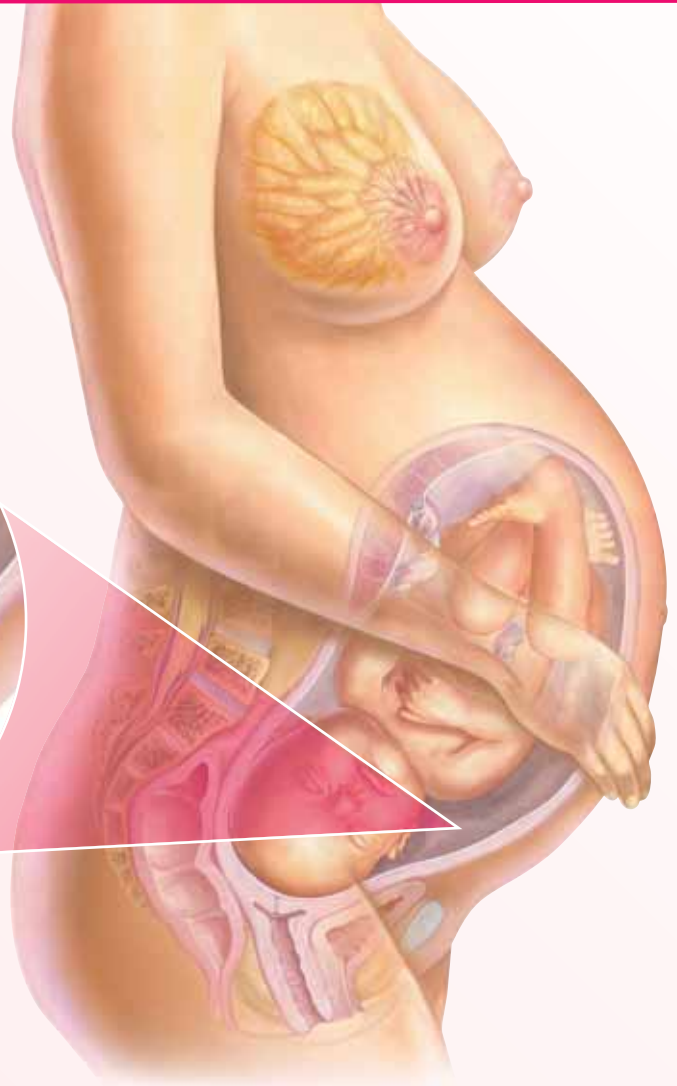
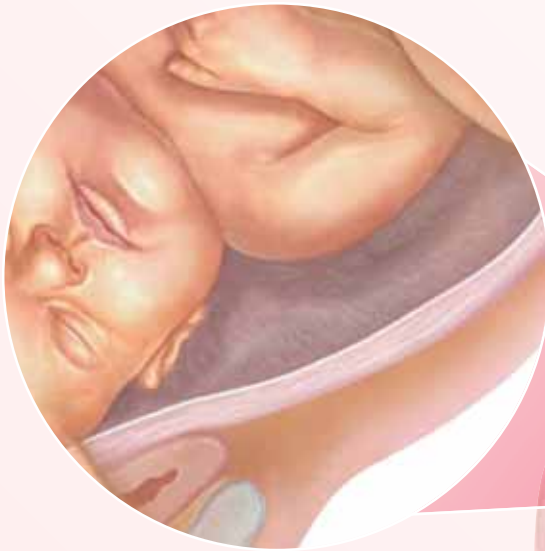ᐱᓄᓂᓂᓂ/ᓂᓂᓂᓂᓂᓂᓂ

Angmaniit/Qiturnngiuruti

Ingilrutit/Nutarannualiurutit

Organes génitaux /  
Appareil génital

# Amniotic Fluid

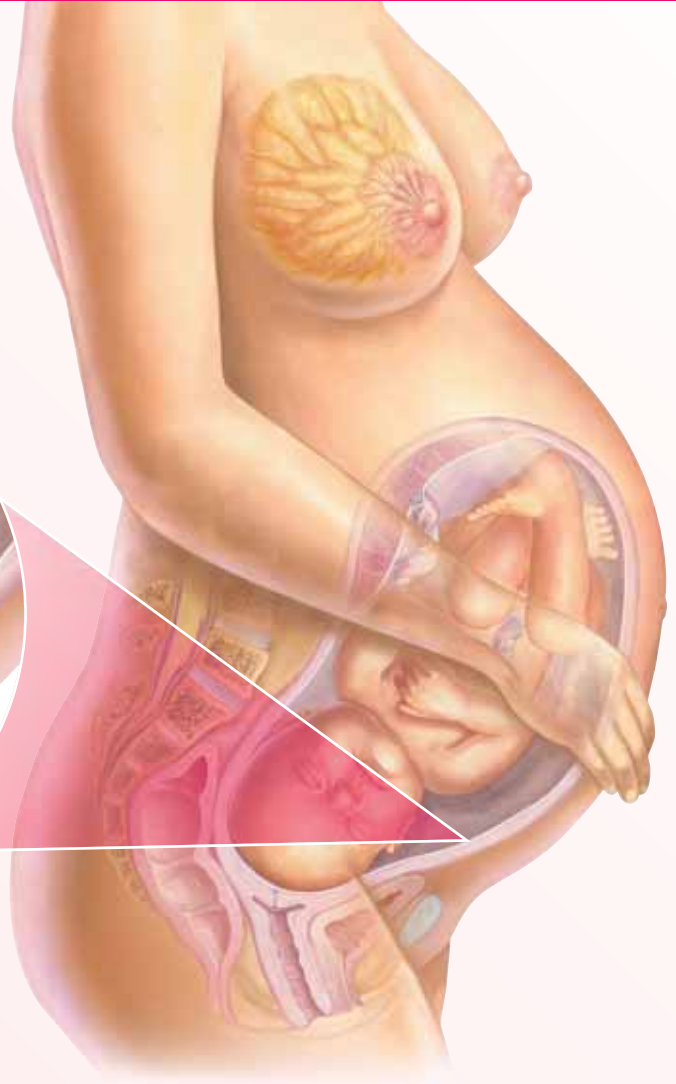
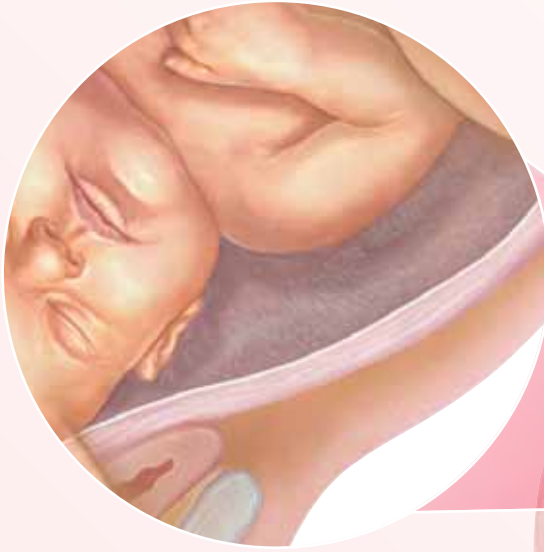

ᐃᑦᑕᑦᑲᑦᑲᑦᑲᑦ  
ᐃᑦᑲᑦᑲᑦ

Nutaraksaup Imanga  
Imaqutaa Ilumiuttap  
Liquide amniotique

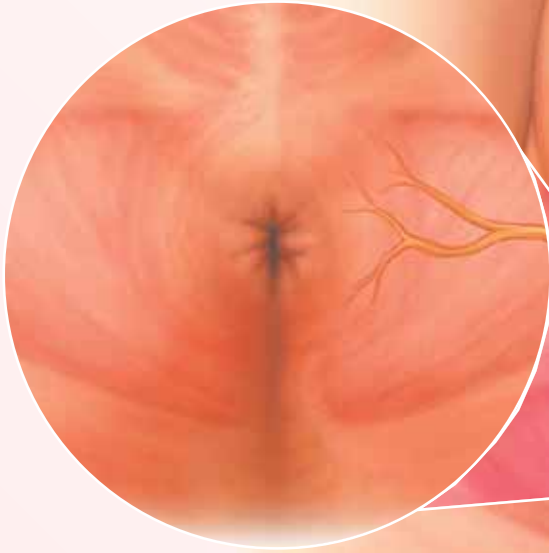

# Amniotic Sac



Puupaaq  
Imaqutip Puunga  
Poche des eaux

# Anus



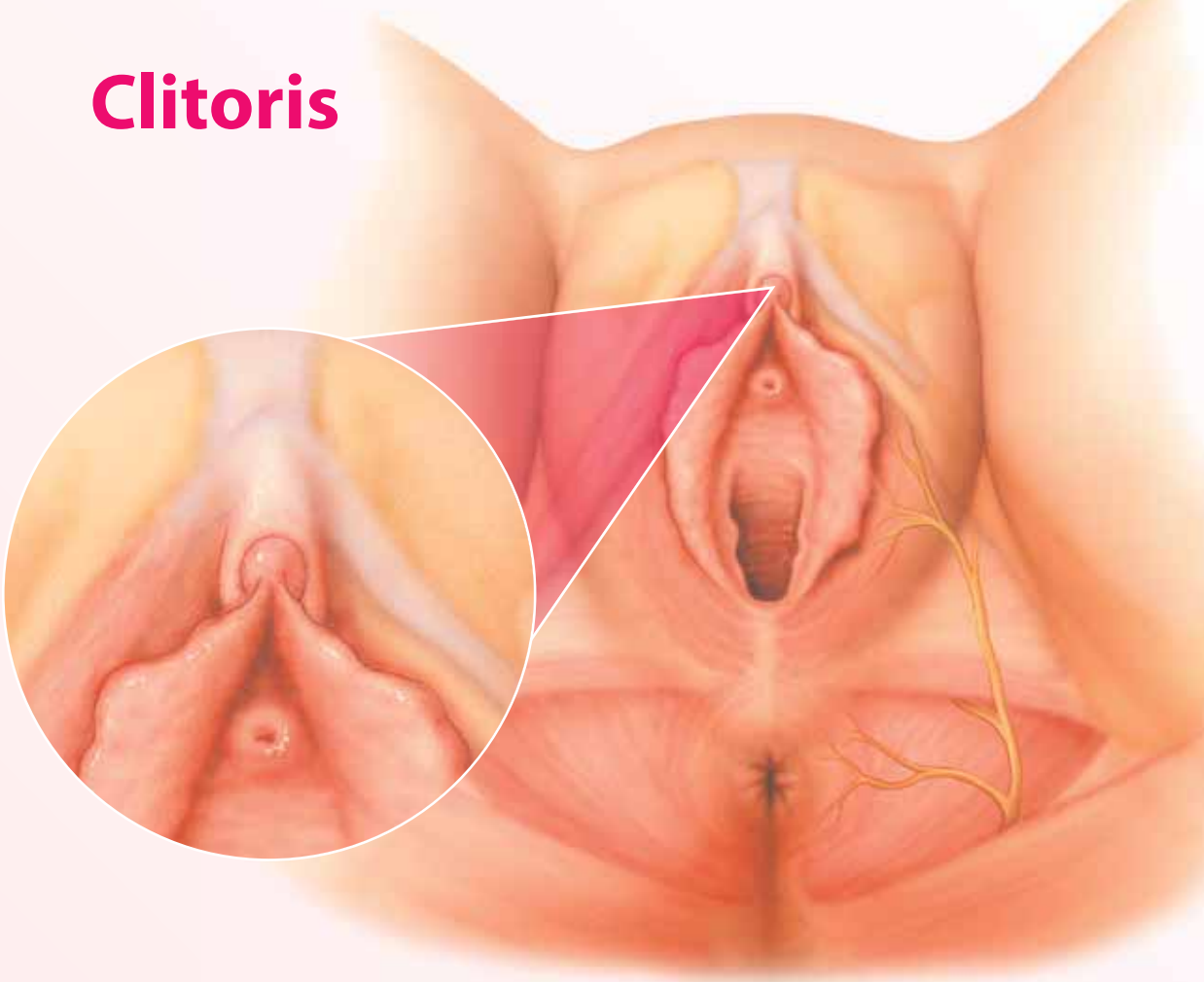
Δἰῶς

Itiq

Itiq

Anus

# Clitoris



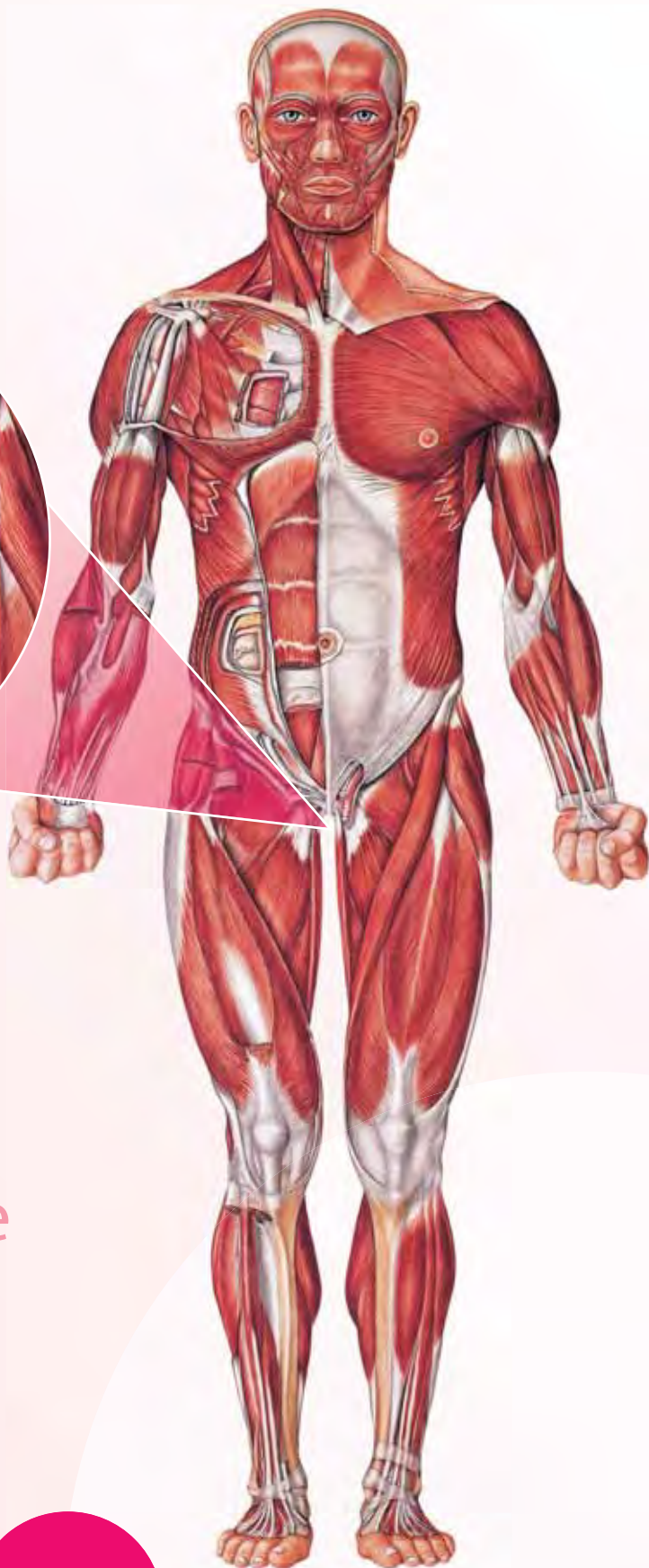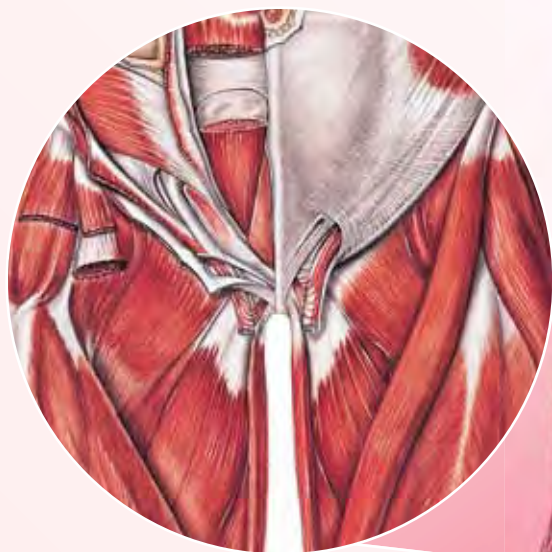
▷ 6 ▷ 9b

Uviuq

Uhuuyaq

Clitoris

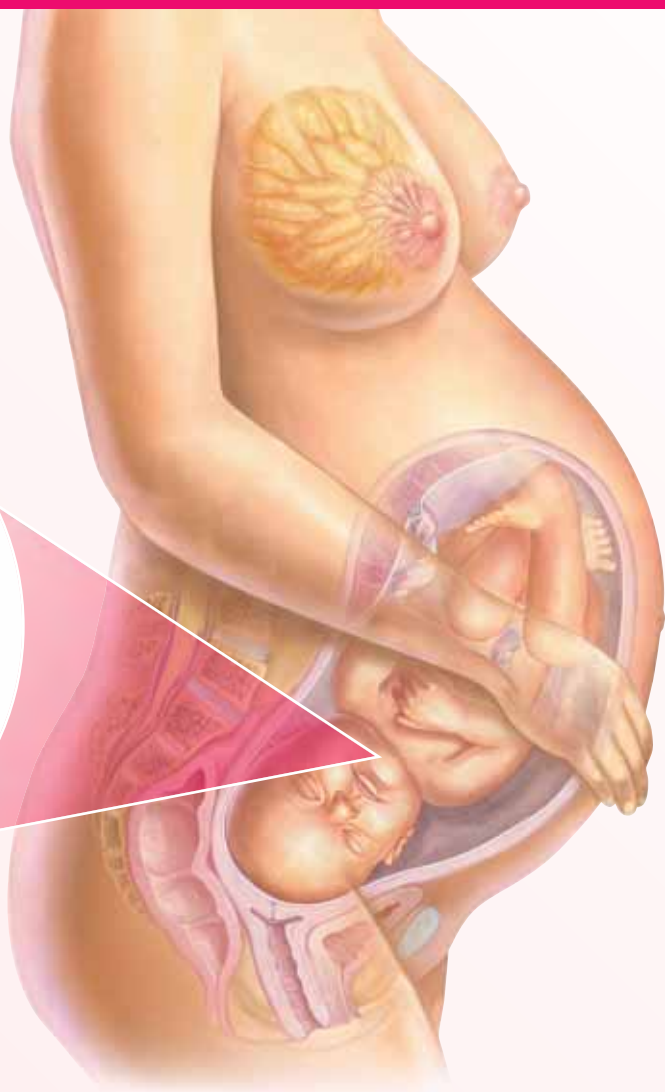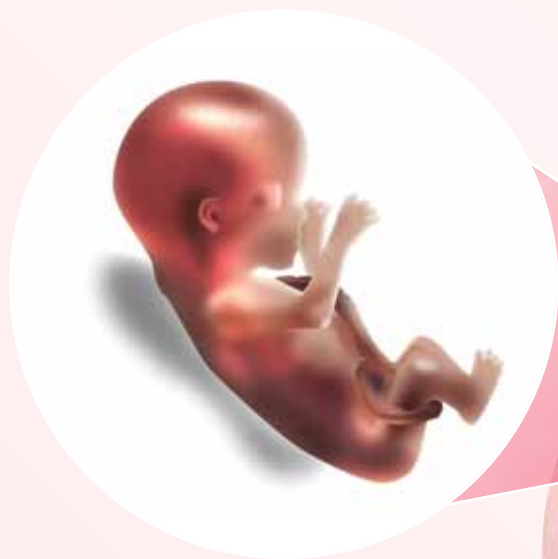# Crotch



ᐱᐃᐅᐅᐅ

Akunnaak  
Akunnaak  
Entrejambe

# Embryo, Fetus



ᑲᓴᓗᓸᑦᓂᓂ

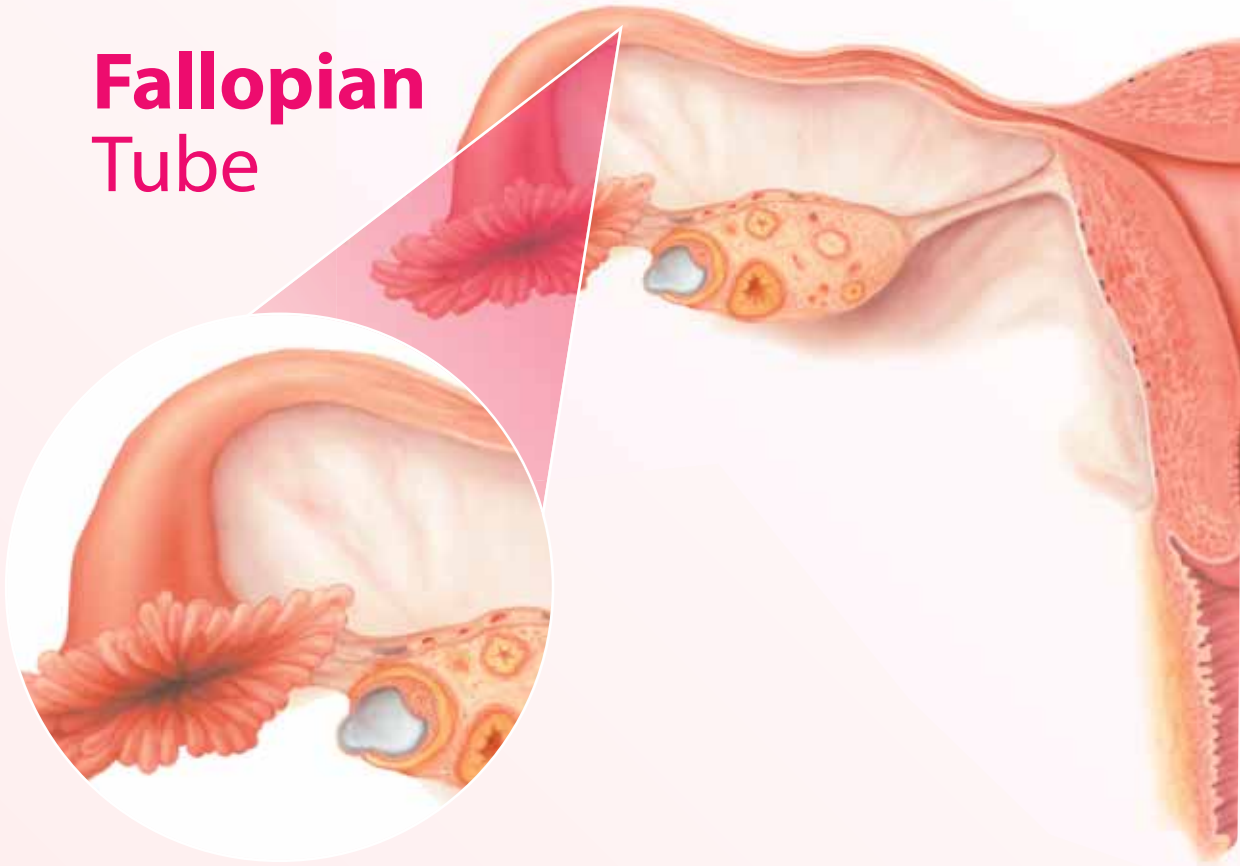
Najjiaq

Ilumiaq

Embryon, foetus



# Fallopian Tube



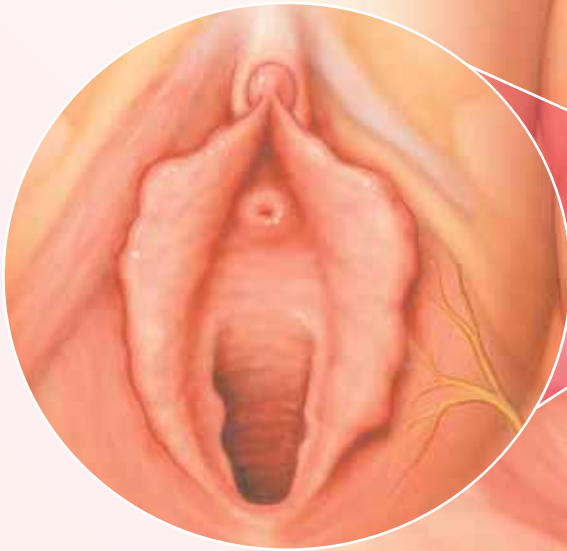
Արևակ Վճիռնիս

Igliap Attunginga

Nutarakhaup Nauvia

Trompe de fallope

# Female Genital Vagina / Vulva



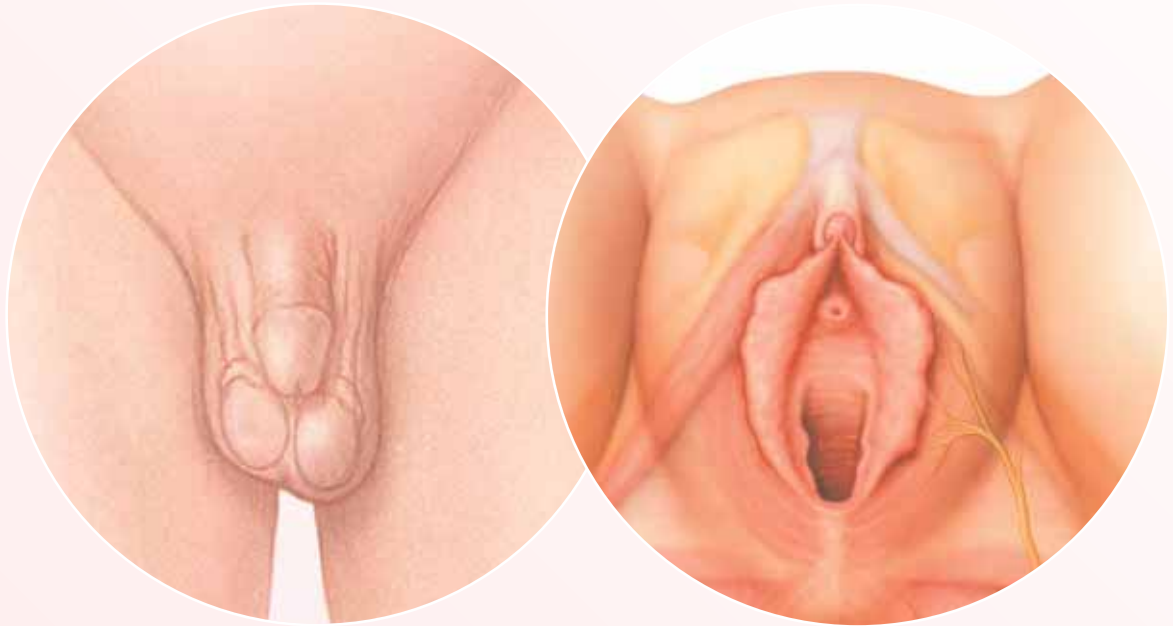
ᐱᓐᓇᓂᓐ ᐱᓐᓇᓂᓐ

Arnaup Angmaningit

Uttuuk

Organe sexuel féminin  
(vagin, vulve)

# Genitals – Male and Female



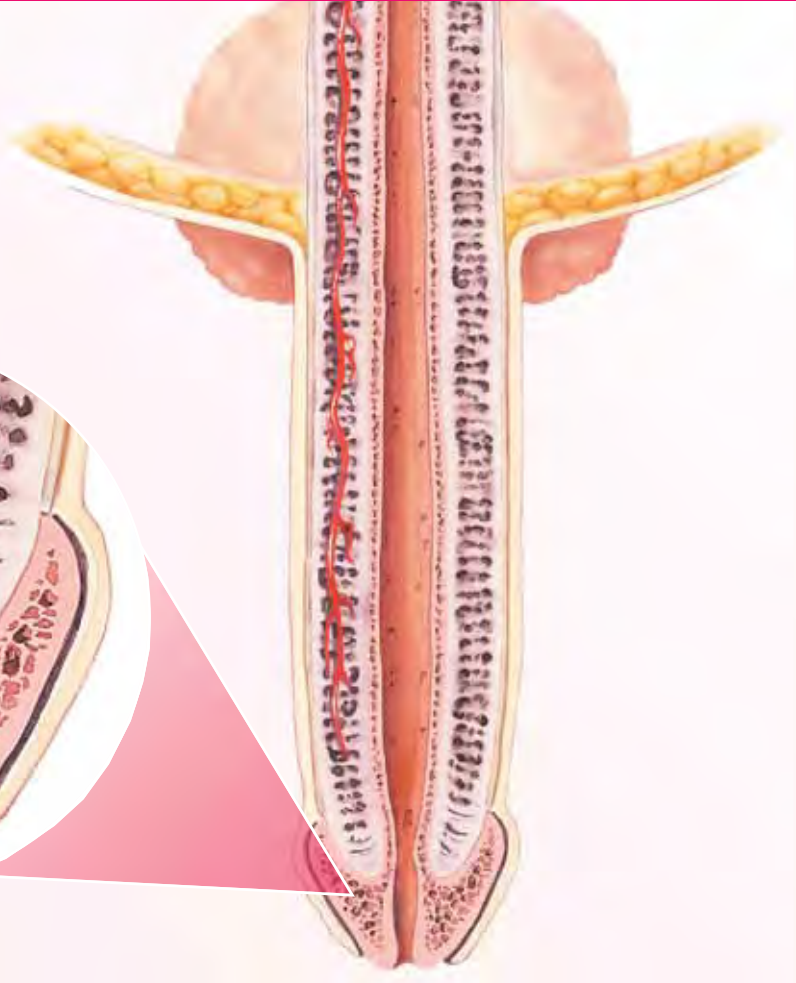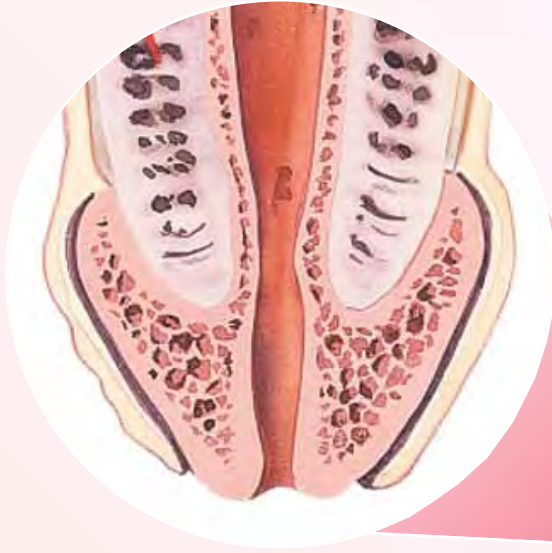ᐱᑦᓴᑦᓴᑦᓴᑦ ᐱᑦᓴᑦᓴᑦᓴᑦ

Angutiup Arnallu

Angutit Arnallu Ingilrutait

Génitaux – mâle et femelle

# Glans Penis



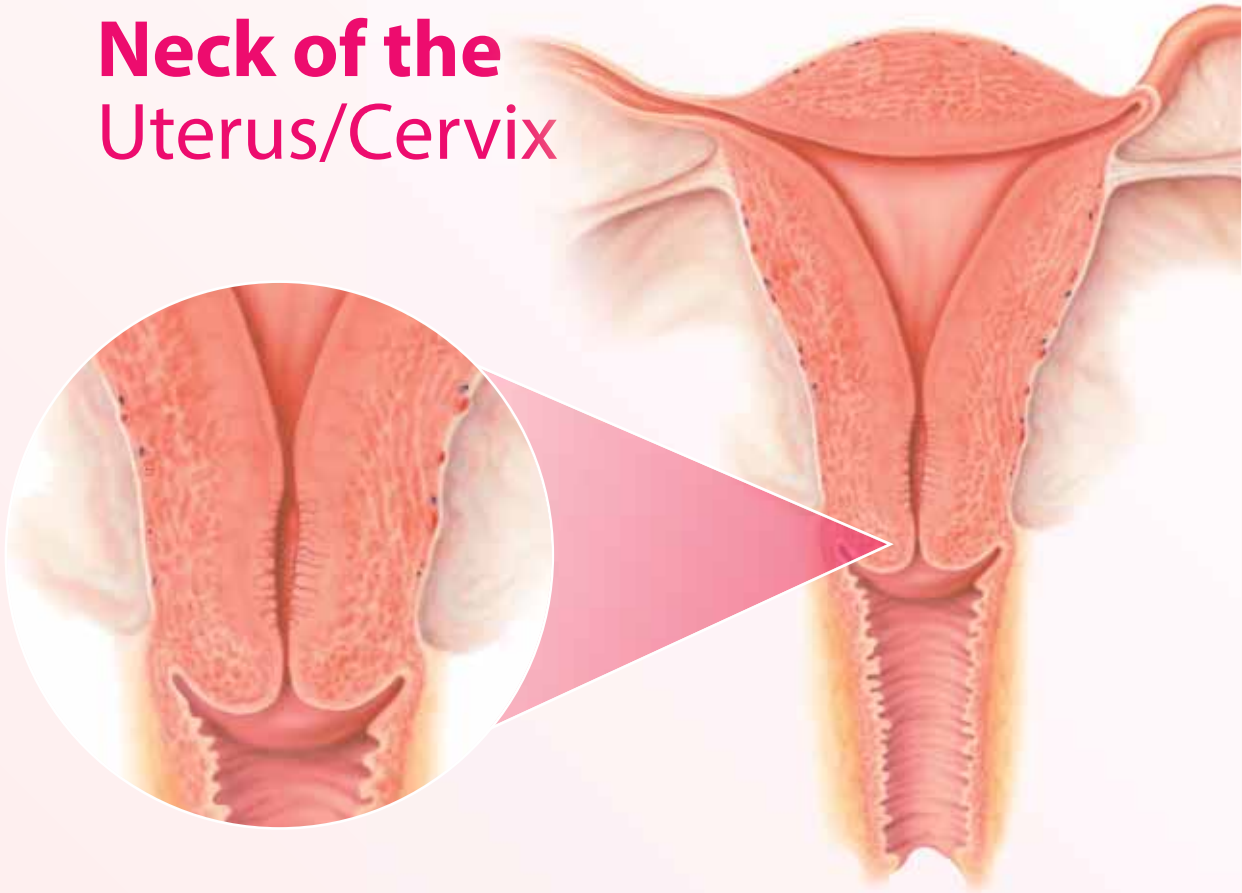
ᐃᑦᑦᑦᑦᑦᑦ

Ulivvaq

Uhuup Nuvua

Gland

# Neck of the Uterus/Cervix



ᐃᑭᑦᑲᑦᑲᑦ ᑲᑲᑲᑲᑲᑲ

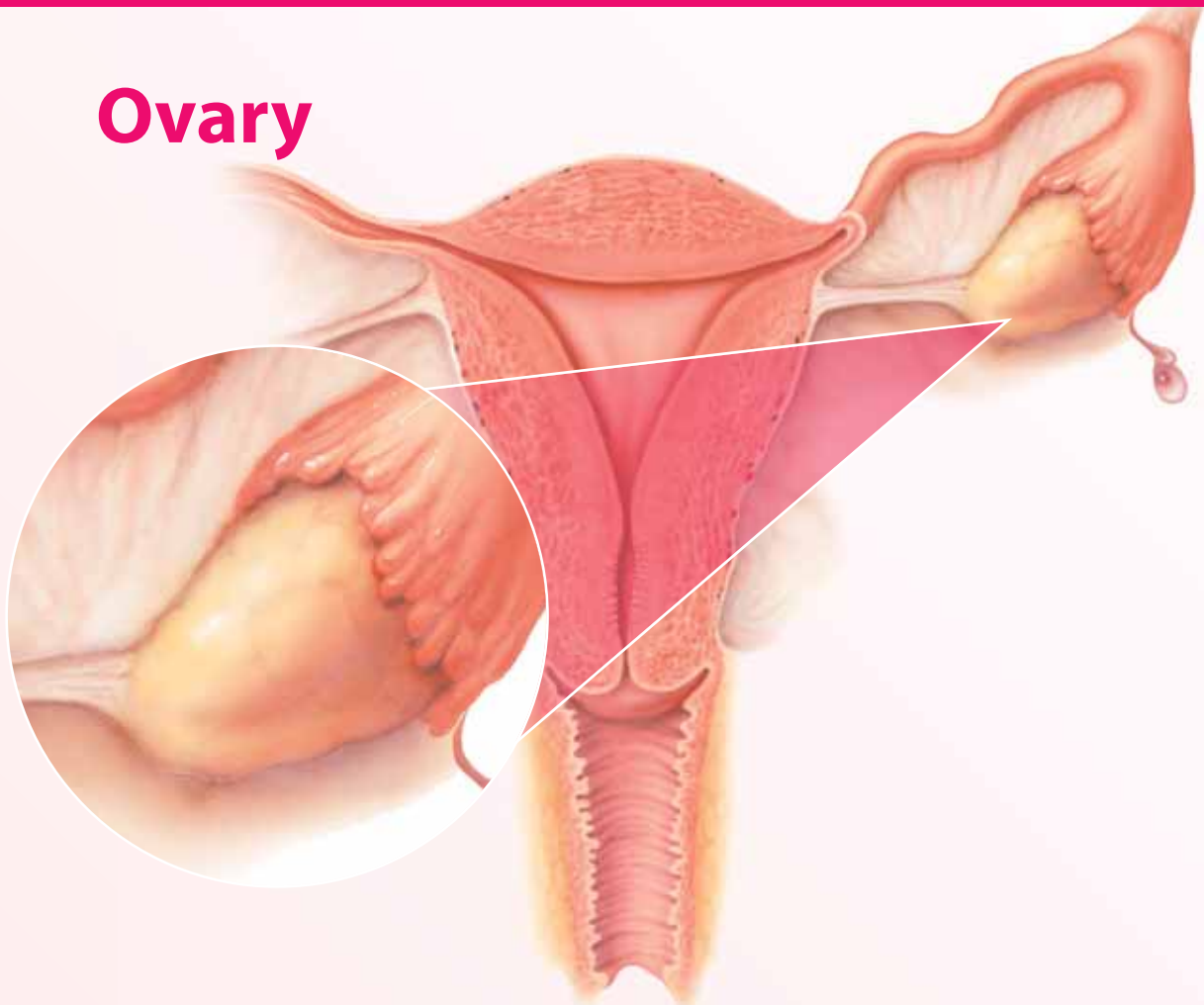
Igliap Quuqqanga

Igliap Qaanga

Col de l'utérus



# Ovary



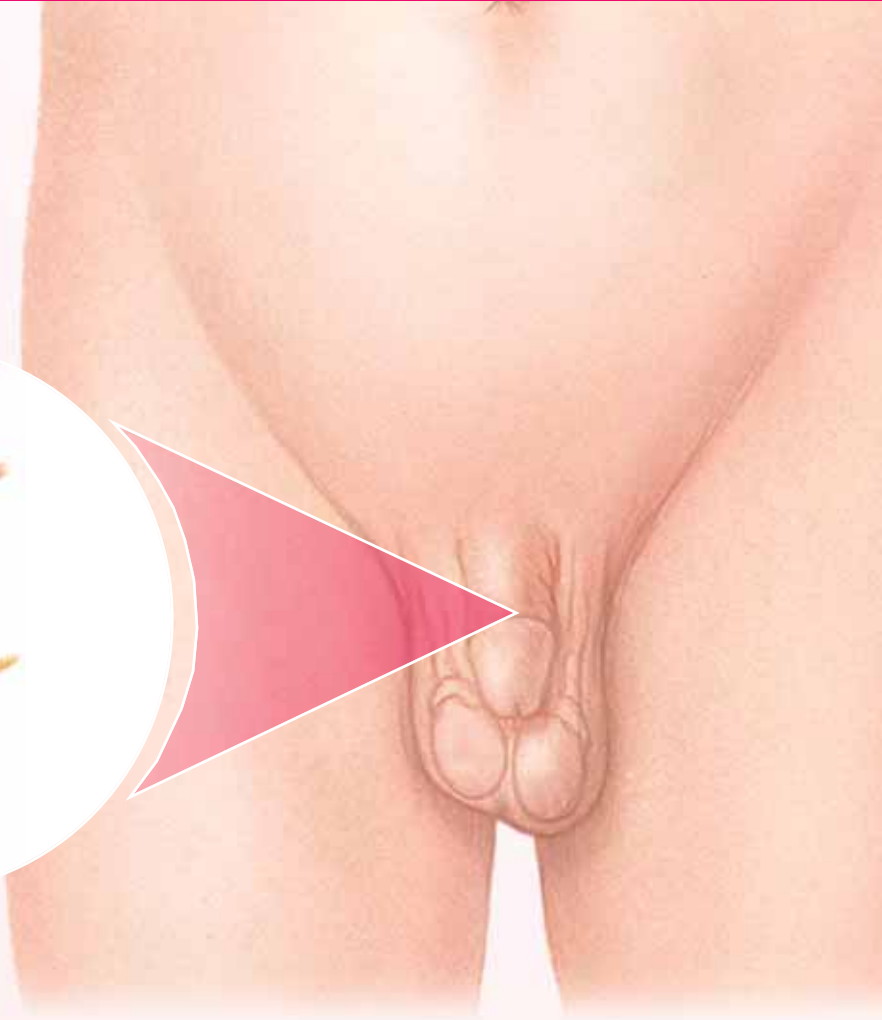
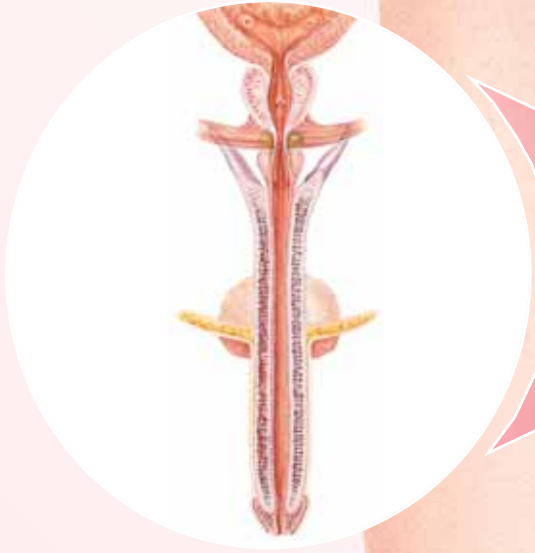ᐱᓃᓄᐅᓃ ᐱᓃᓃᓃᐅᐱᓃᓂ

Arnaup Manniqautinga

Igliaq

Ovaire

# Penis



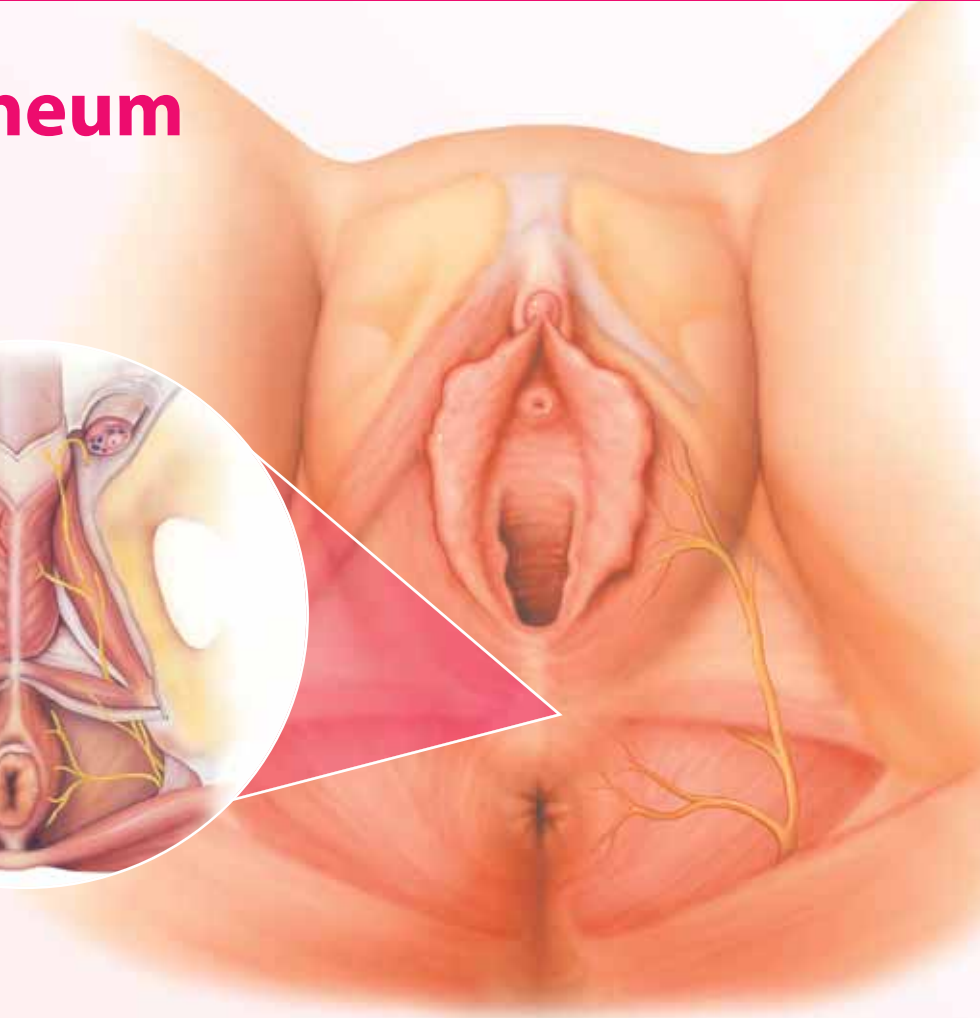
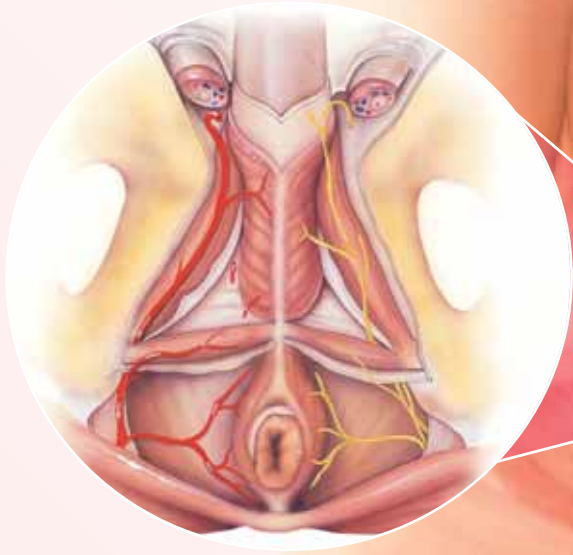
بدر

Usuk

Uhuk

Pénis

# Perineum



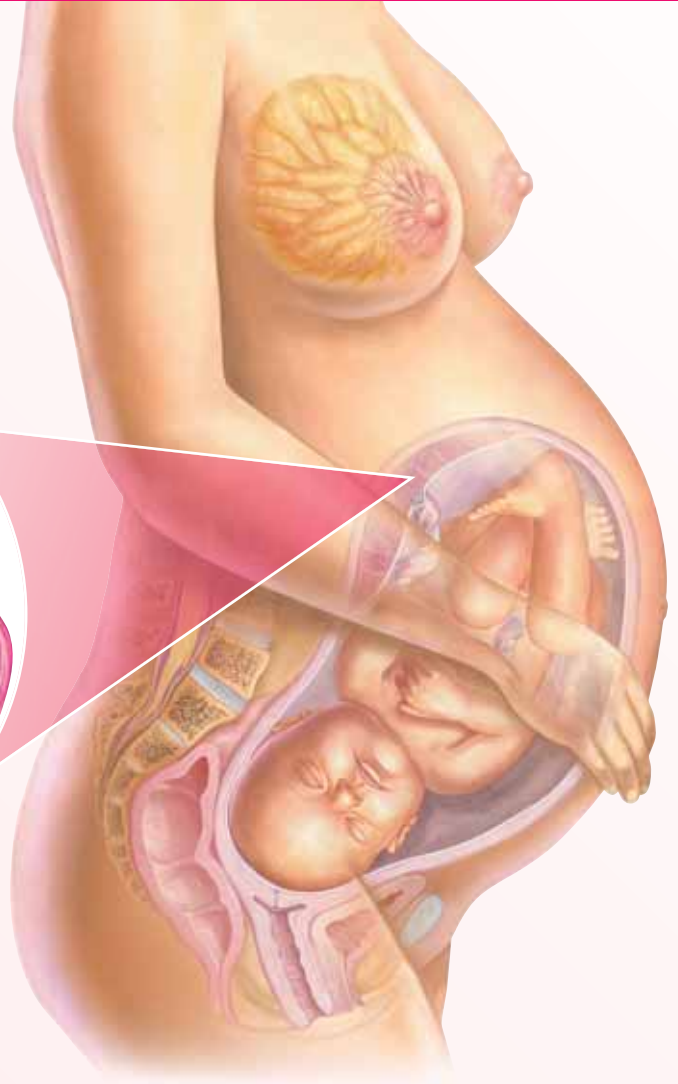
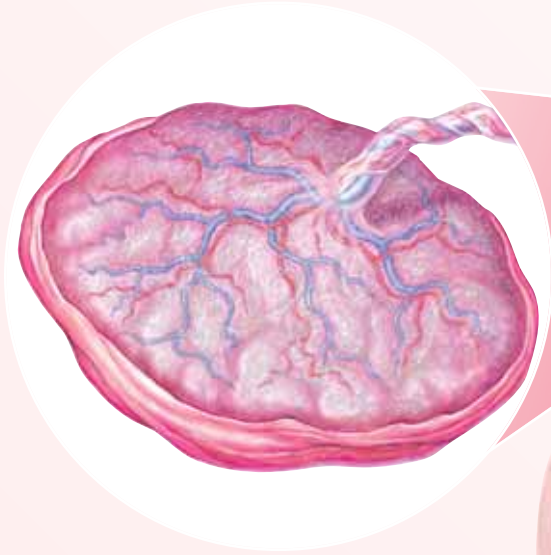
ᐱᕈᕐ ᐱᕈᕐ

Qilluaq

Attakilruq

Périnée

# Placenta



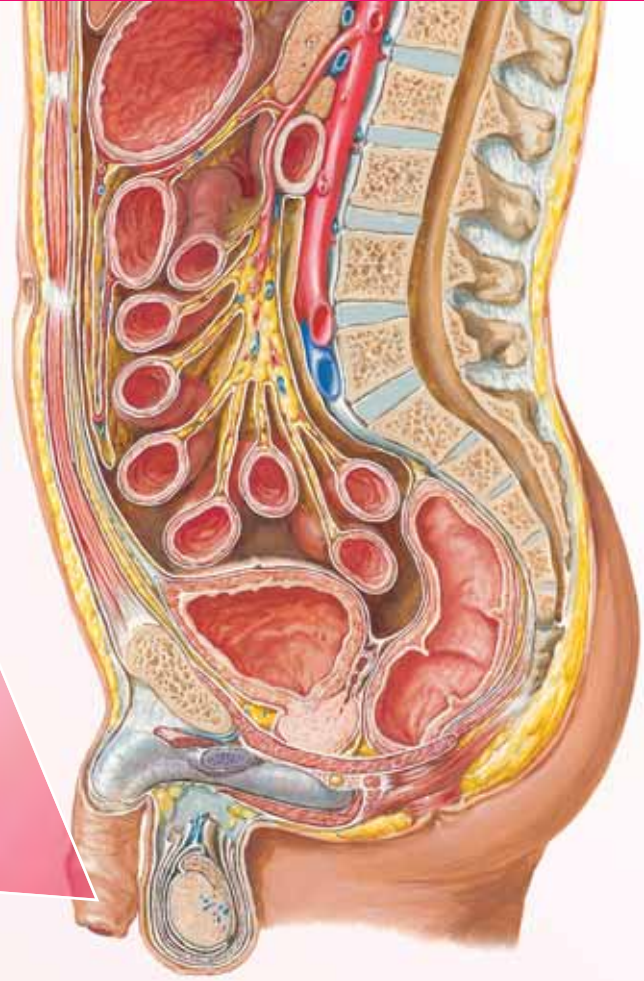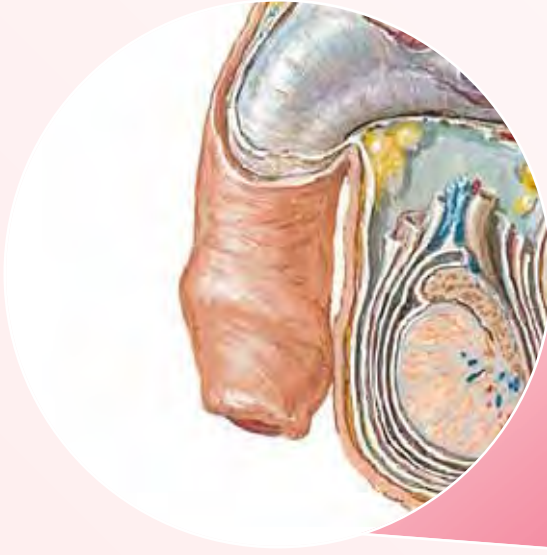
ᐱᕐᕐᕐᕐ

Arraaq

Alraaq

Placenta

# Prepuce / Foreskin



ᐱᐱᐱᐱᐱᐱ

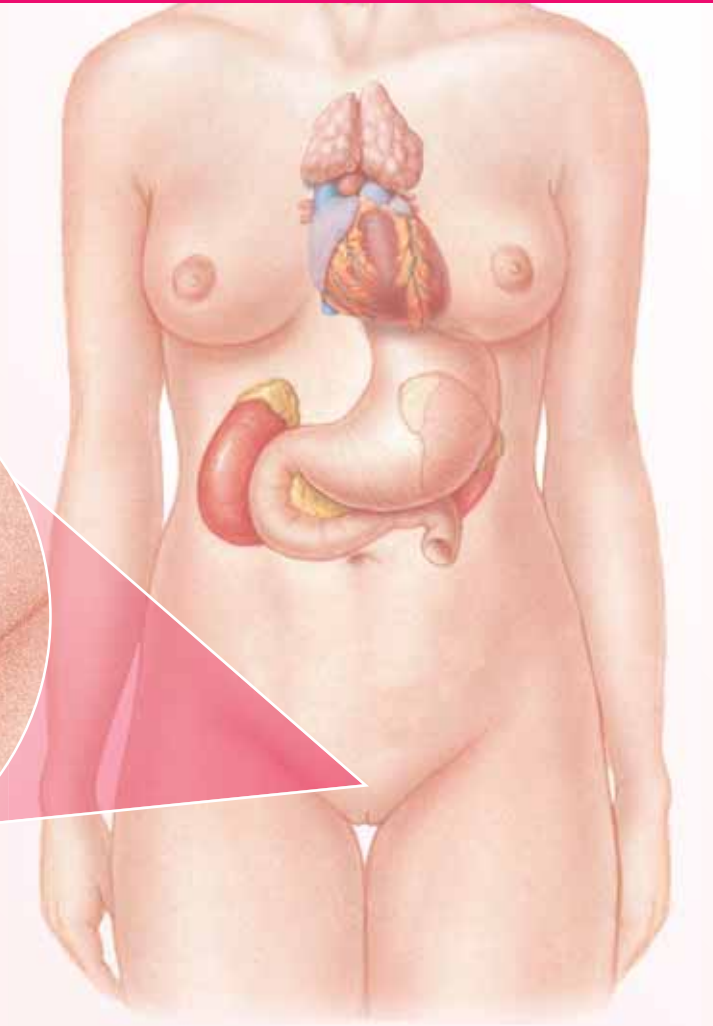
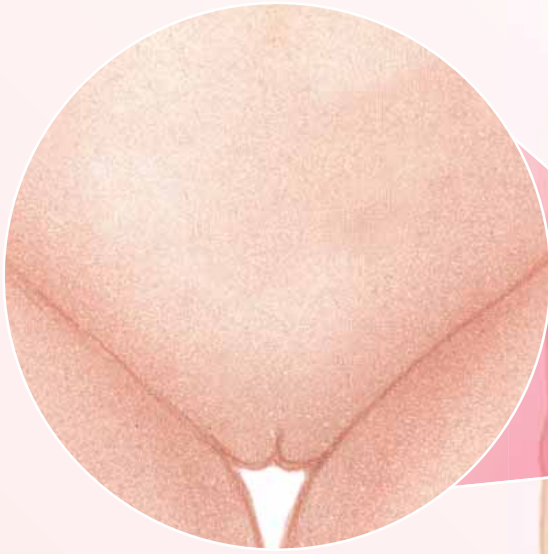Paasiniq

Puungata Nuvua

Prépuce



# Pubic Area



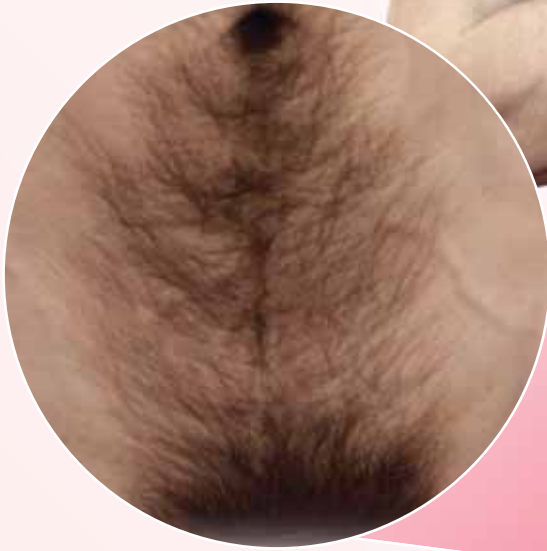ᐃᓴᓂ

Ingi

Ingik

Région pubienne

# Pubic Hair



Ո՞՛ՐԸ

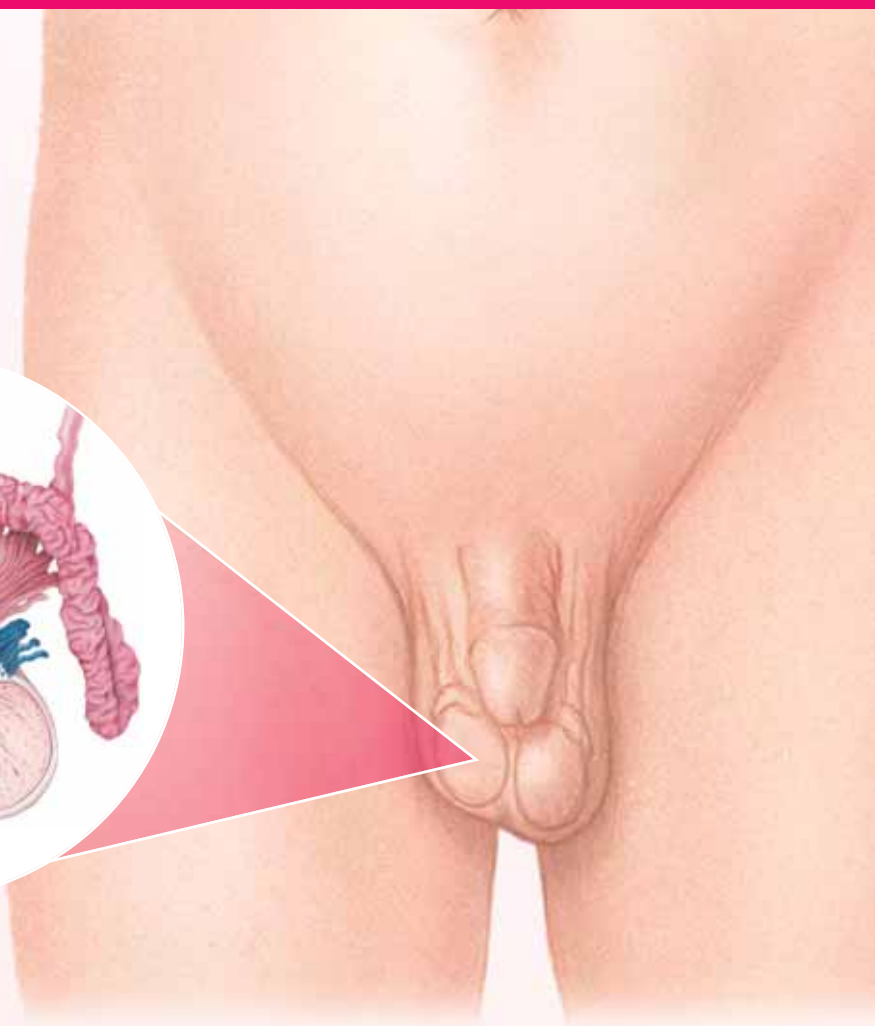
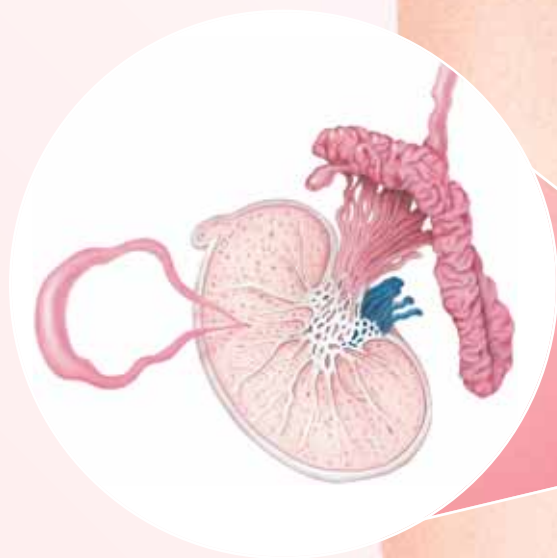Tingit

Tingiq

Poils pubiens



# Testicle



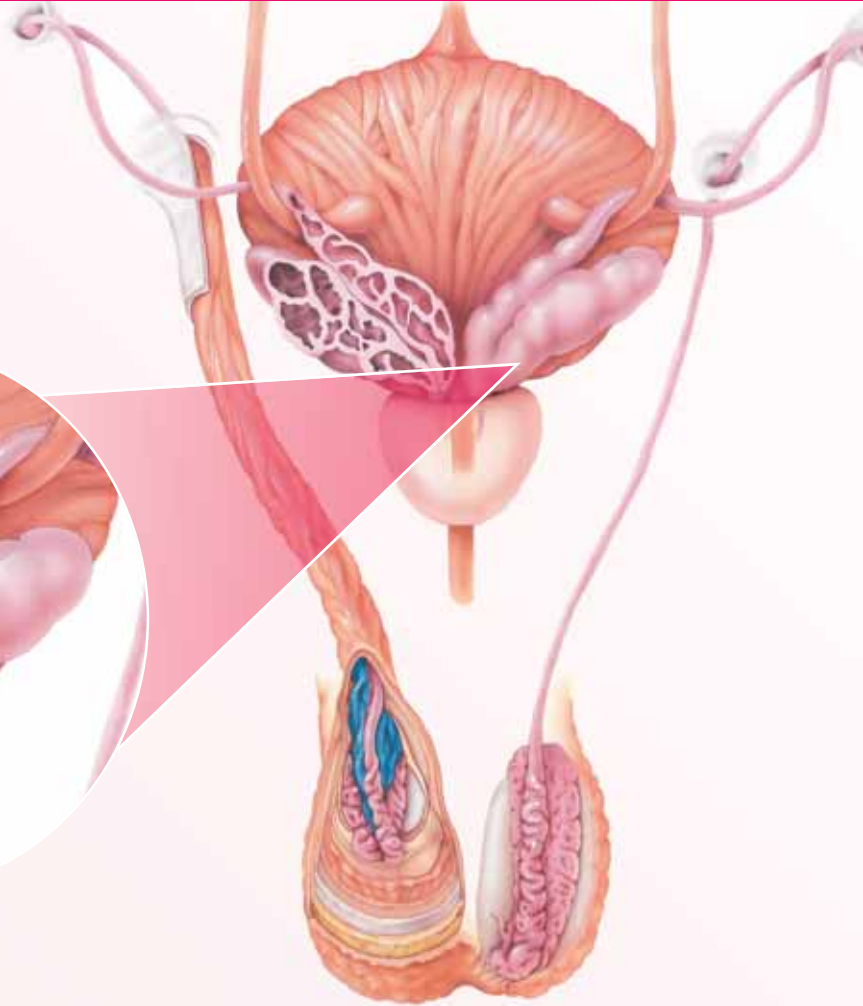
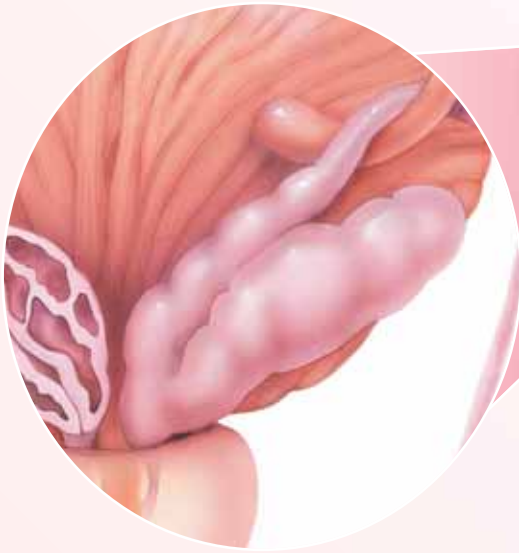ᐃᓕᓴᓂ

Igjuk

Igyuuk

Testicule

# Testicle Seminal Gland



ᐃᐸᐸᐸ ᐸᐸᐸᐸᐸᐸᐸᐸ

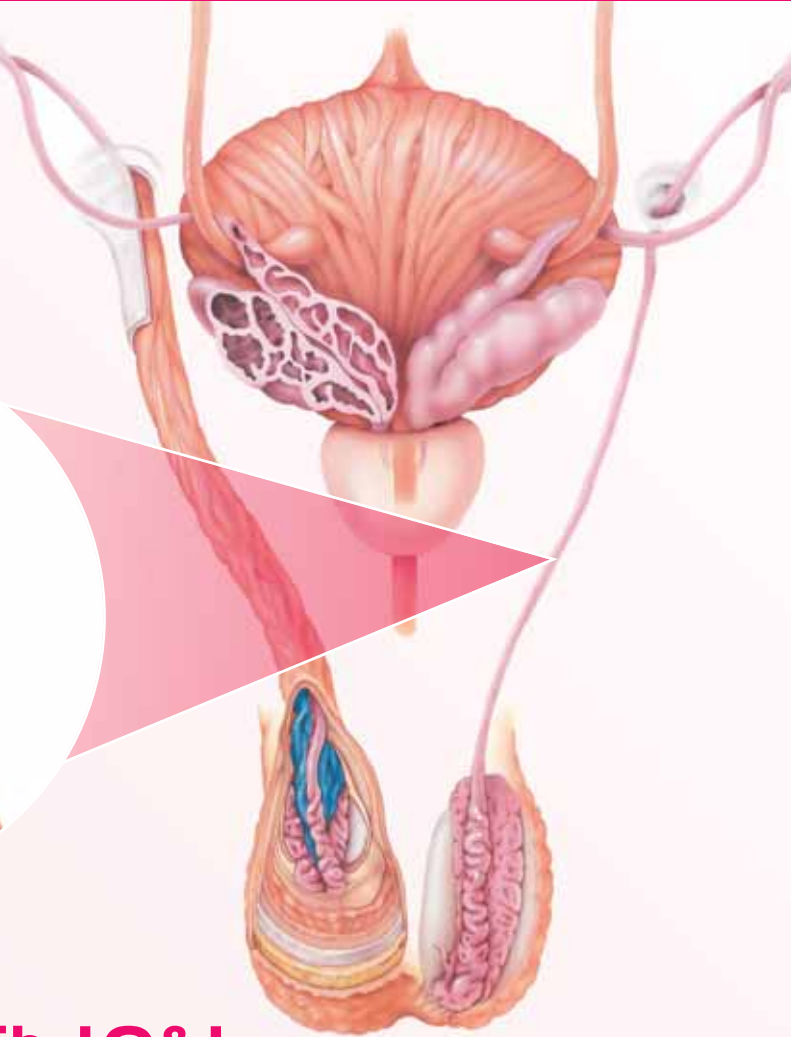
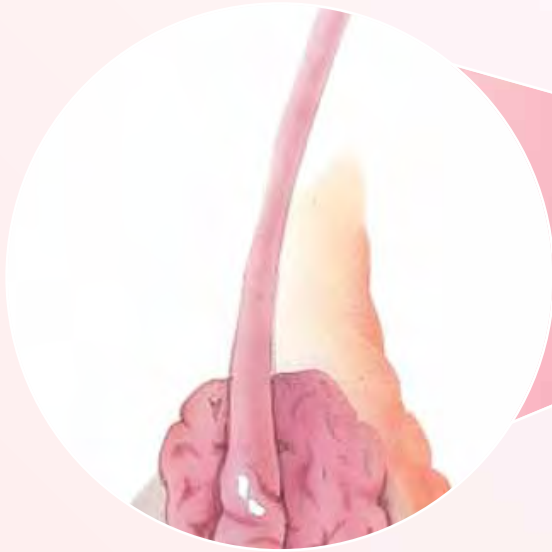Igjuup Qapaliurutinga

Qapuliurut

Testicule, glande séminale



# Testicular Duct / Vas Deferens



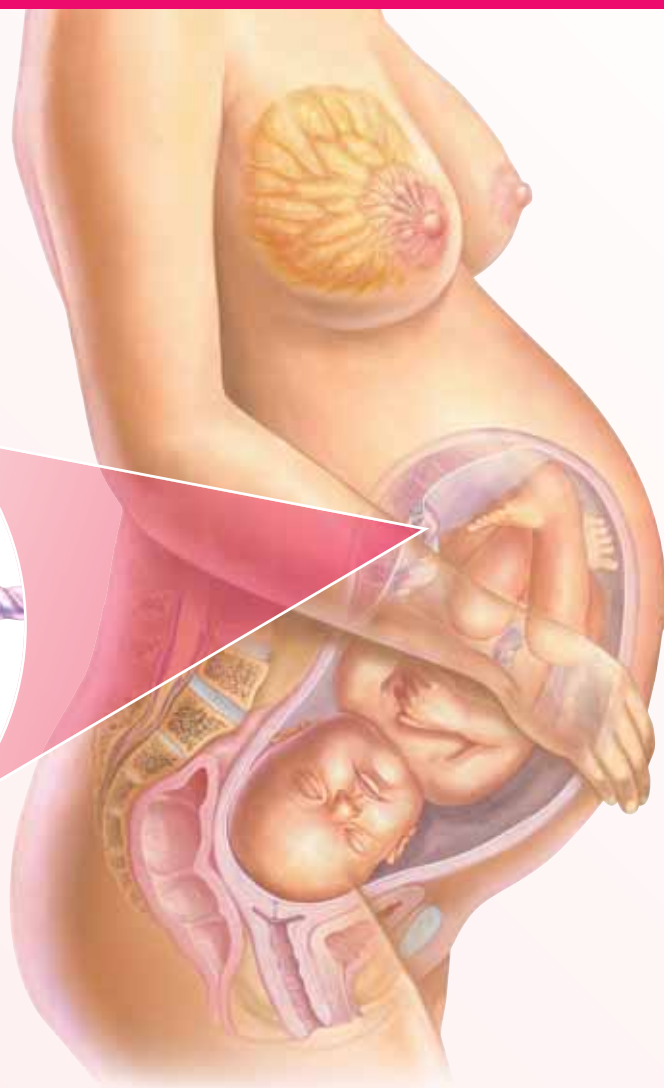
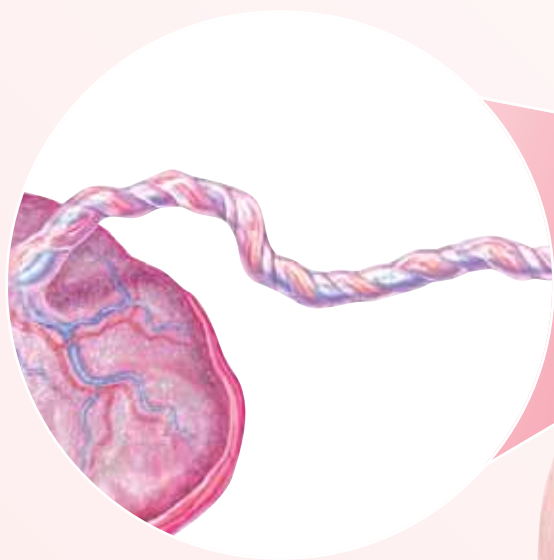
ፍጅፋፈፄፄፄ ፄፍጅፄፅፅፅ

Qapaup Aqqutinga

Qapuup Apqutaa

Canal déférent

# Umbilical Cord



ᠮᠢᠬᠢᠶᠢᠨ

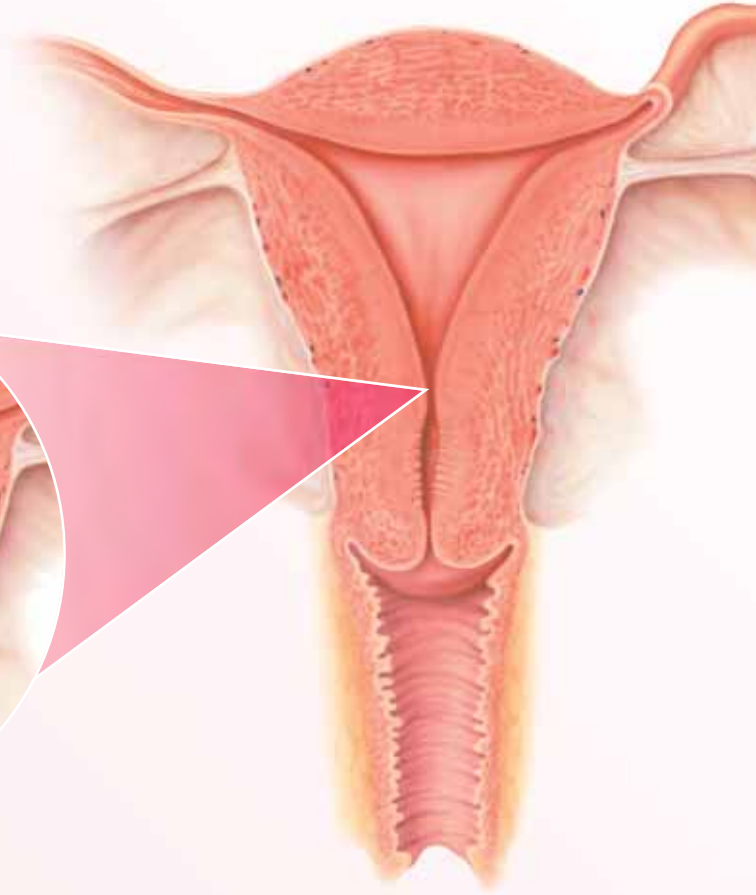
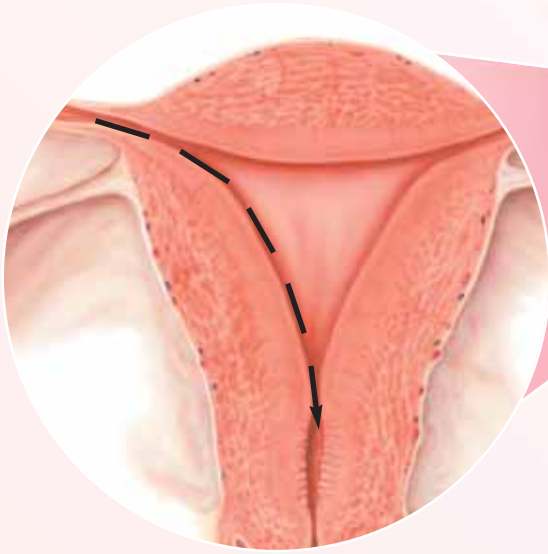
Mik᠊iaq

Mikhiaq

Cordon ombilical



# Uterine Tube



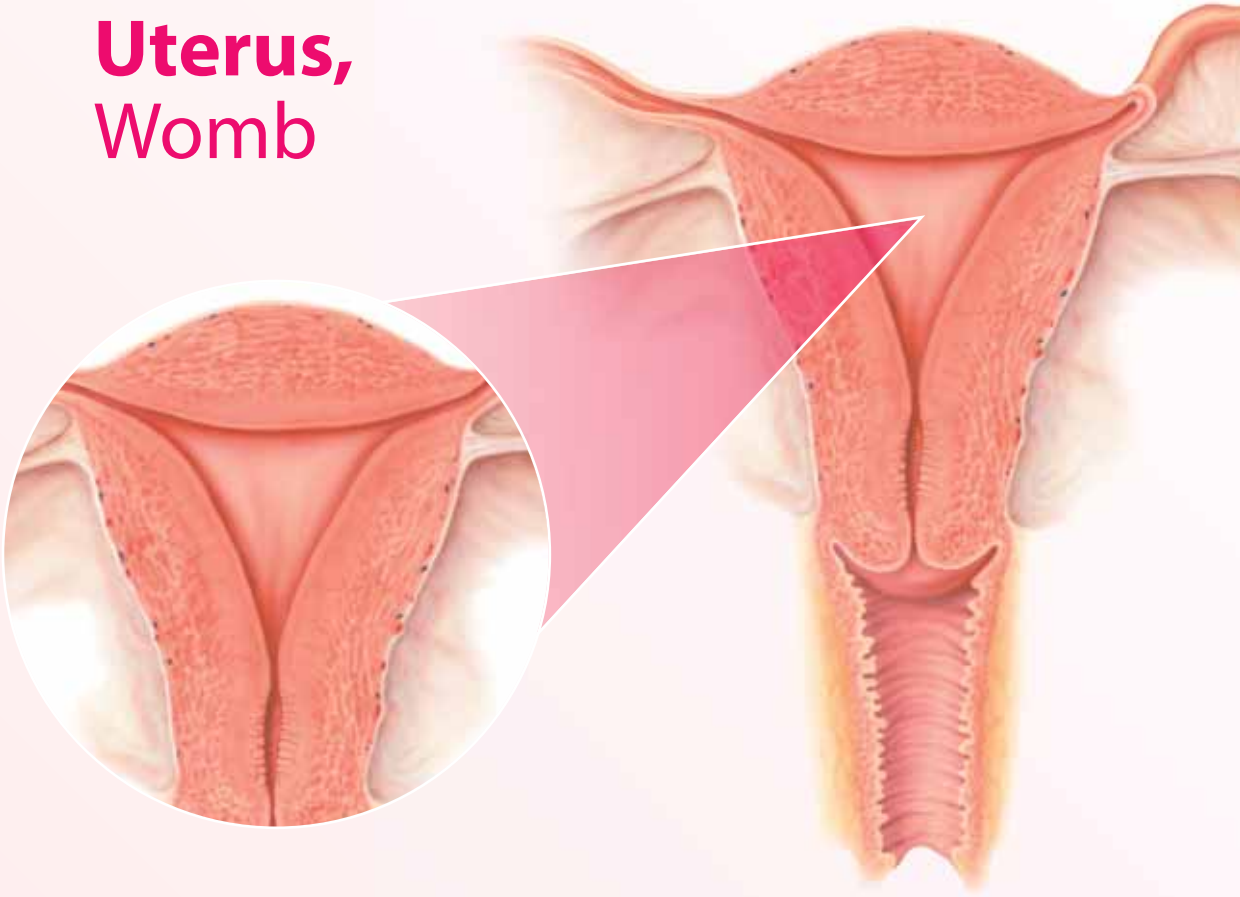
Լ՞օժ՝Ձ՛ Ձ՛ԳԵԺՈ՞Ն

Manniup Aqqutinga

Igliap Tuqhuanga

Trompe utérine

# Uterus, Womb



ᐃᐅᐅᐅᐅᐅᐅ

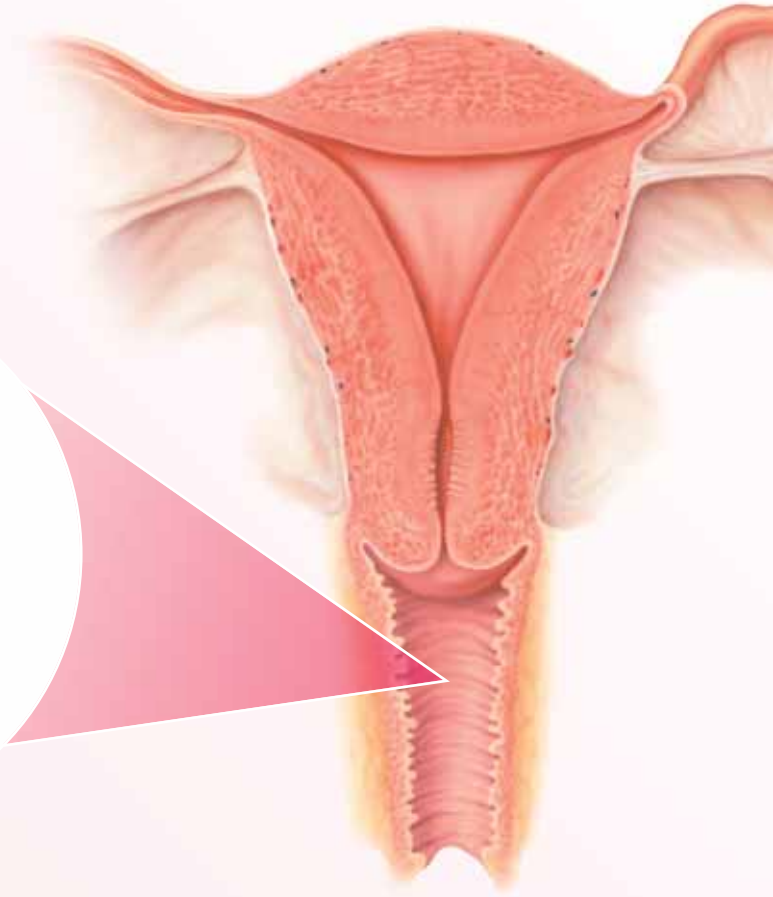
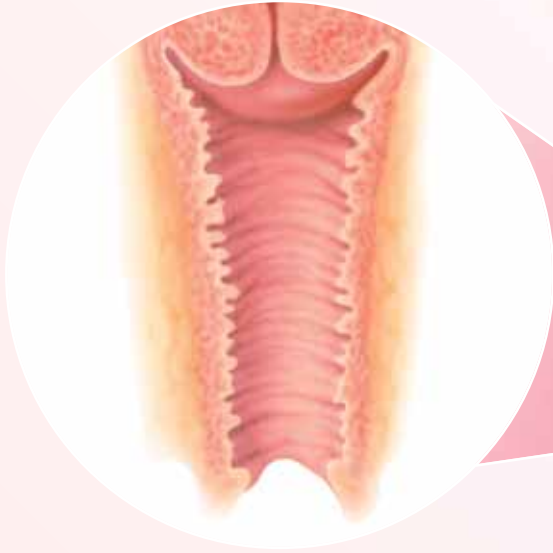Igliaq

Igliaq

Utérus, matrice



# Vagina



ᑲᑦᑲᑦ

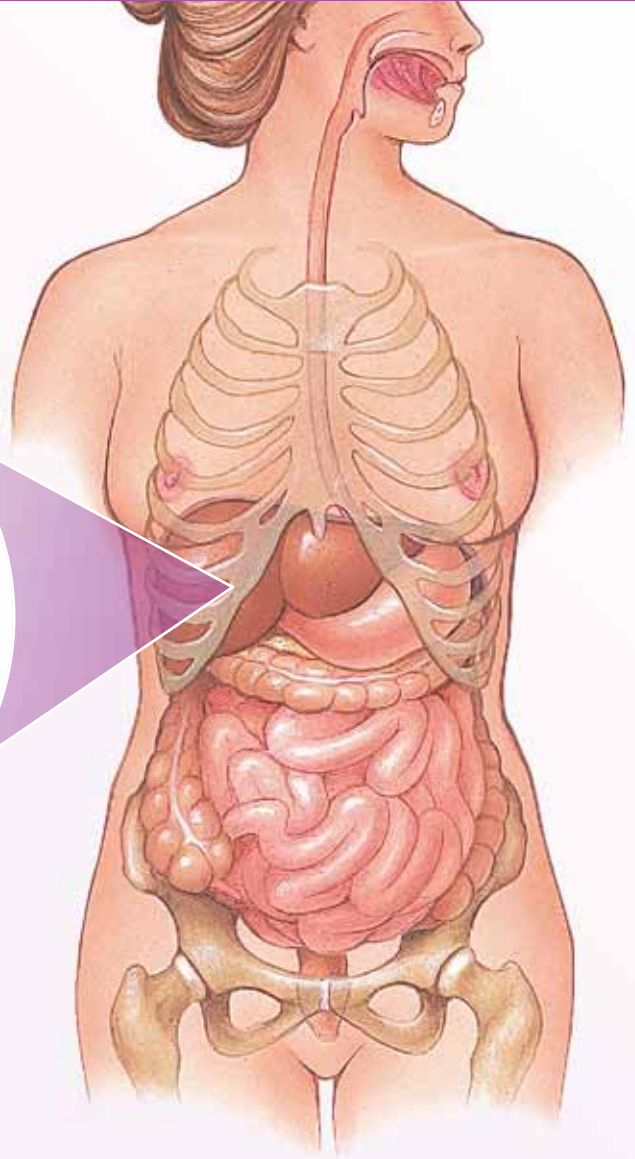
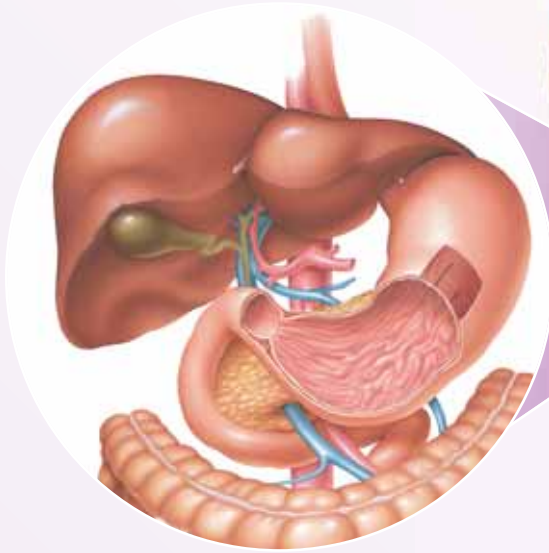Kavvik

Uttuuk

Vagin



# Bile / Gall / Gall Bladder



سۇنغاق

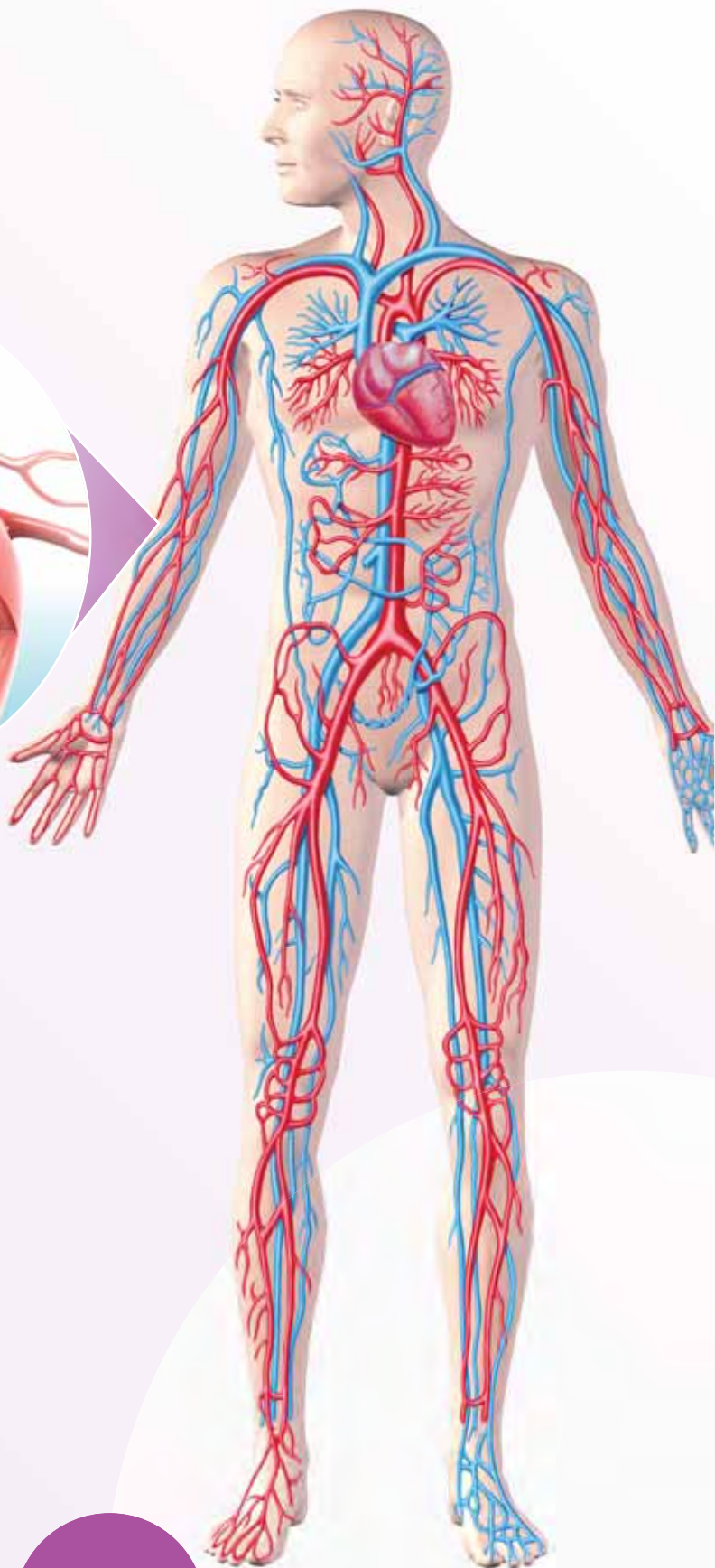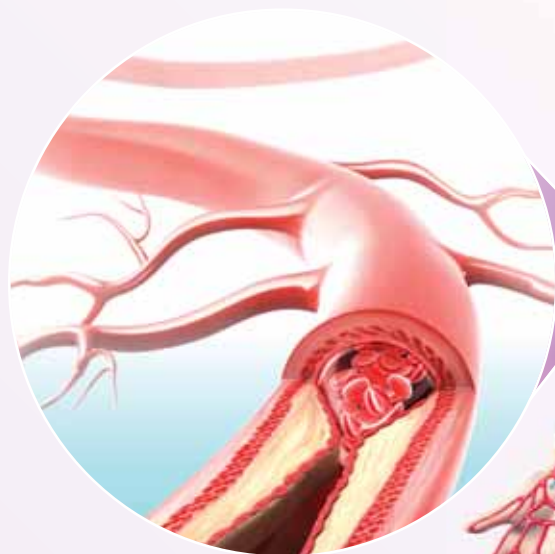Sungaq

Hungaq

Bile, vésicule  
biliaire



# Blood



◀▶<sup>b</sup>

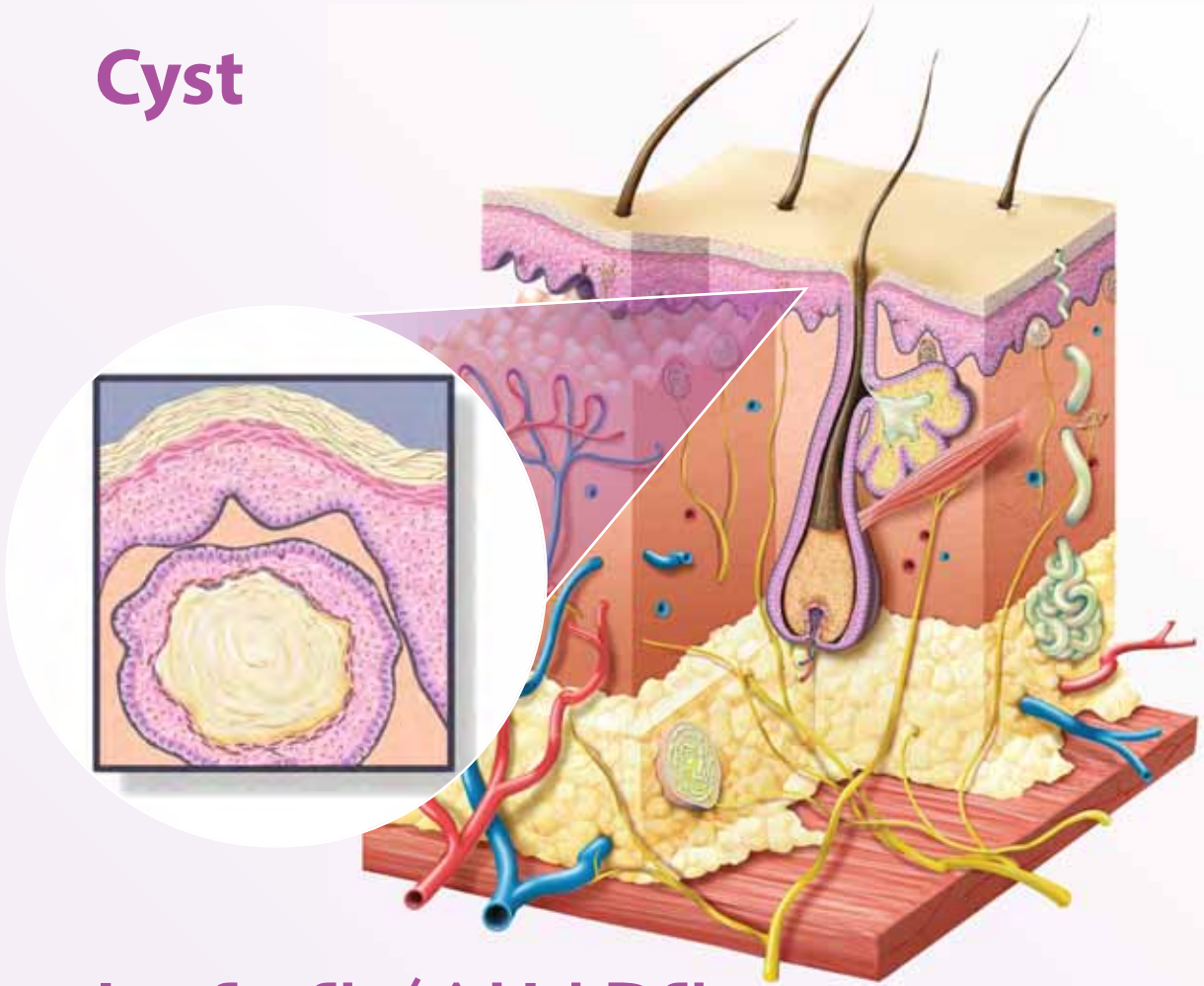
Auk

Auk

Sang



# Cyst



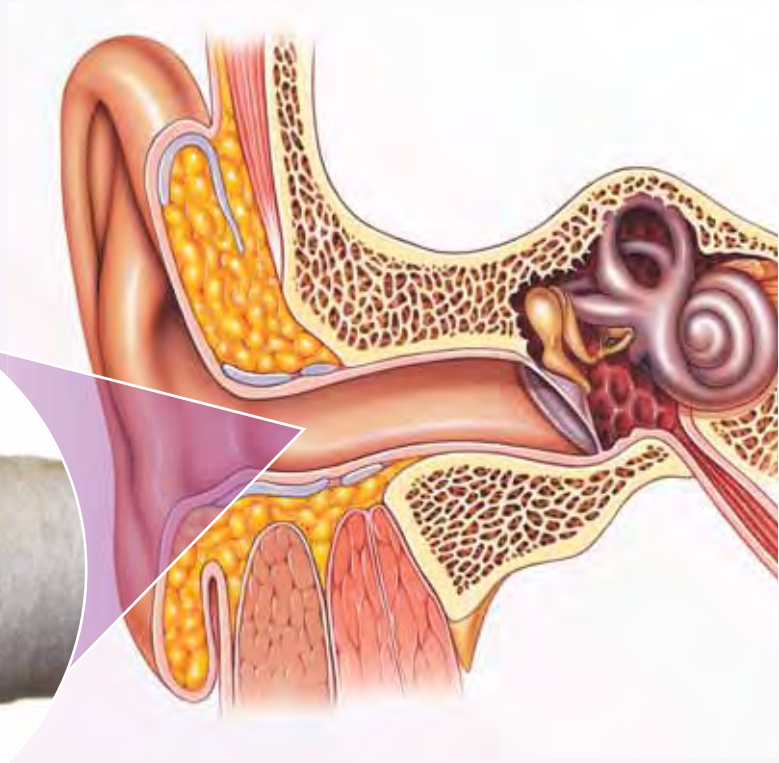
ᐱᓄᓐᓇᓐ / ᐱᓄᓐᓇᓐ

Manirnaq/immaktuq

Nauyiniq

Loupe

# Ear Wax



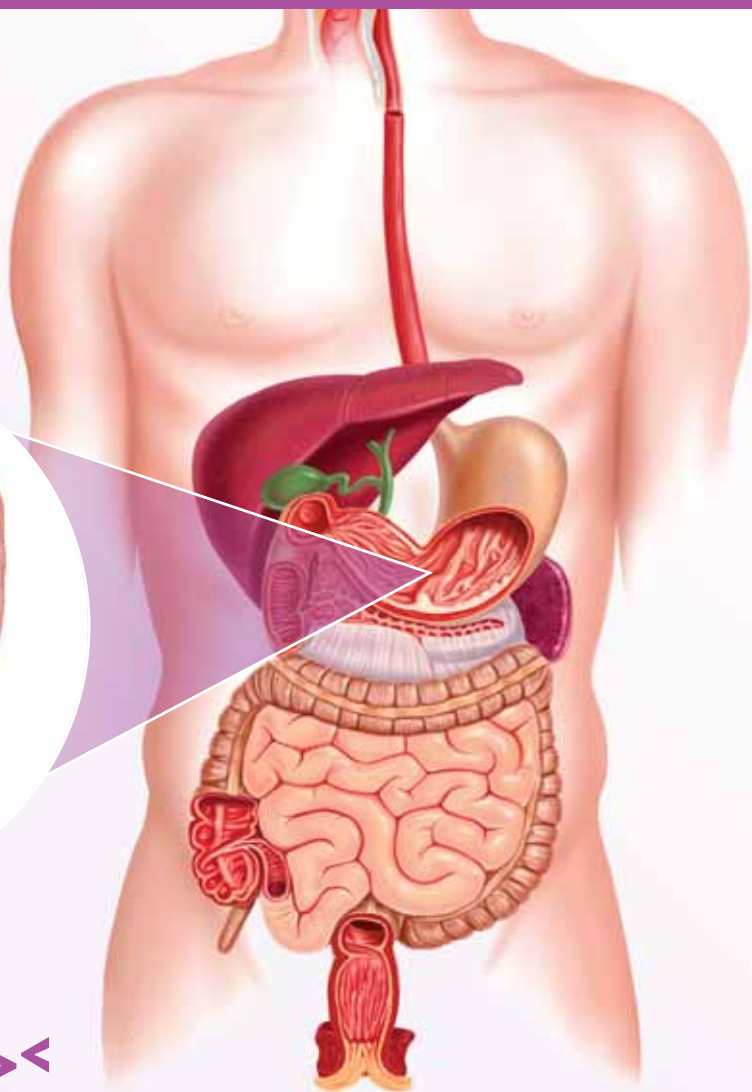
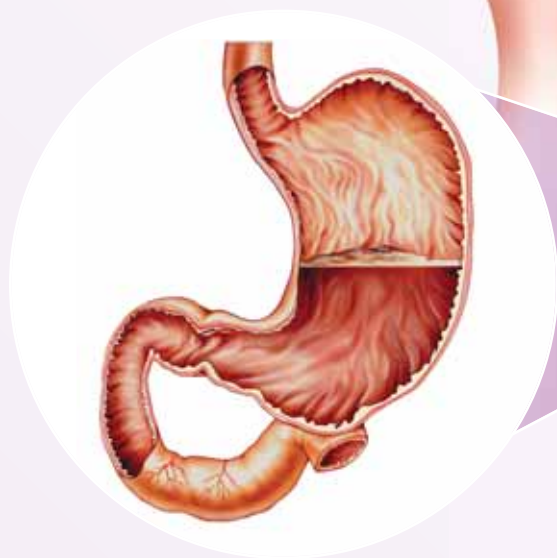ᑭᐃᑎᑦ ᐃᑦᑭᑦᑭᑦ

Siutimit issaaqijuq

Hikhik

Cérumen/Tympan

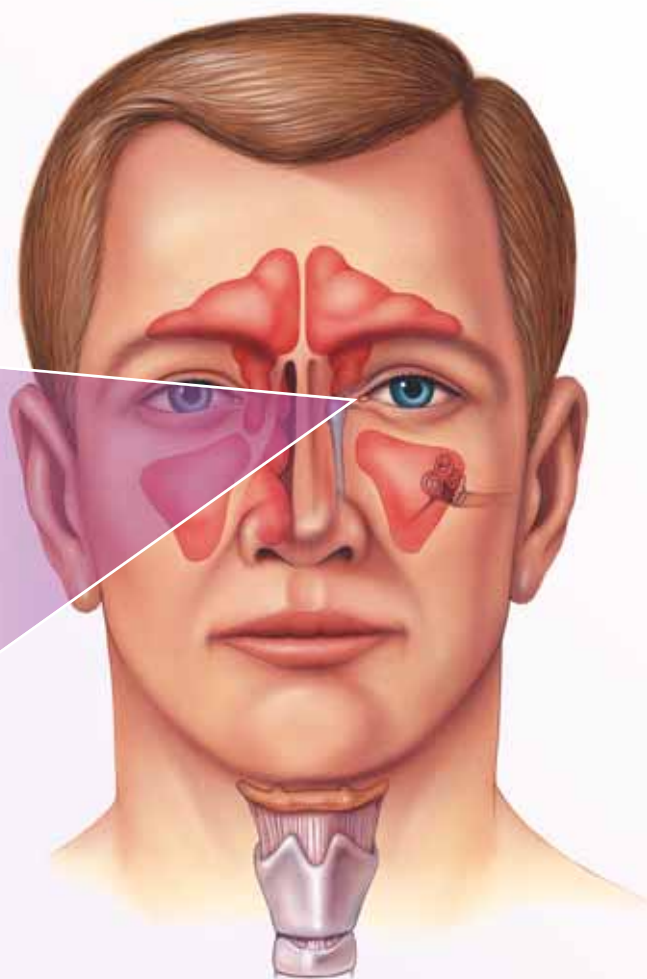
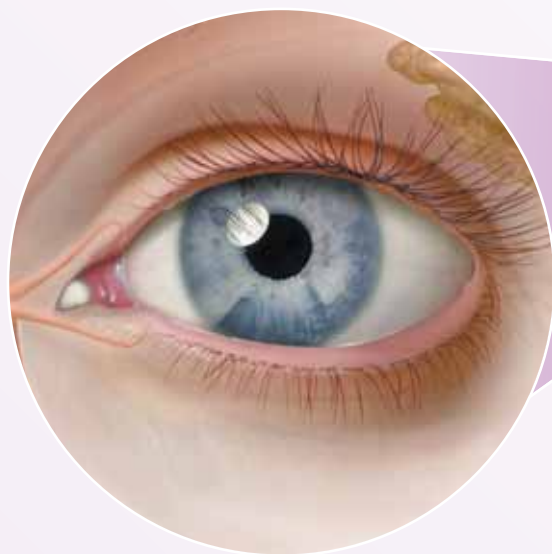# Gastric Juice



ᐱᑦᐱᑦᐱᑦᐱᑦᐱᑦᐱᑦ  
ᐱᑦᐱᑦᐱᑦᐱᑦᐱᑦᐱᑦᐱᑦ

Aqiarurmiup  
Aqilisautinga  
Hiirlan'nguniq  
Suc, muqueuse  
gastriques

## Gum at the Corner of the Eye



ل٢٦٧

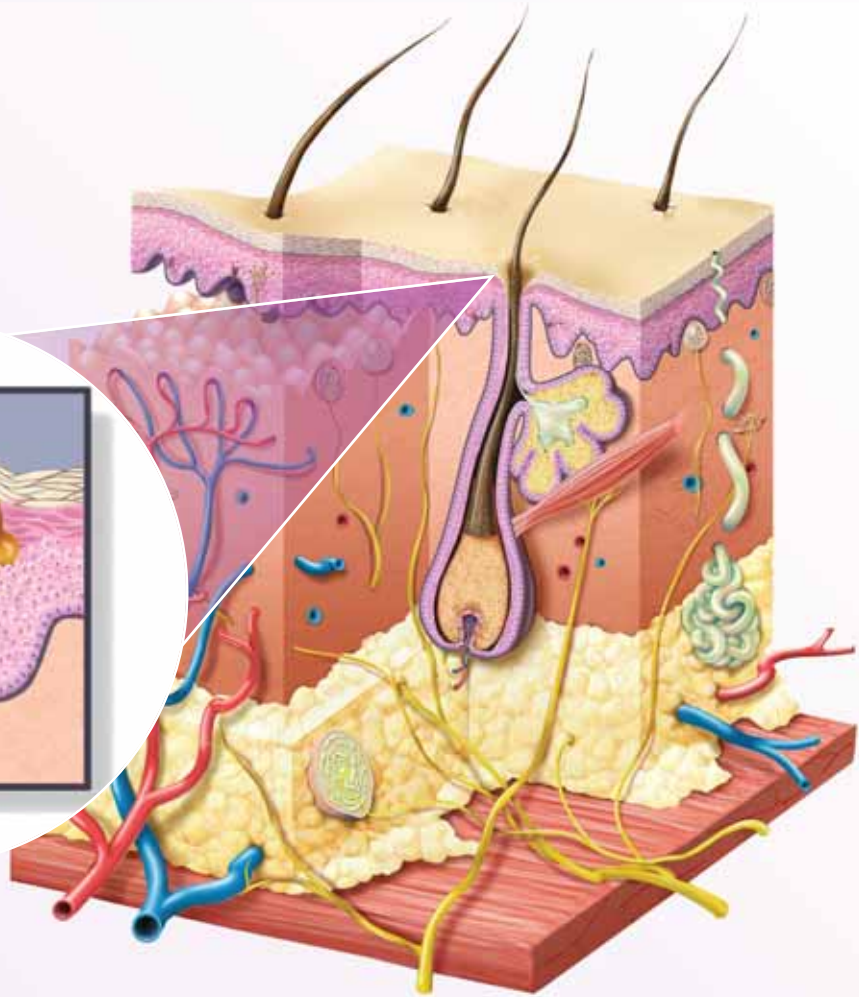
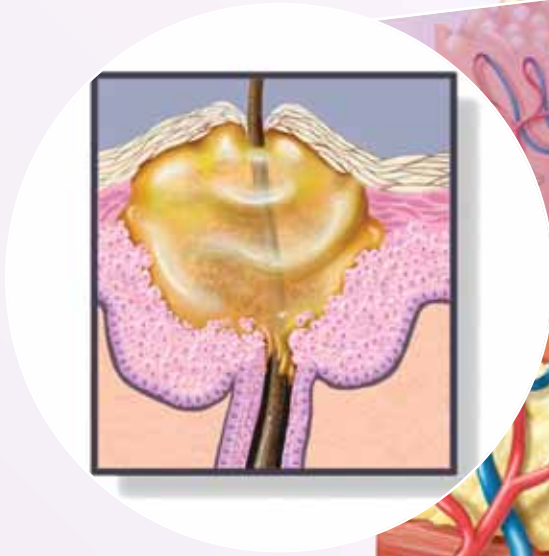Siqpi

liluk

Sécrétion dans  
le coin de l'œil



# Pus



ΔΛ<sup>ε</sup>σ<sup>ς</sup>β

Immangniq

Qaquviraq

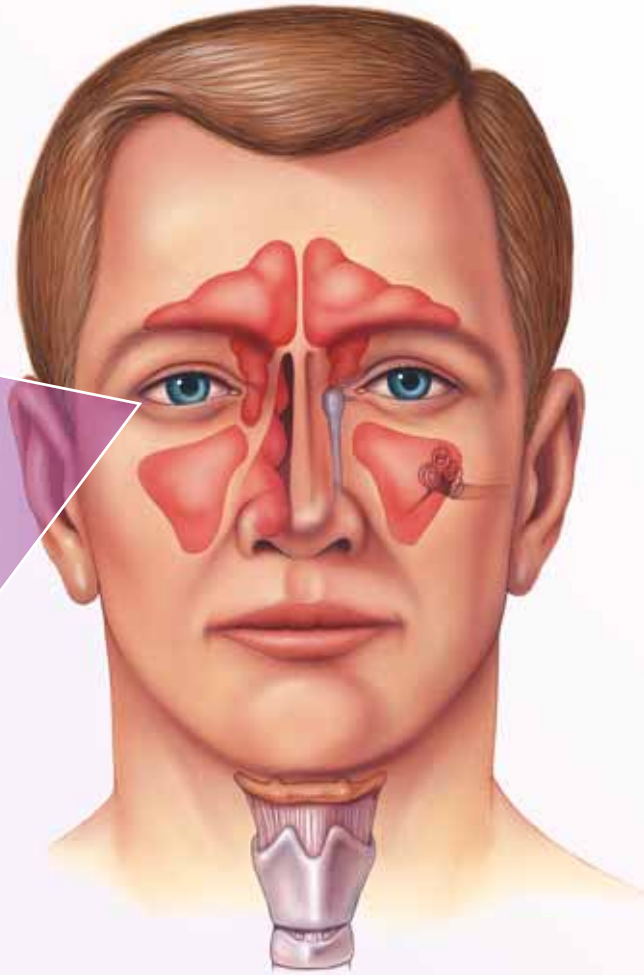
Pus







# Tear



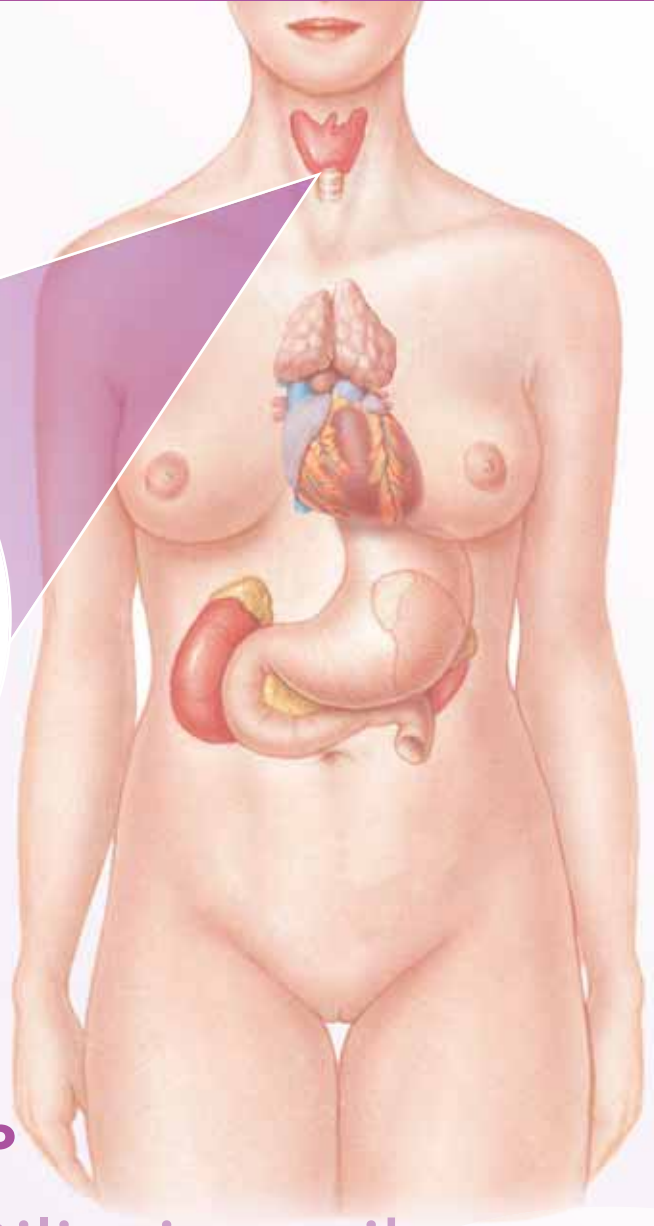
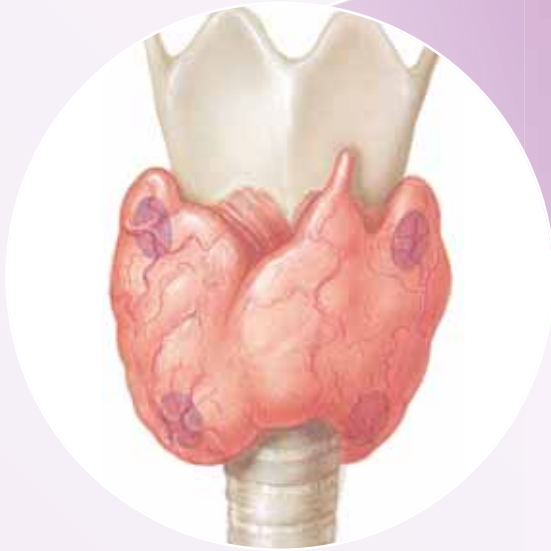
ᑭᑭᑭᑭᑭᑭ

Quvviq

Qulvik

Larme

# Thyroid and Parathyroid Glands



ᑕᑦᑲᑦᑲᑦᑲᑦ  
ᑦᑲᑦᑲᑦᑲᑦᑲᑦ

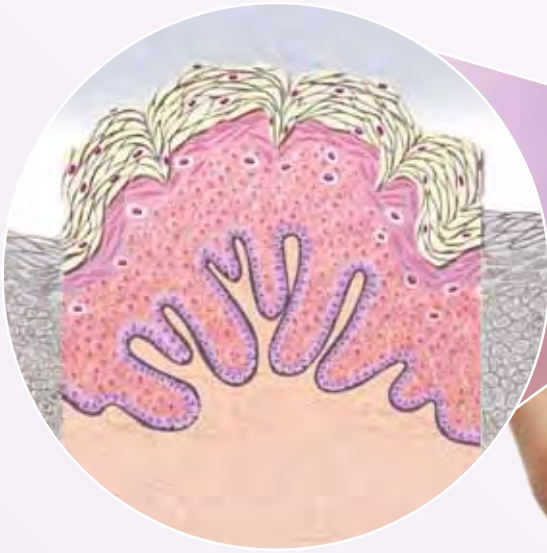
Tuqqujaap Qiliqsinangik

Tupquyaaq Qiniqhiit

Glands tyroïdes et  
parathyroïdes



# Wart



▷ ႁႁႃႇ

Unnguq  
Un'nguq  
Verrue



# Head/Face/Teeth/ Tongue

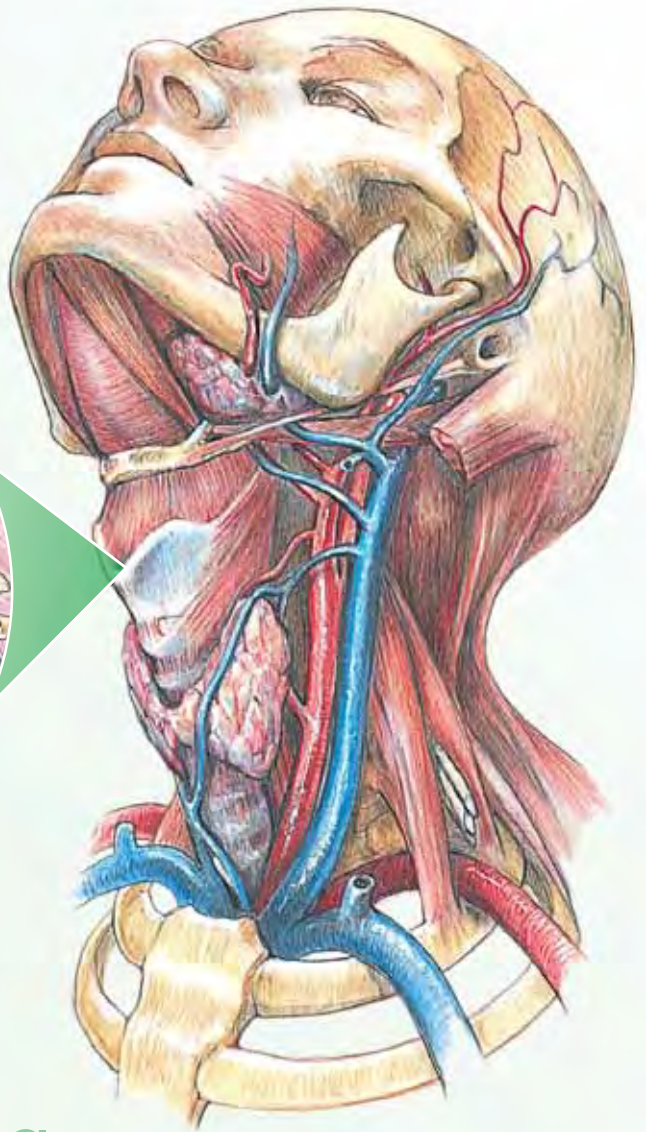
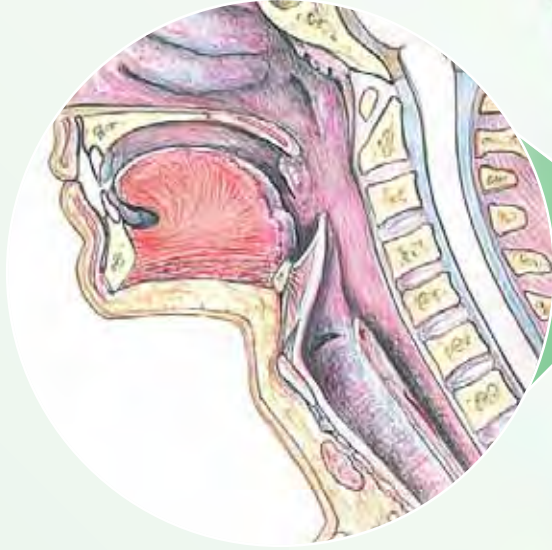σᐱᐅᐅᐅᐅ / ᐅᐅᐅᐅᐅᐅ / ᐅᐅᐅᐅᐅᐅ / ᐅᐅᐅᐅᐅᐅ

Niaquq/Kiinaq/Kigutit/Uqaq

Niaquq/Akuliak/Kigutit/Uqaq

Tête / Face / Dents / Langue

# Adam's Apple



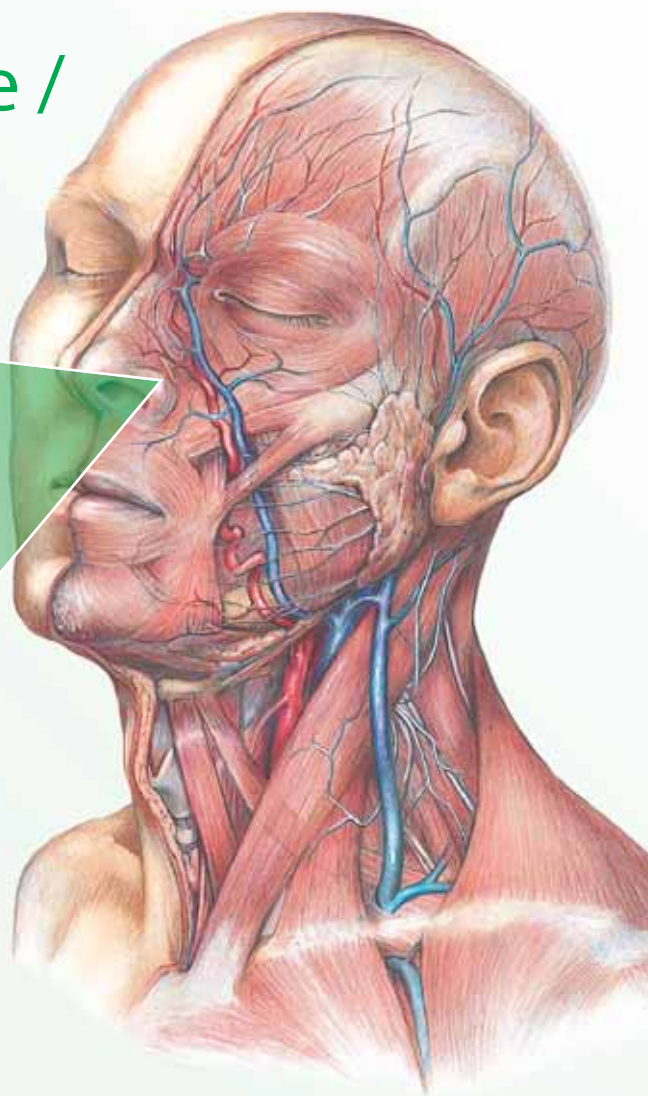
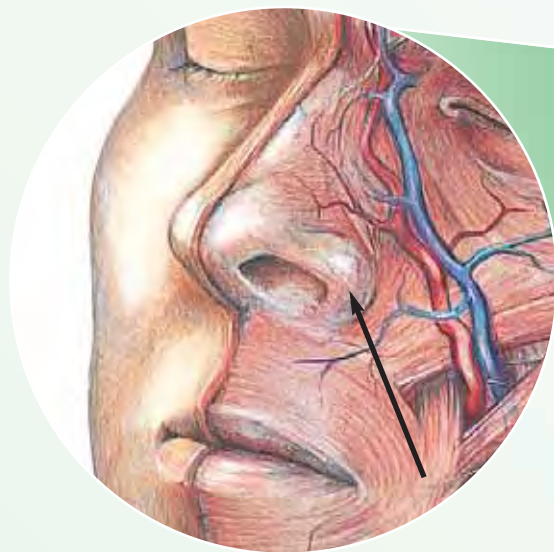
ᐱᑦᑭᑦᑭᑦᑭᑦᑭᑦᑭᑦ

Qingannuaq

Iggialhuq/Iggiaqquq

Pomme d'Adam

# Ala of the Nose / Nose Wing



ᑕᑦᑲᑦᑕᑦᑲ

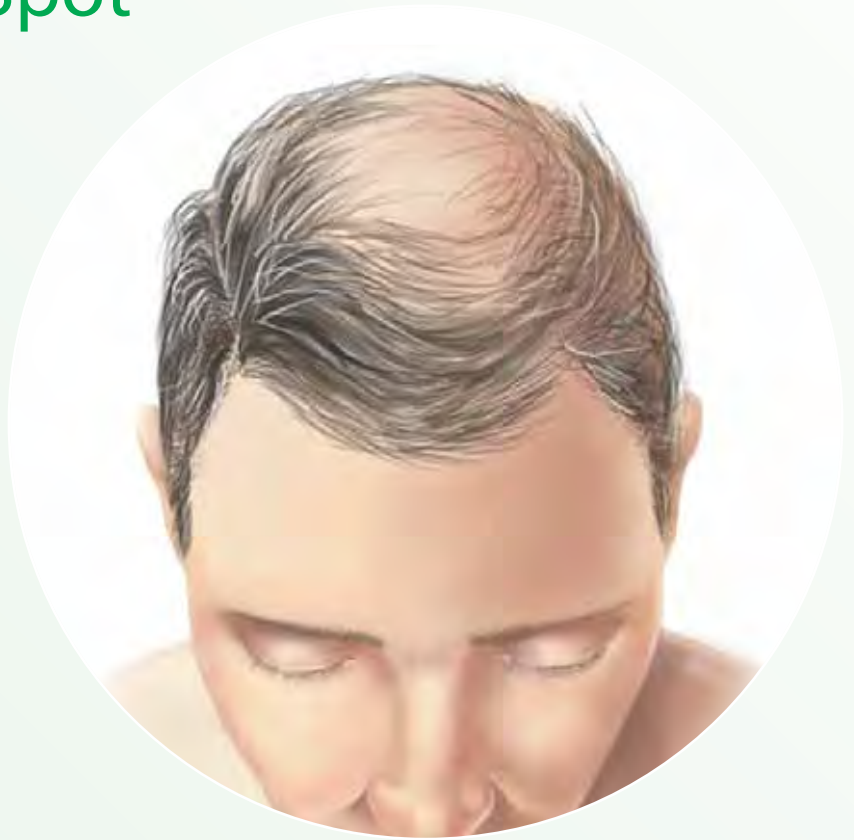
Taqpaq

Natatquaq

Aile du nez



# Bald Spot



ᐱᐱᐱᐱᐱᐱᐱᐱᐱᐱ

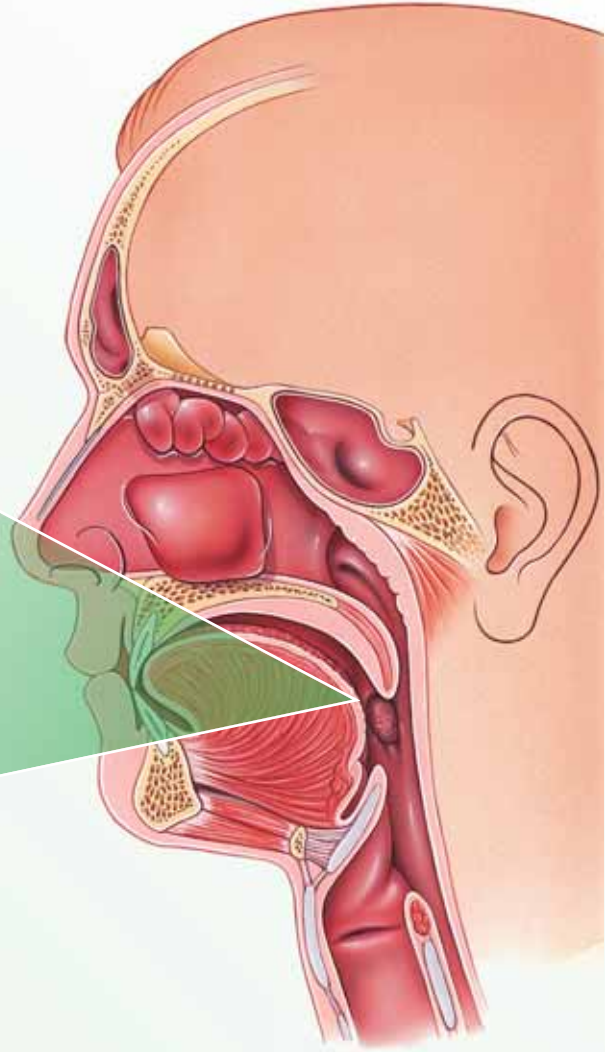
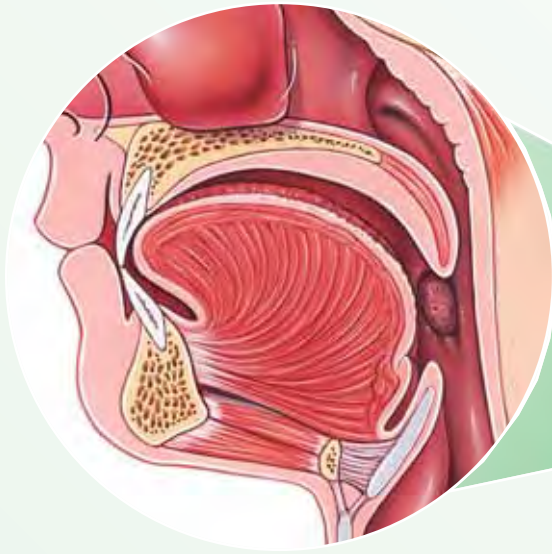Miqquiqtuq

Mitquirniq

Chauve, sans poil (être)



# Base of the Tongue



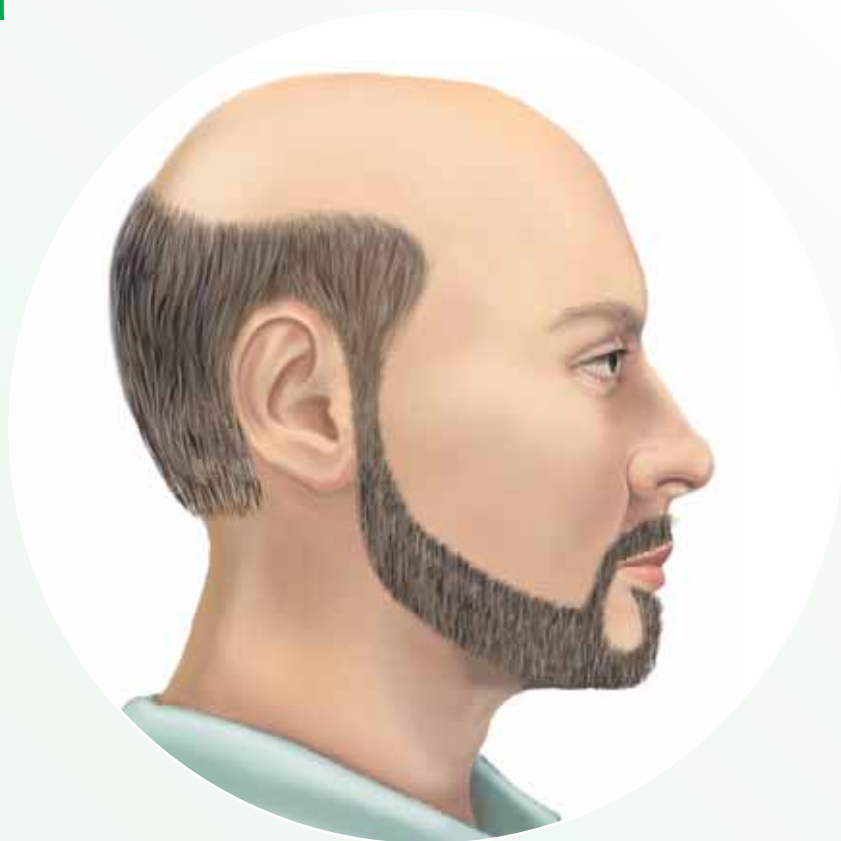
ᐃᑦᑲᐃᑦ ᑲᑦᑦᑦ

Uqaup Kangia

Uqaup Nuqirutaa

Base de la langue

# Beard



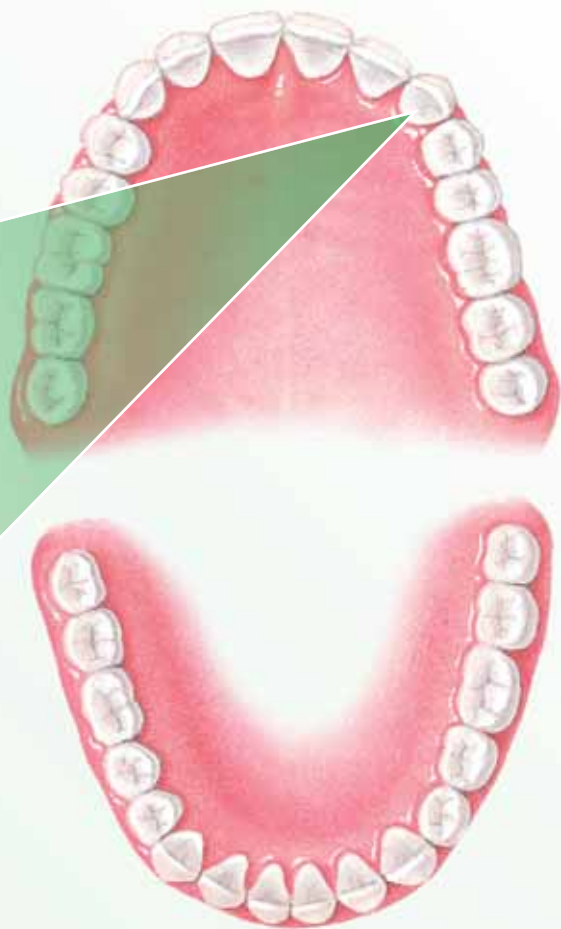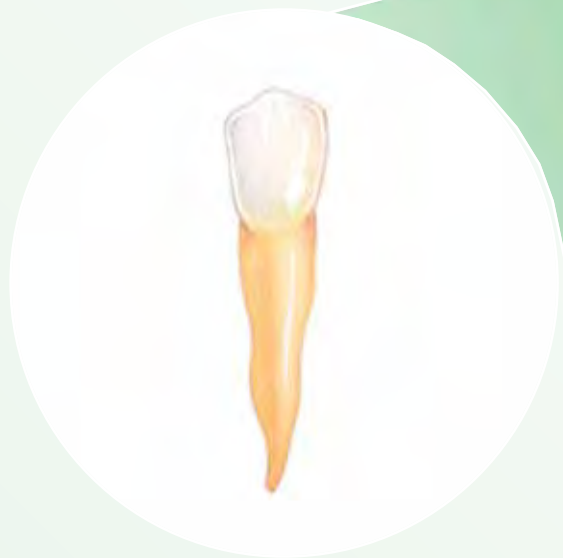▷Гб

Umik

Umik

Barbe

# Canine



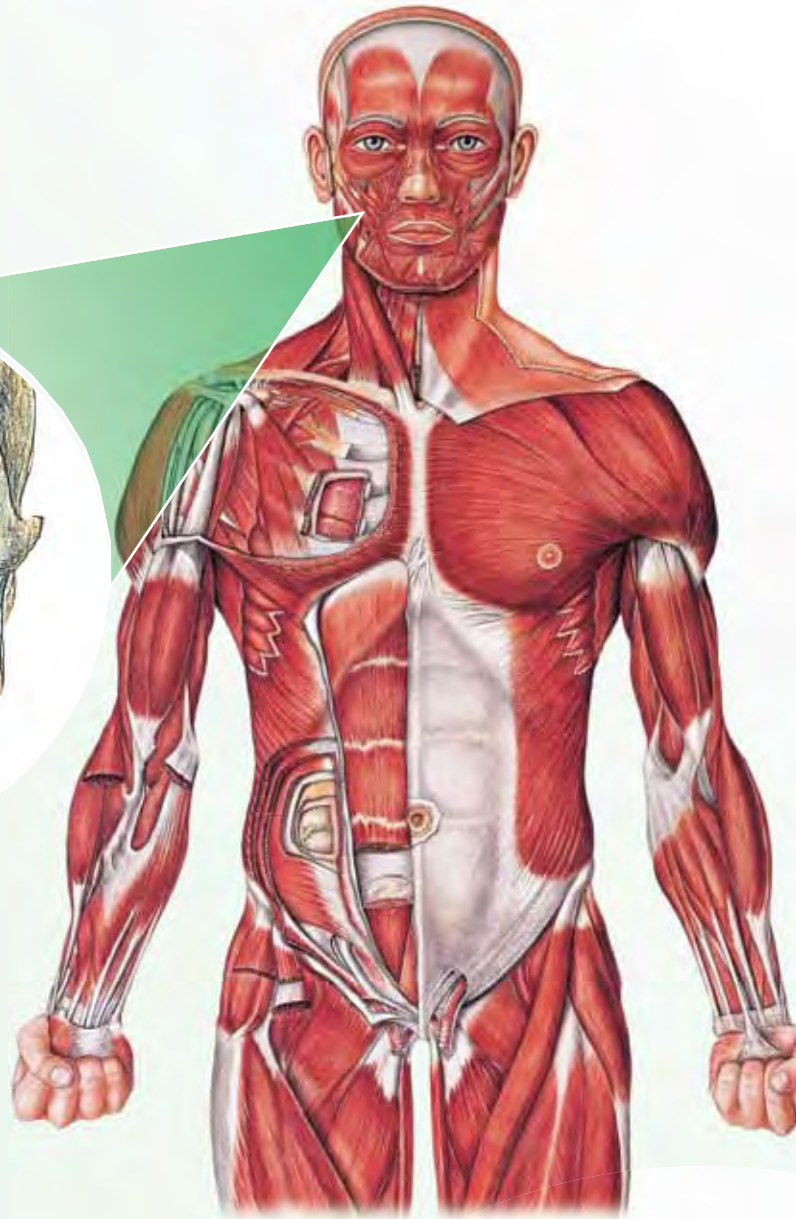
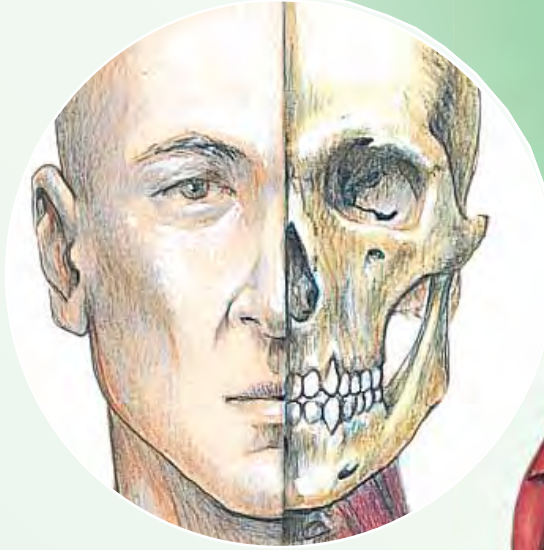
تولوریاق

Tuluriaq

Tuluriaq

Canine

# Cheek



Uluak

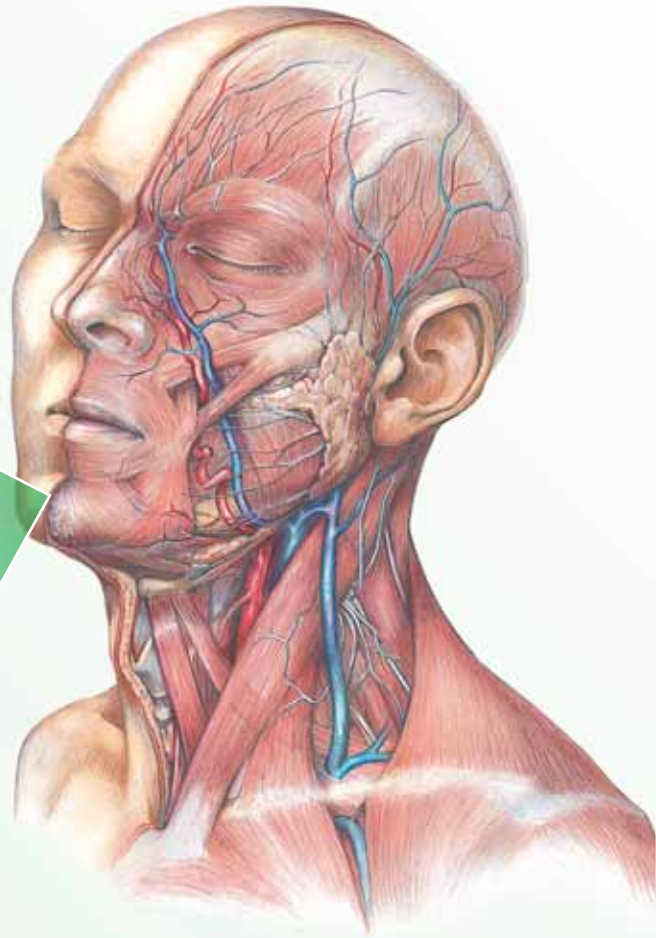
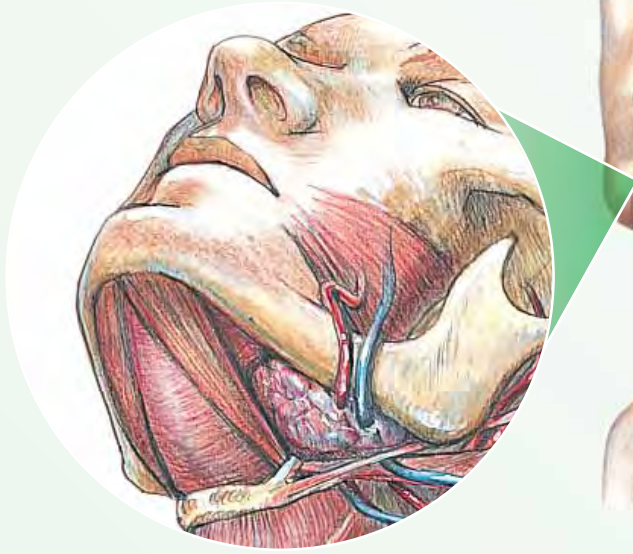Uluak

Uluak

Joue



# Chin



چن

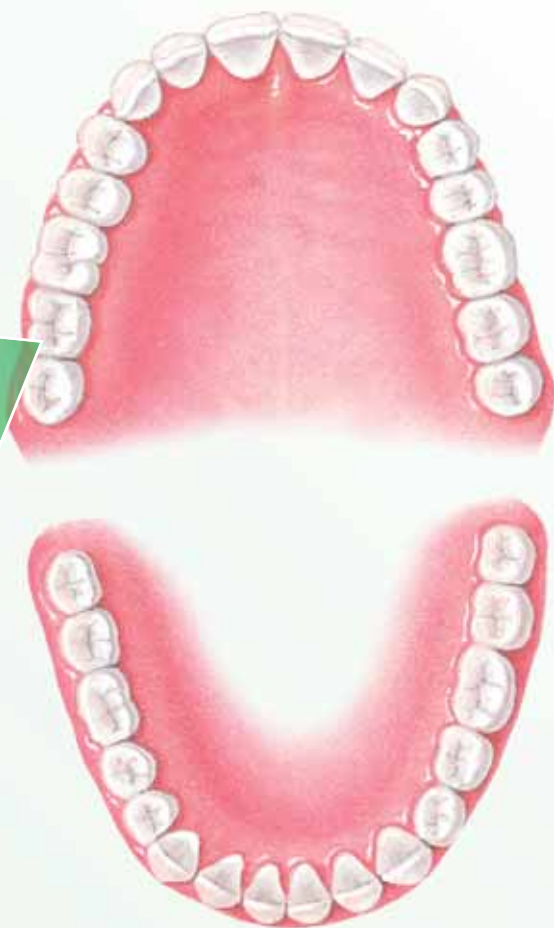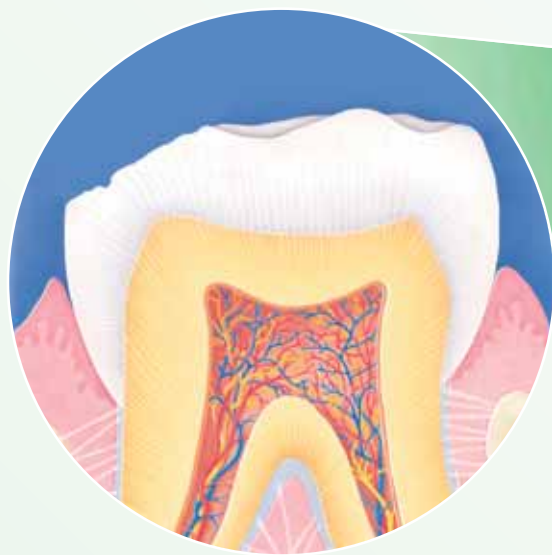Tallu

Tablu

Menton



# Chipped Tooth



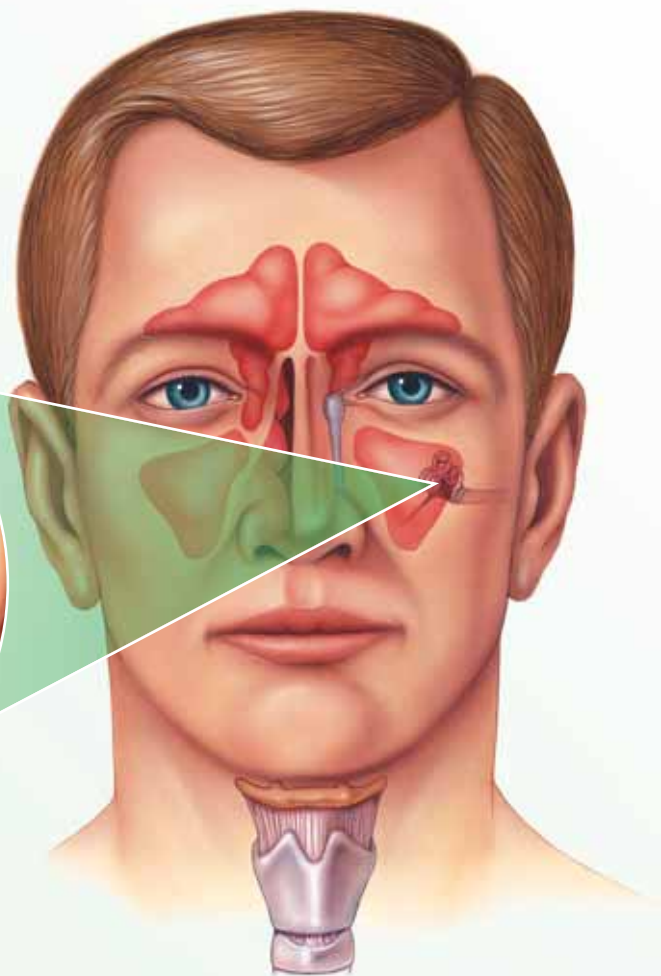
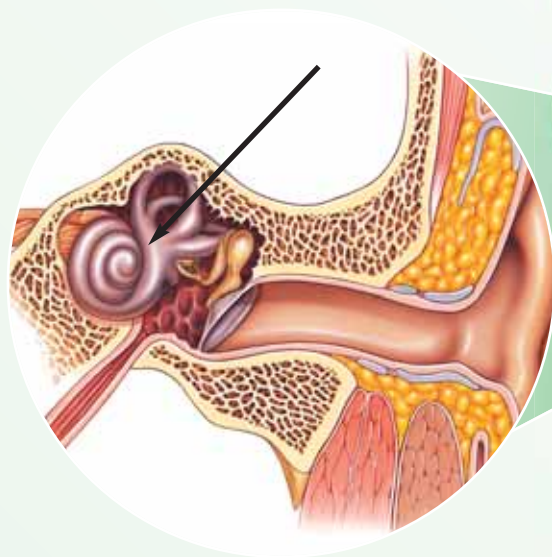
ᐃᑦᑦᑦᑦᑦᑦᑦᑦ

Uliqsimajuq

Kigutip Ahiqua

Dent ébréchée

# Cochlea



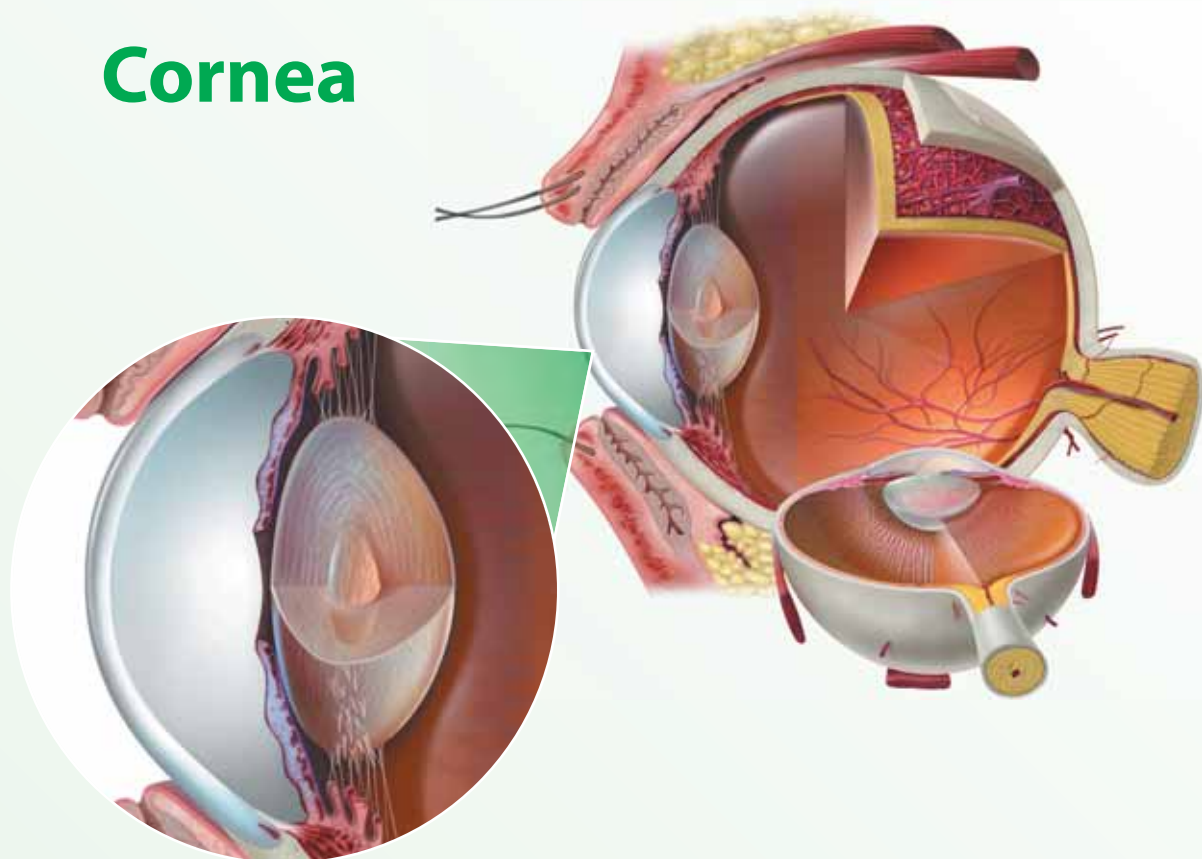
ᐱᐅᐅᐅᐅᐅ

Siunnaq

Hiutip Kapihianga

Cochlée ou limaçon

# Cornea



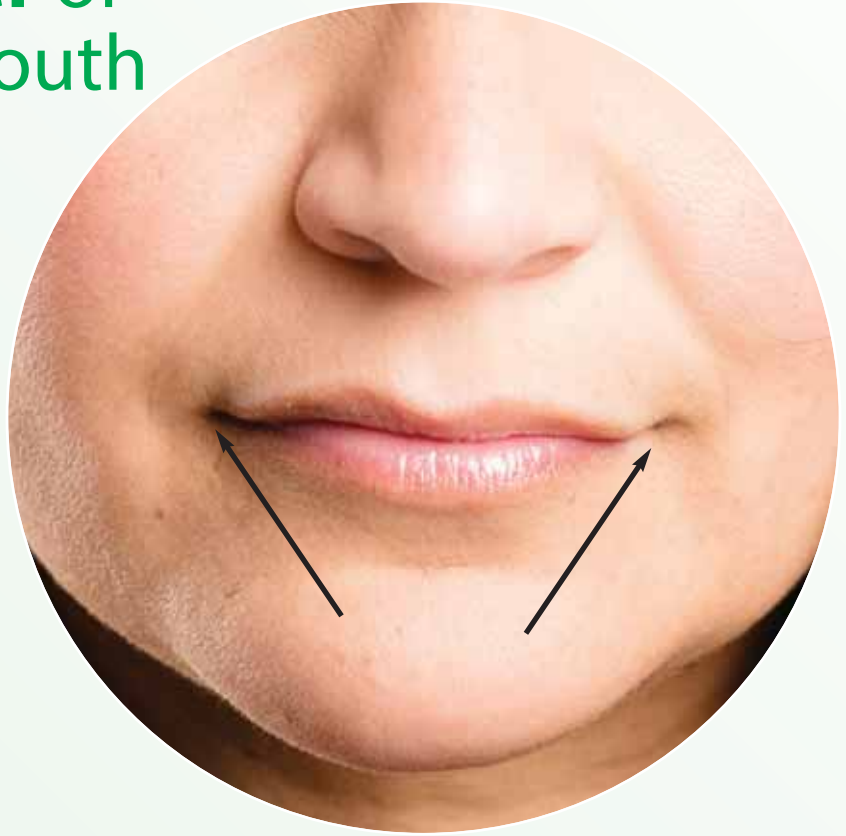ᐃᑭᐃᑦ ᐃᑭᑦᑕᐃᑦᑕᑦ

Ijiup Igalaujanga

Iyip Kapihianga

Cornée

## Corner of the Mouth



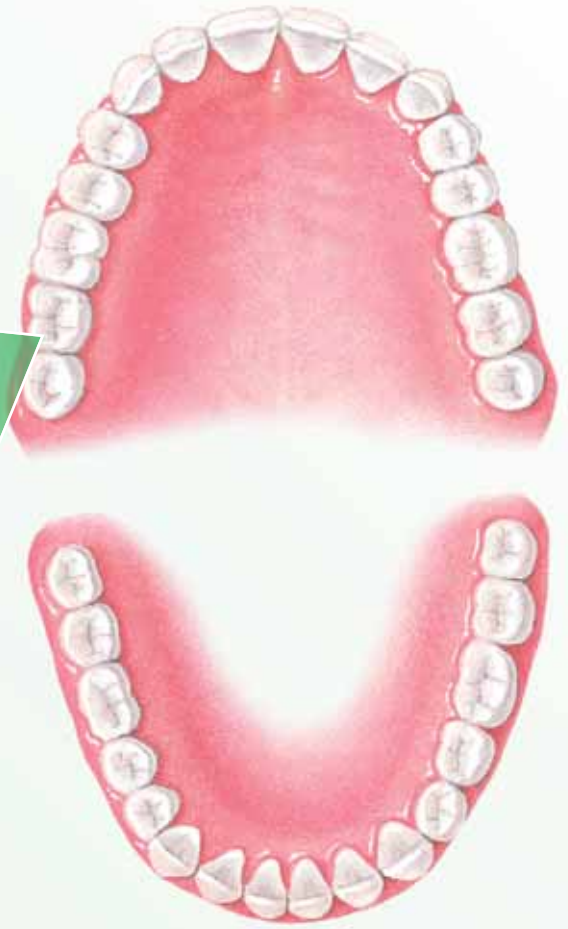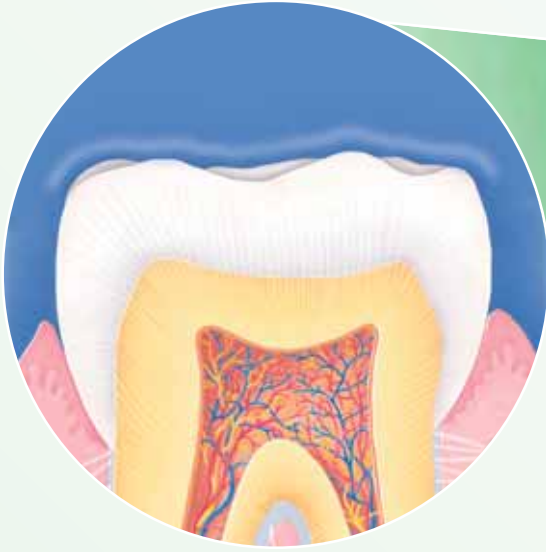
Δ<sup>ϕ</sup>ρ

lqi

lqik

Commissure des lèvres

# Crown of the Tooth



ᐱᑭᑦᑲᑦᑲᑦ ᑦᑲᑦᑲ

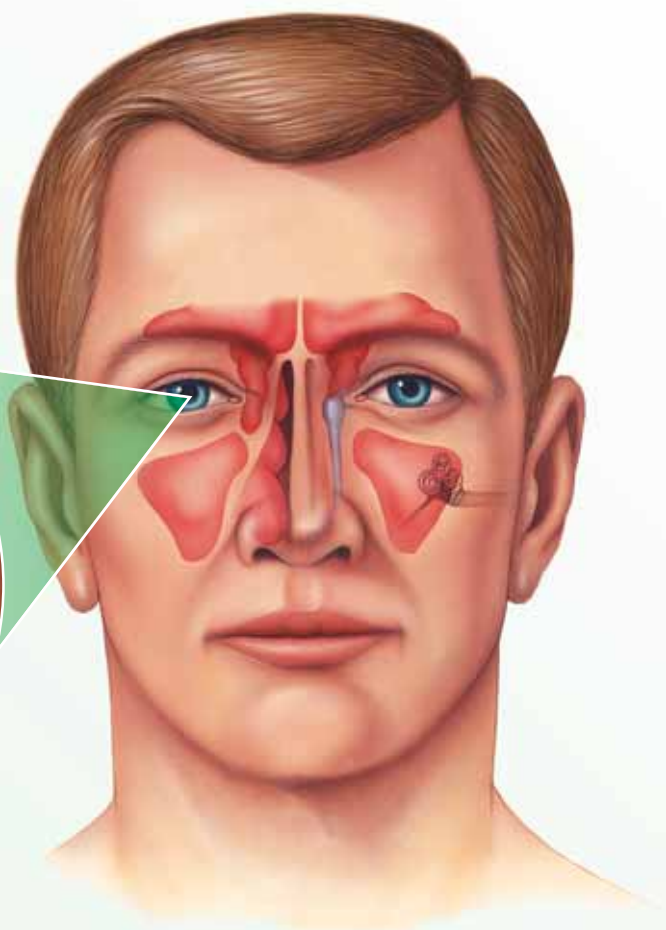
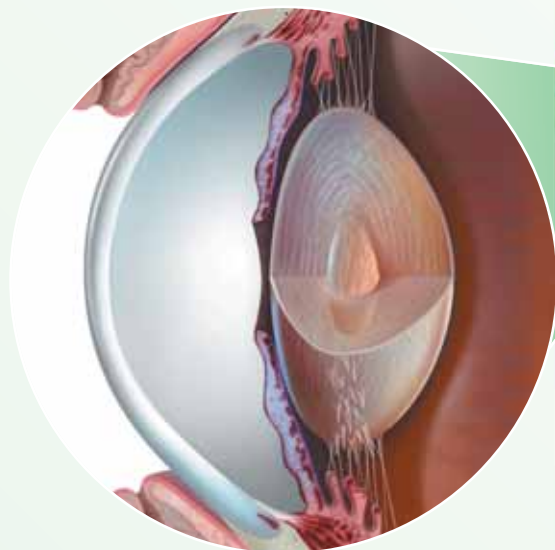
Kigutiup Qaanga

Kigutip Qaanga

Couronne de la dent



# Crystalline Lens / Pupil



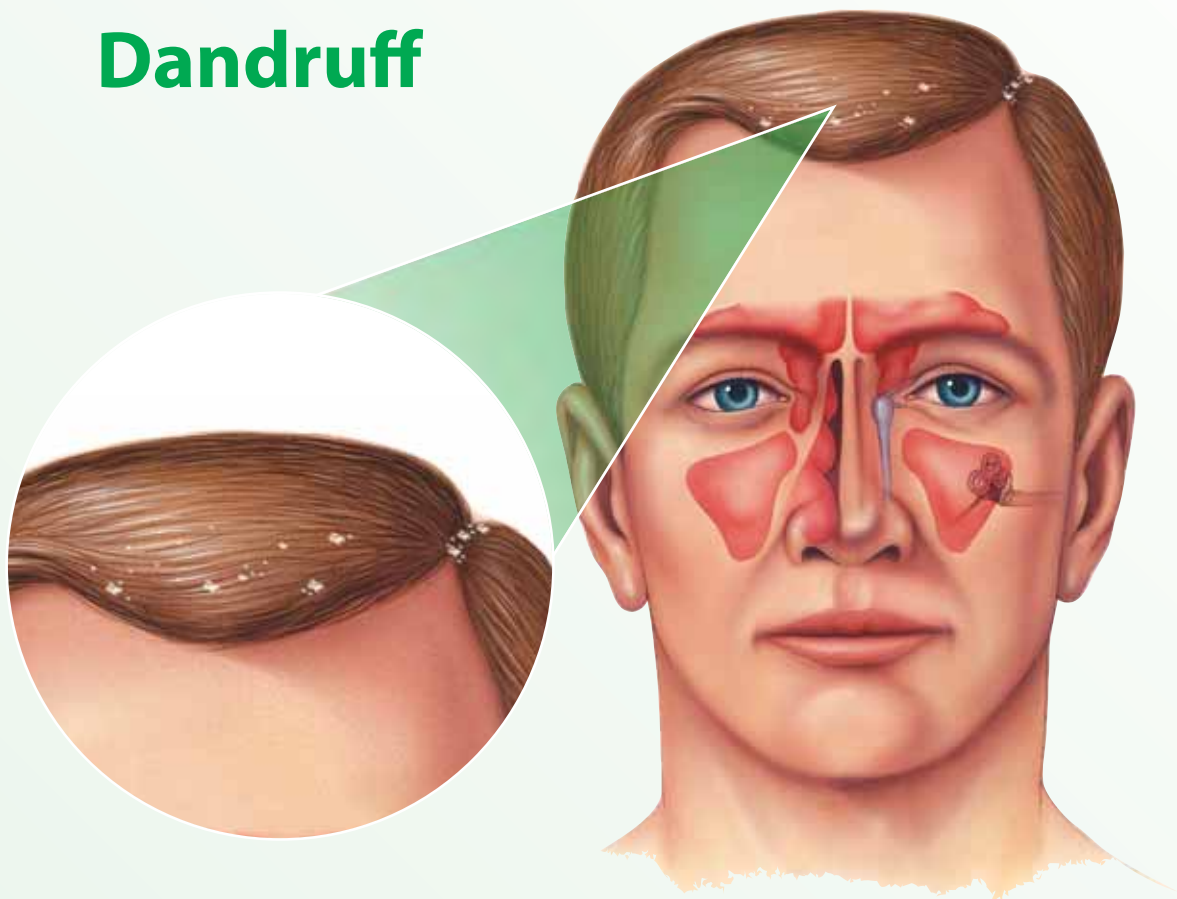
Δ↳P◁ᵇ

Ijaruvak

Takkuvik

Cristallin (pupille)

# Dandruff



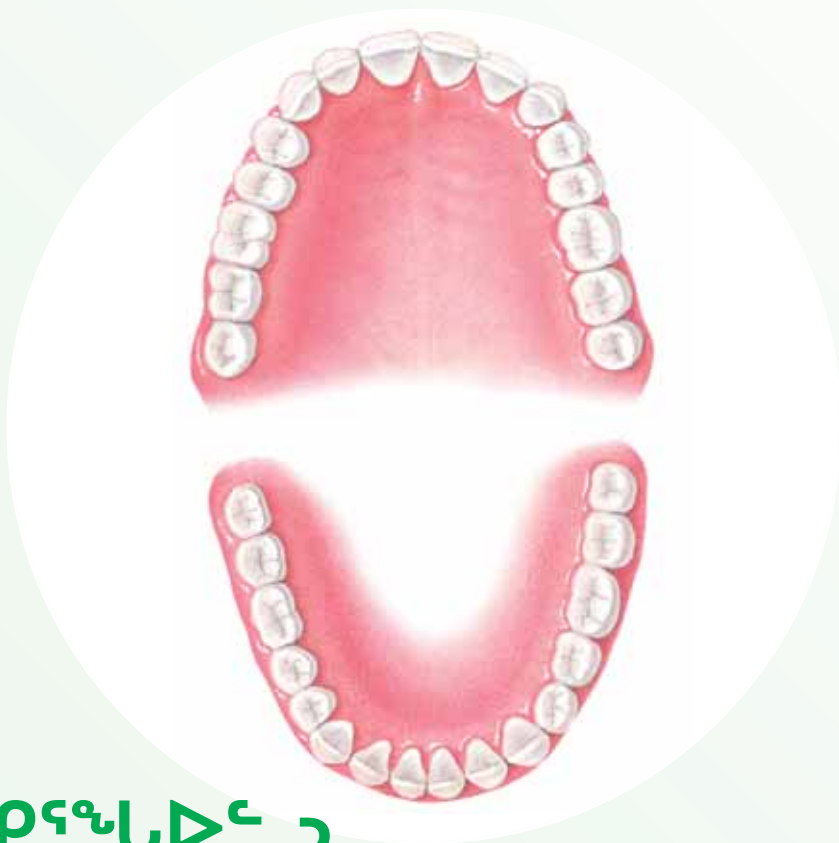ЛІ ґб

Mamaaq

Qaglik

Pellicules

# Dental Arches



ՄԱԳԻՆՊԳՆՆԱԾՆ

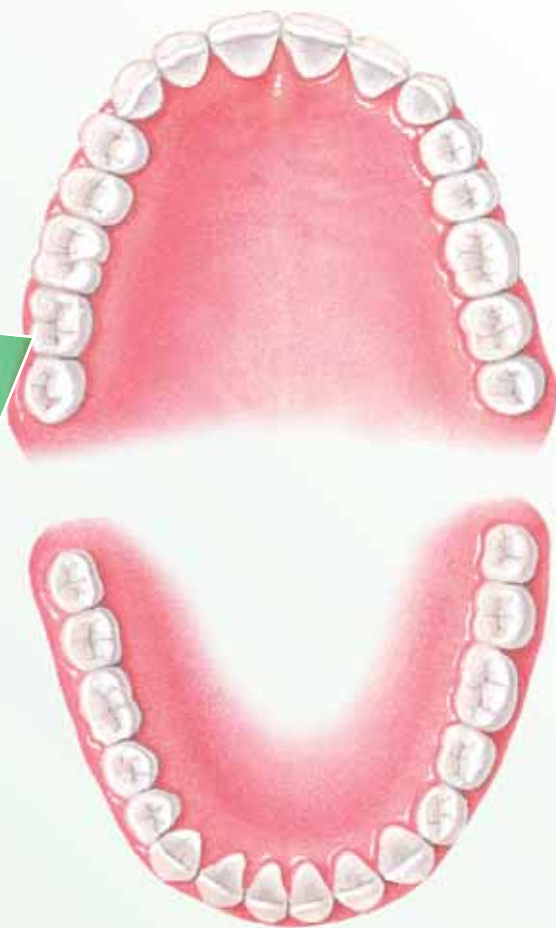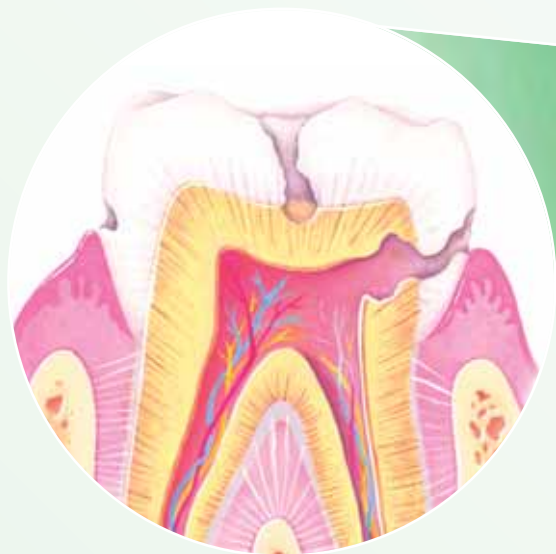
ՎԵՆՉՆՆԱԾ ՎՃԳԵՐՏՆՆ

Niaqqirngaullu Agliruullu  
Apuqtarninga

Kigutiqarvik

Arcades dentaires

# Dental Carie



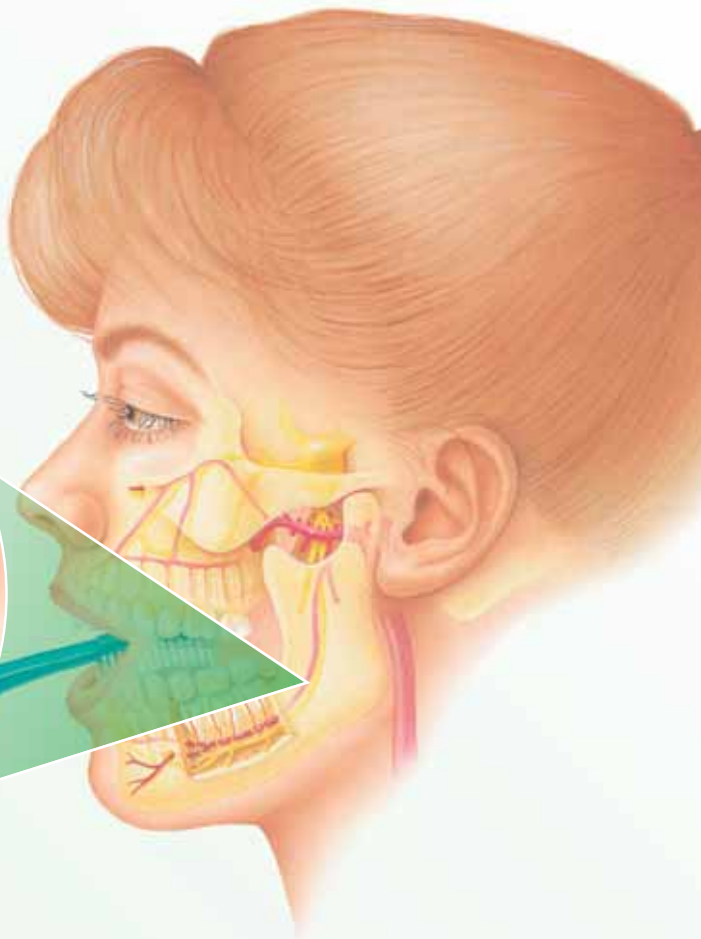
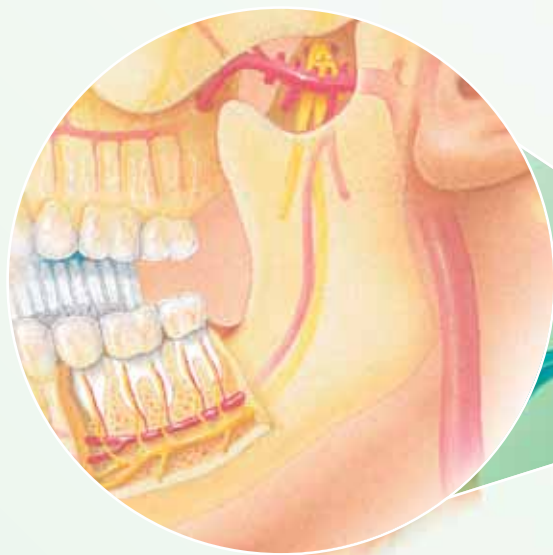ԲՅՈՒՆՆԵՐ ԳՆՏՆԵՐ

Kigutiup Auninga

Kigut Auhimayuq

Dent cariée

# Dental or Alveolar Nerve



ΡΥΝΟ ΔΕΛΦΟΣ ΔΕΛΦΟΝΟΡΟ

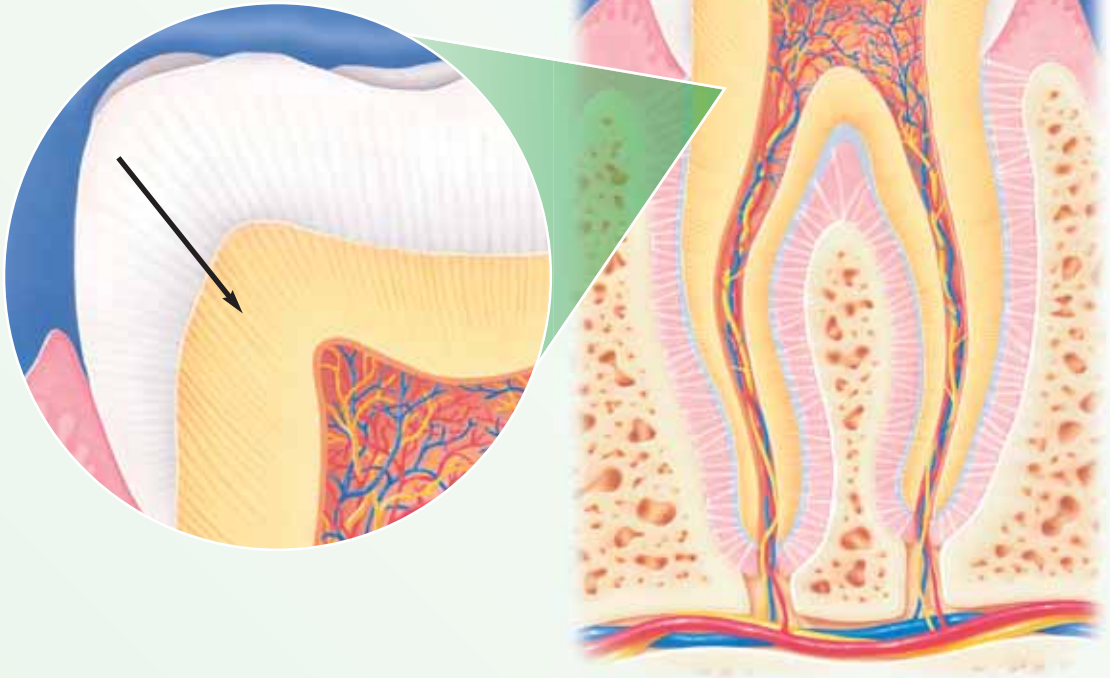
Kigutit Ikpingniajjutingit

Kigutip Attataa

Nerf dentaire ou alvéolaire



# Dentin, Ivory



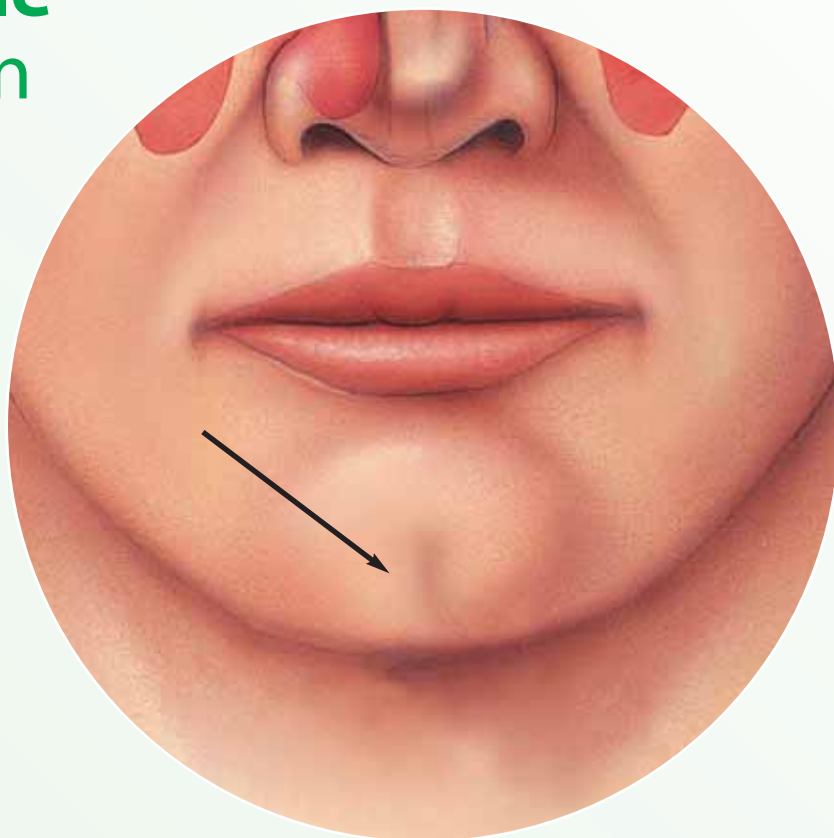
ᑭᑭᑭᑭᑭᑭ ᑭᑭᑭᑭᑭᑭ

Kigutiup Aqinninga

Kigutip Qaanga

Couronne de la dent

# Dimple of Chin



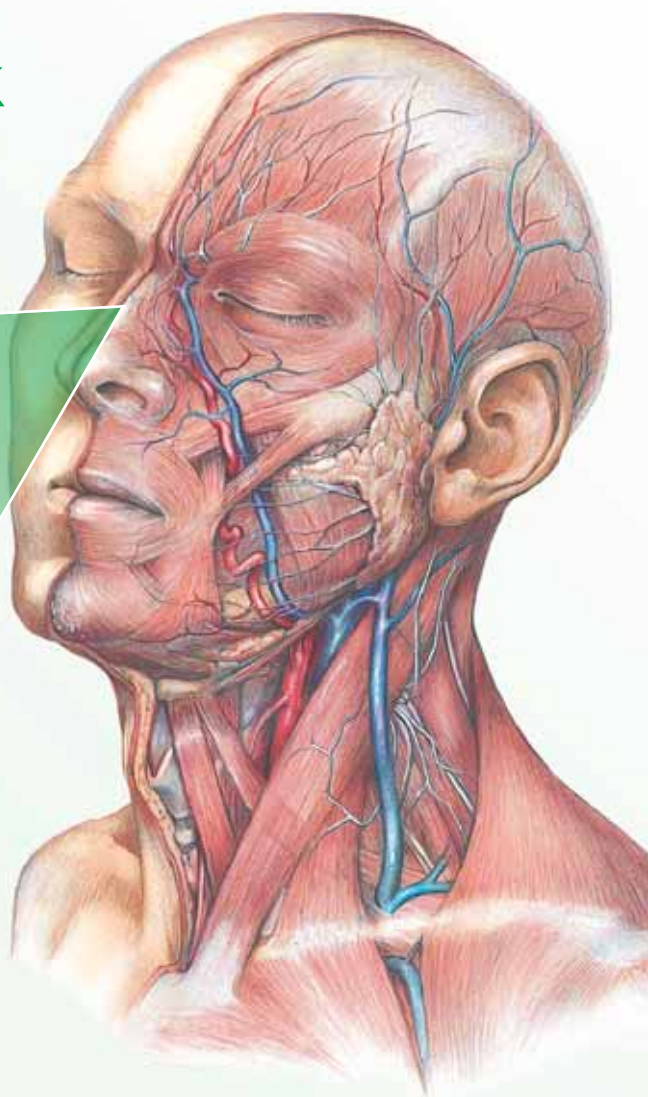
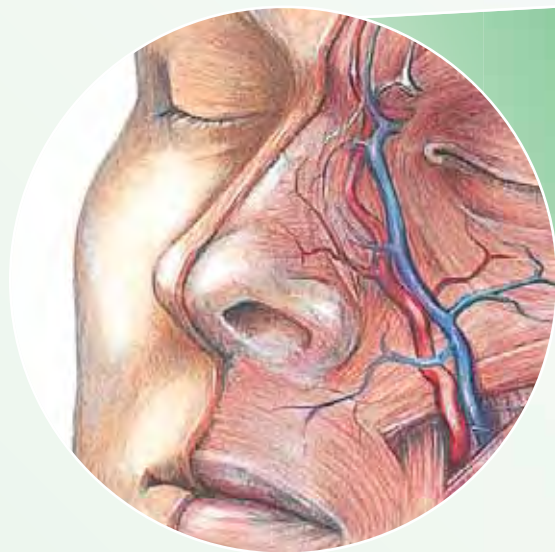ᑕᑦᑭᑦ ᐃᑭᑦᑲᑦᑲᑦ

Talluup Iluqsanga

Tablurut

Fossette

## Dorsum / Back of the Nose



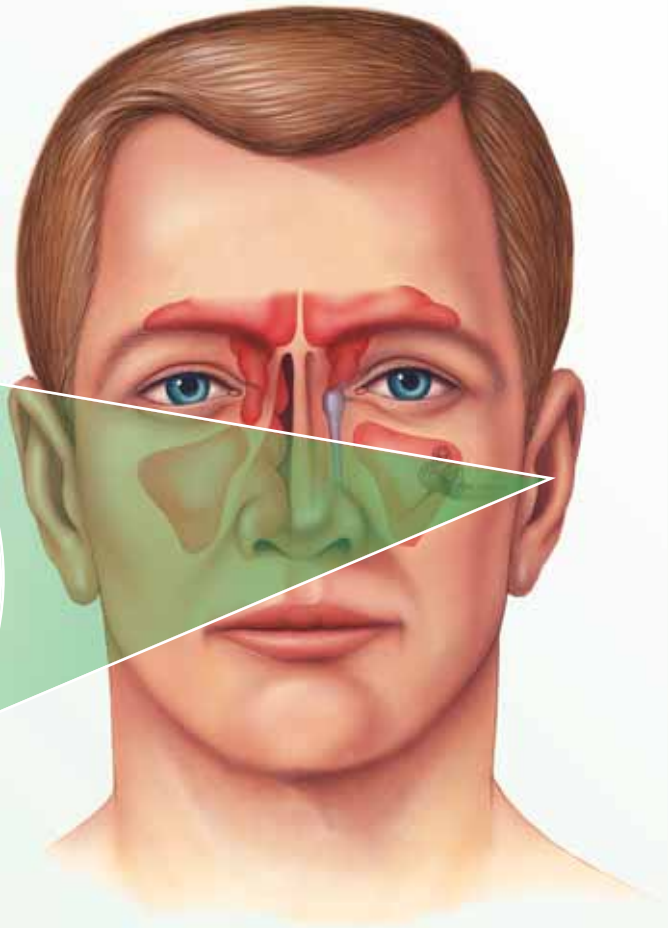
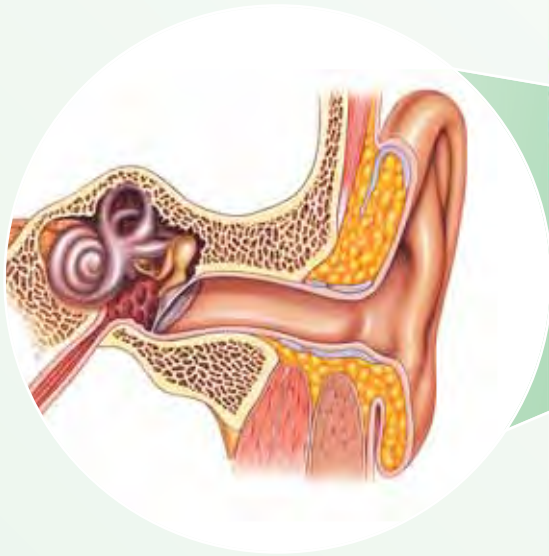ᐱᑭᑦᑎᑦᑎᑦ

Sivuraq

Qingaulhuk

Dos du nez

# Ear



𐌿𐌸𐌰

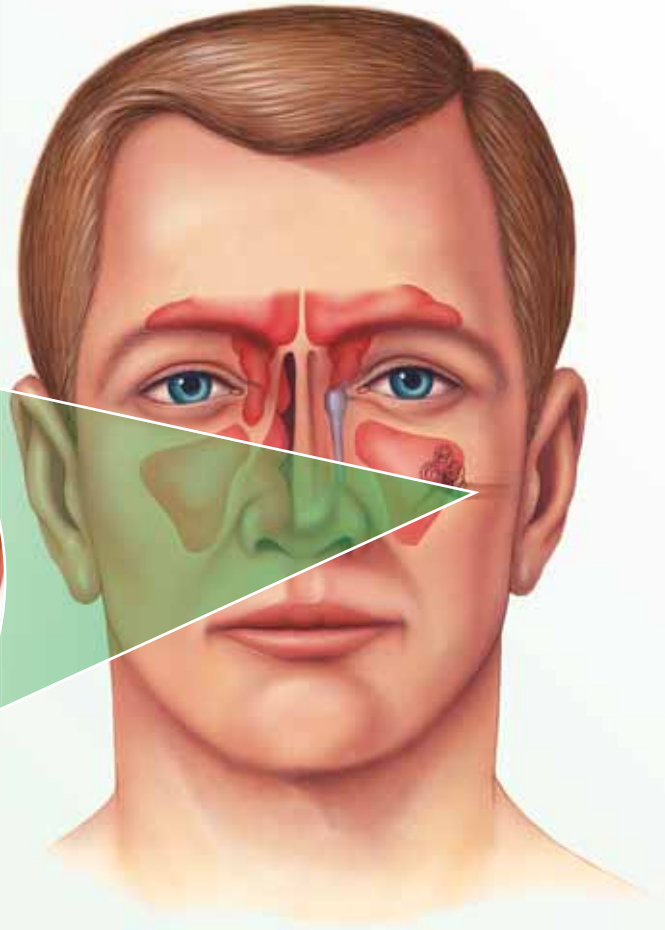
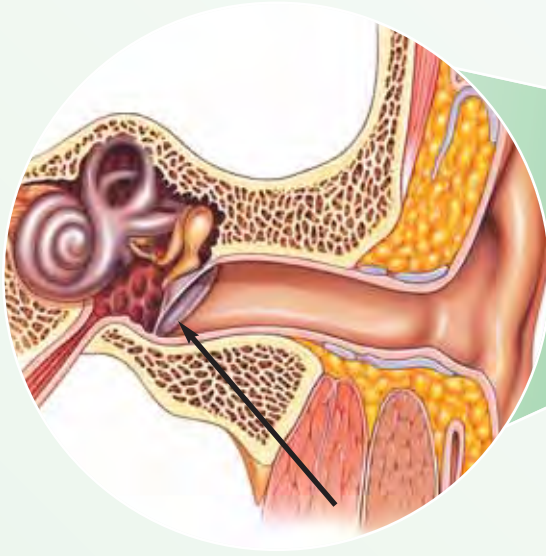Siuti

Hiut

Oreille



# Ear Drum



ΔΛϸ▷↳ϣᵇ

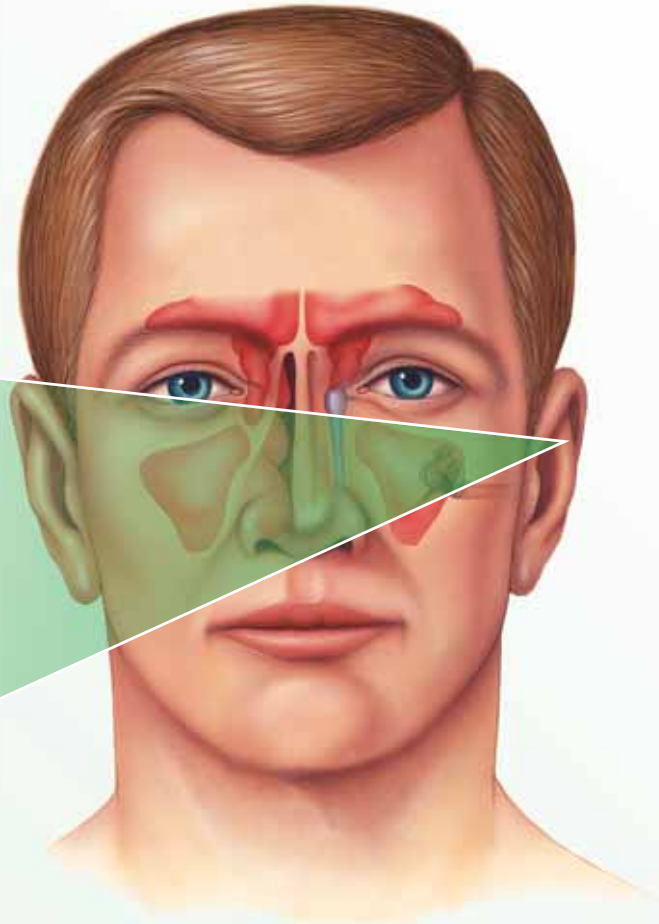
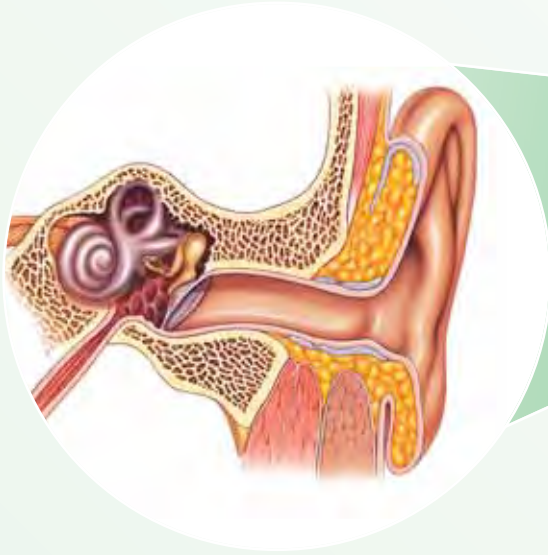Igalaujaq

Kapihiaq

Tympan



# Ear Pavilion



ᐱᐅᐅᐅᐅᐅ ᐅᐅᐅᐅᐅᐅ

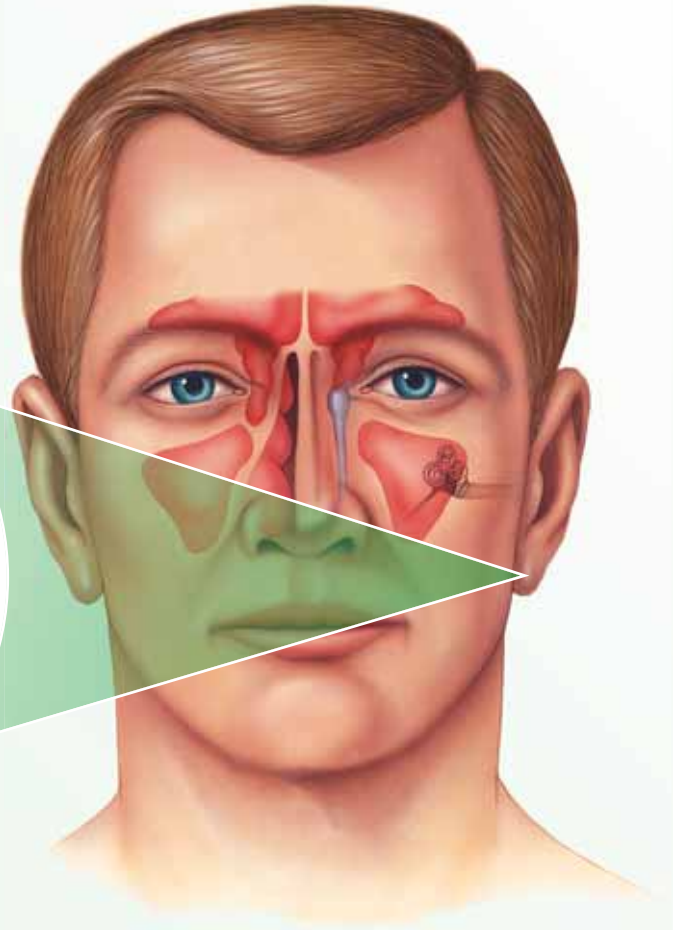
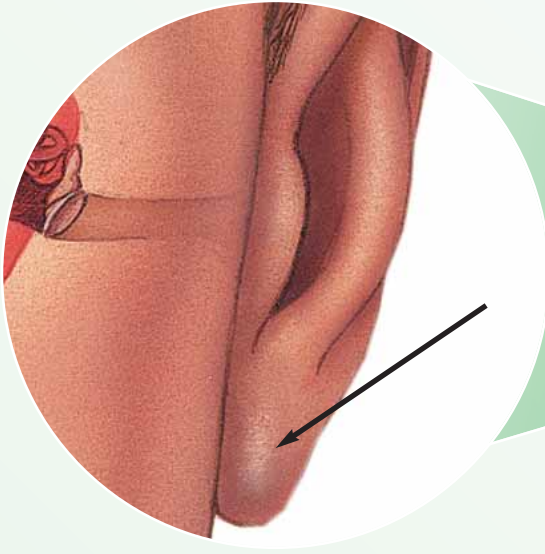
Siutiup Nataqqua

Hiutip Avataa/Hiutip

Qaqqulaanga

Pavillon de l'oreille

# Earlobe



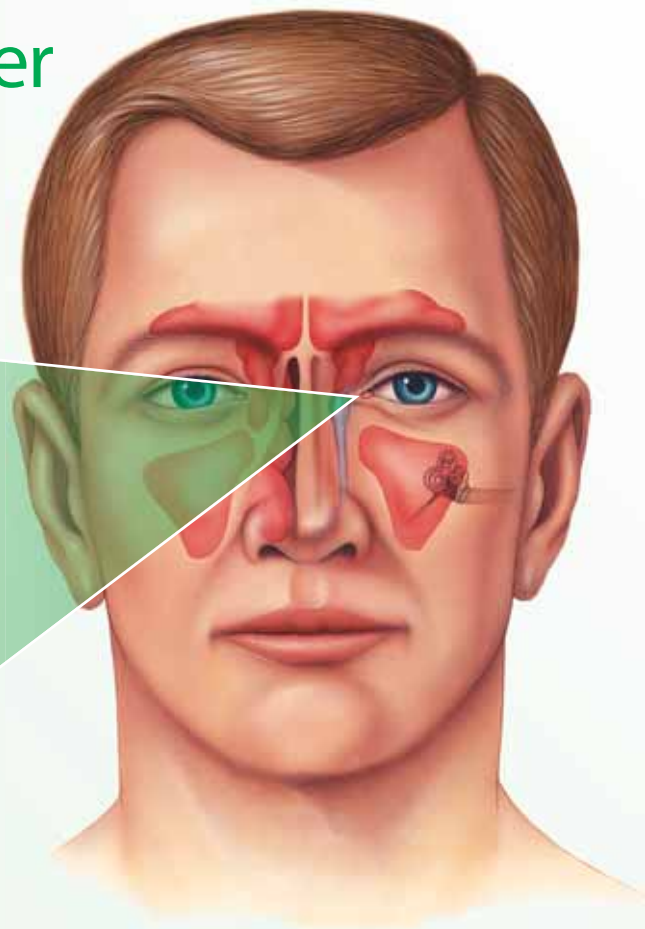
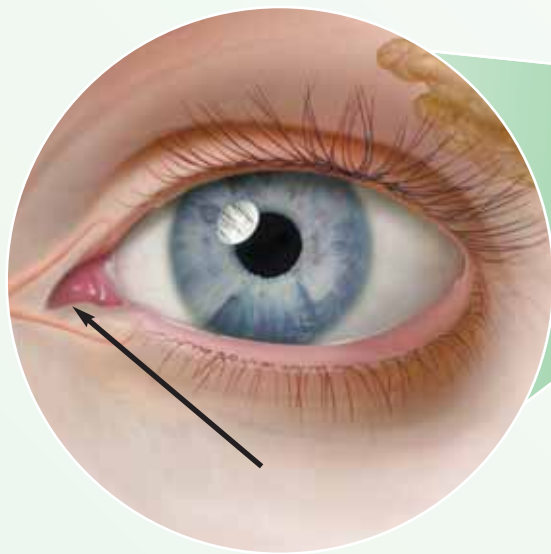
ᐱᑦᑕᑦ

Matsa

Hiutiruk

Lobe de l'oreille

# Internal Corner of the Eye



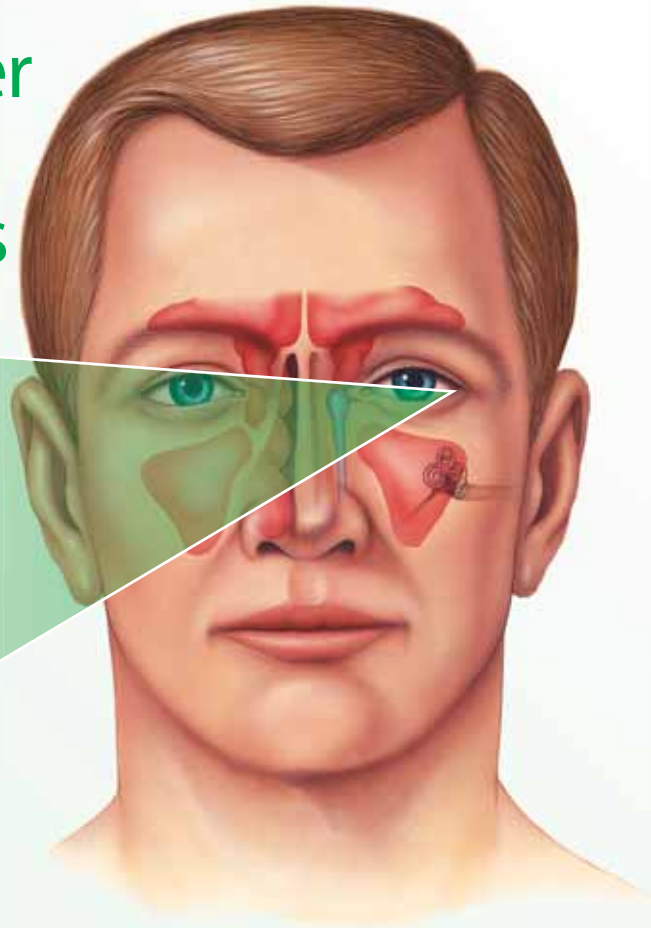
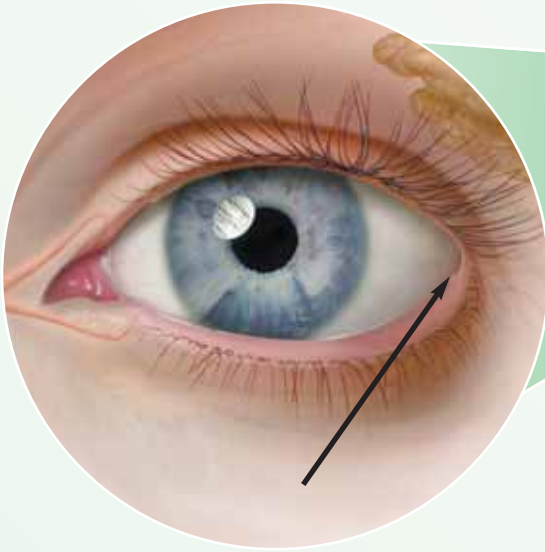
Δ<sup>c</sup>ⱭⱭ▷Ɑ

Illuriuti

Qipaluaq

Coin interne de l'œil

# External Corner of the Eye or Lateral Canthus



ᐅᐅᐅᐅᐅᐅ

Qipaluaq

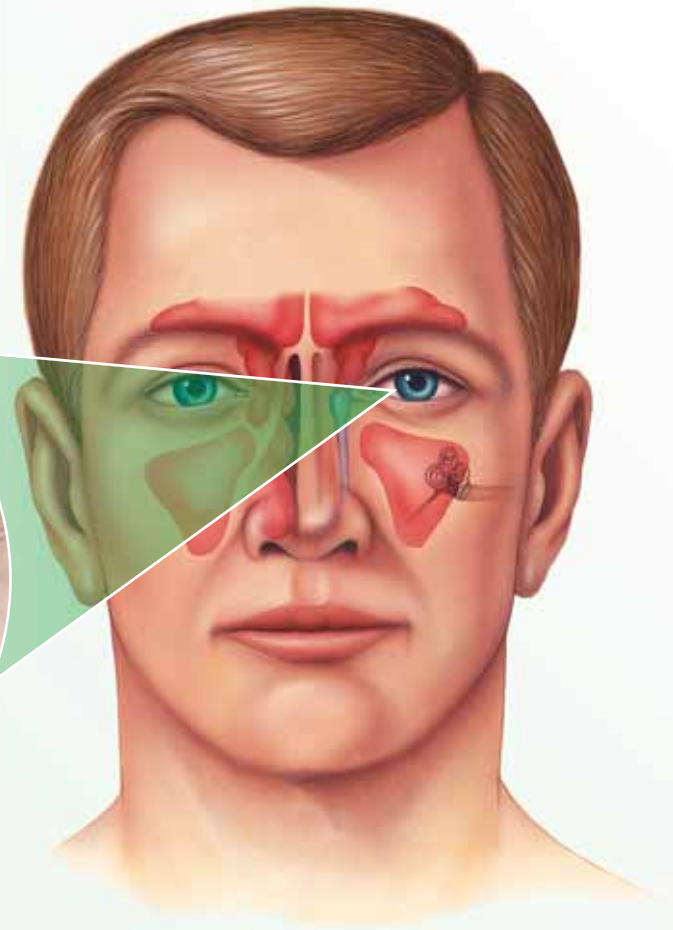
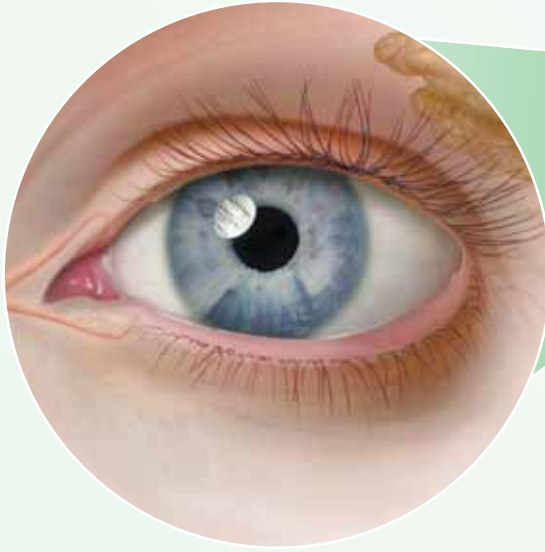
Qipaluaq

Coin externe de l'œil





# Eye



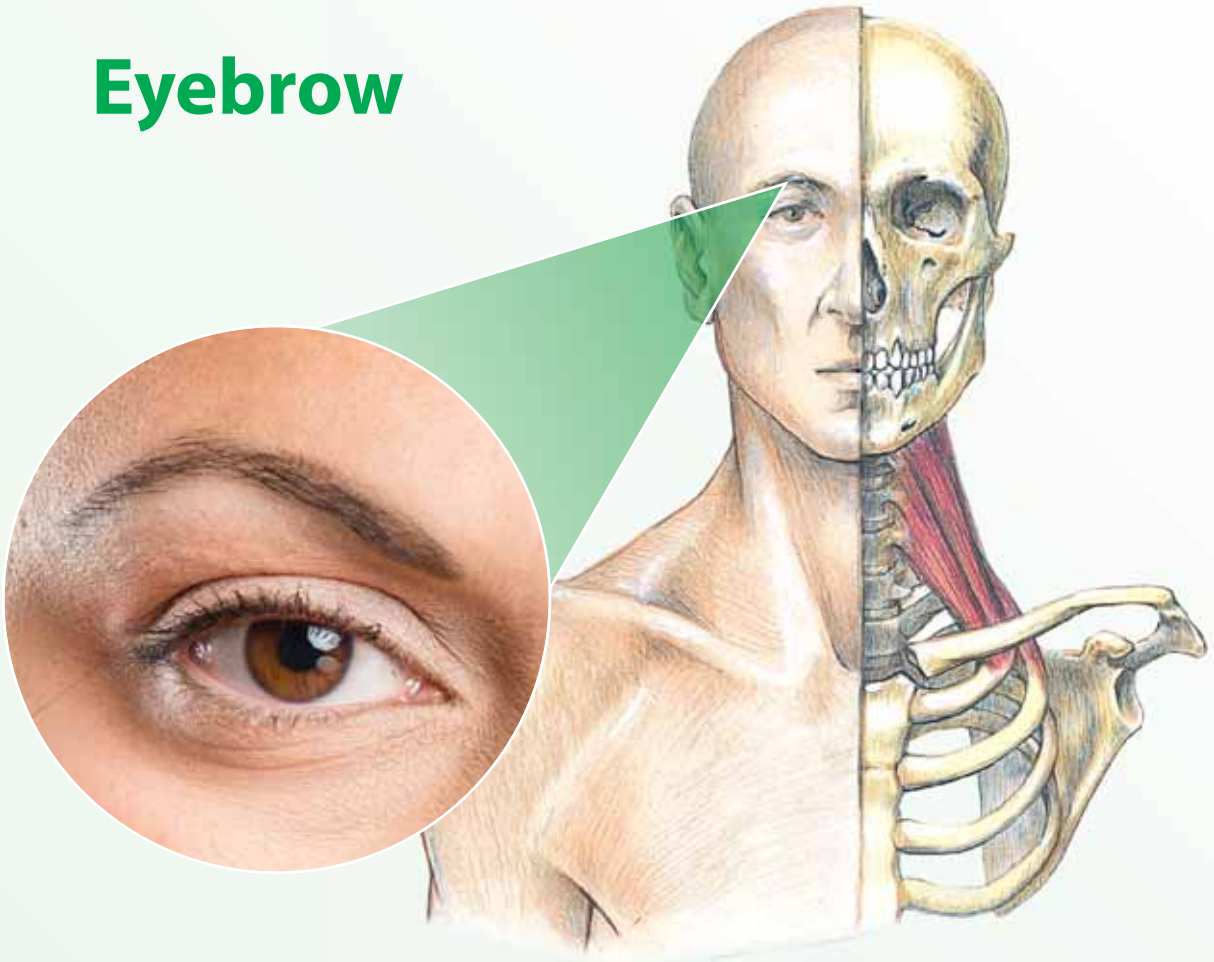
ΔΡ

Iji

lyi

Oeil

# Eyebrow



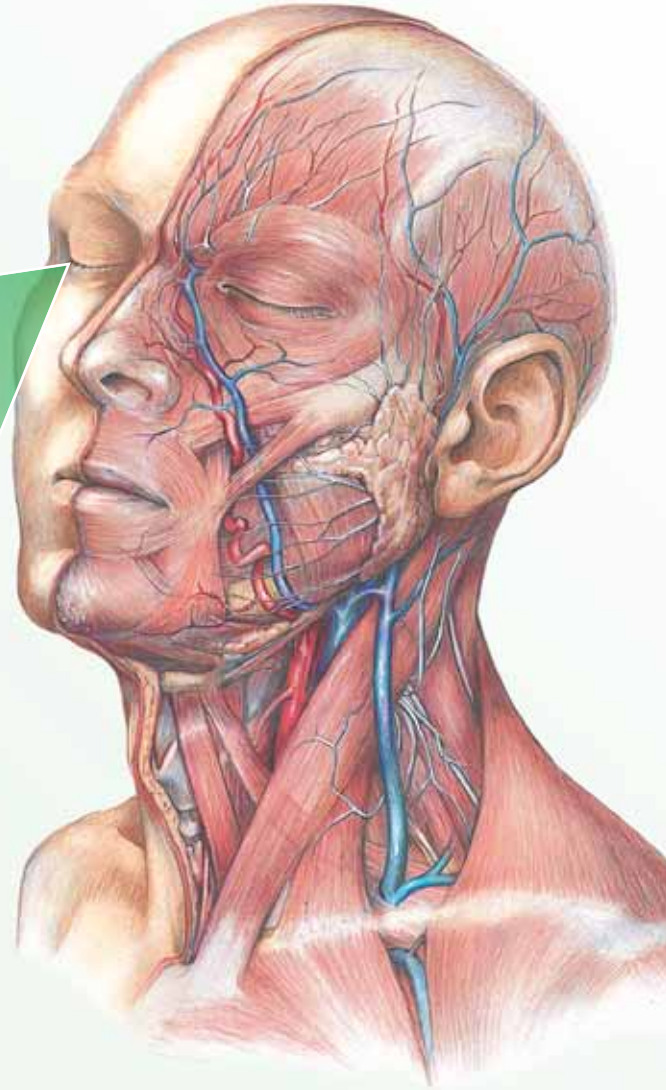
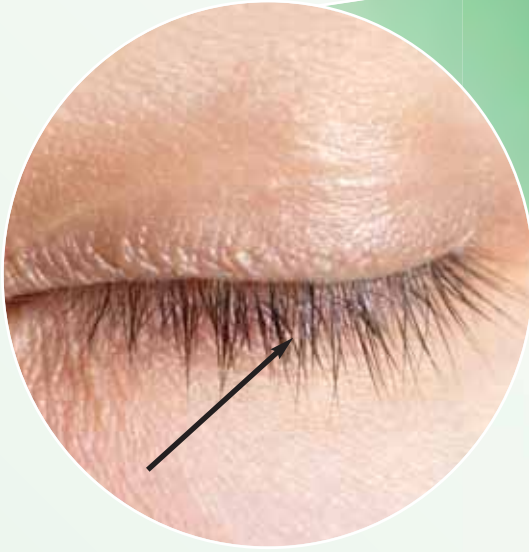ጻፍ

Qallu

Qablu

Sourcil

# Eyelashes



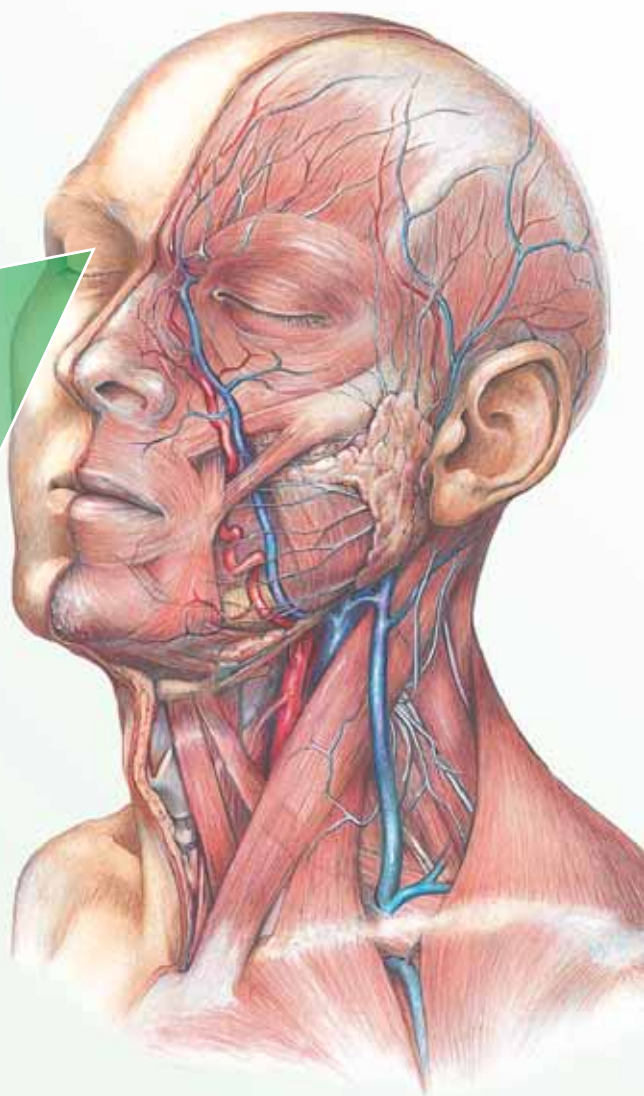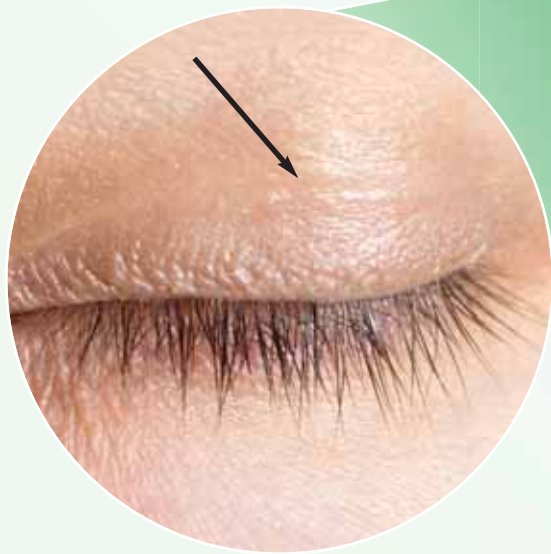ᠴᠢᠮᠢᠷᠢᠲ

Qimiriat

Qimiriat

Cils

# Eyelid



Δῖῖῖῖ ῖῖῖῖ

Ijiup Qulaa

Qablunaq/Pumngataa

Paupière



# Face



ᐅᐱᑦᑲ

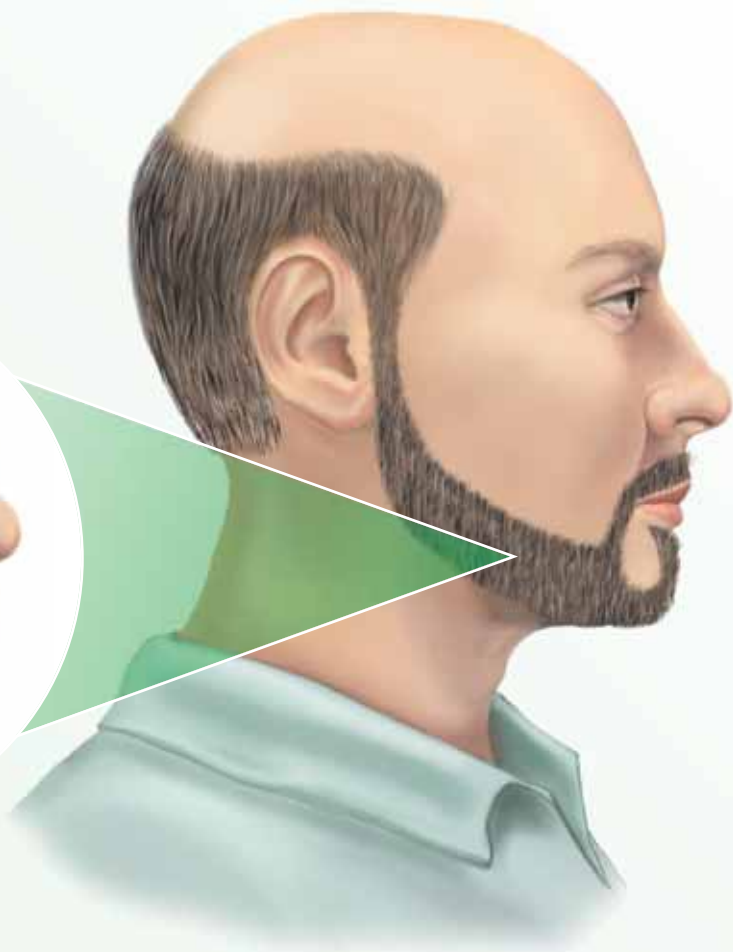Kiinaq

Akuliak

Visage



## Facial Hair



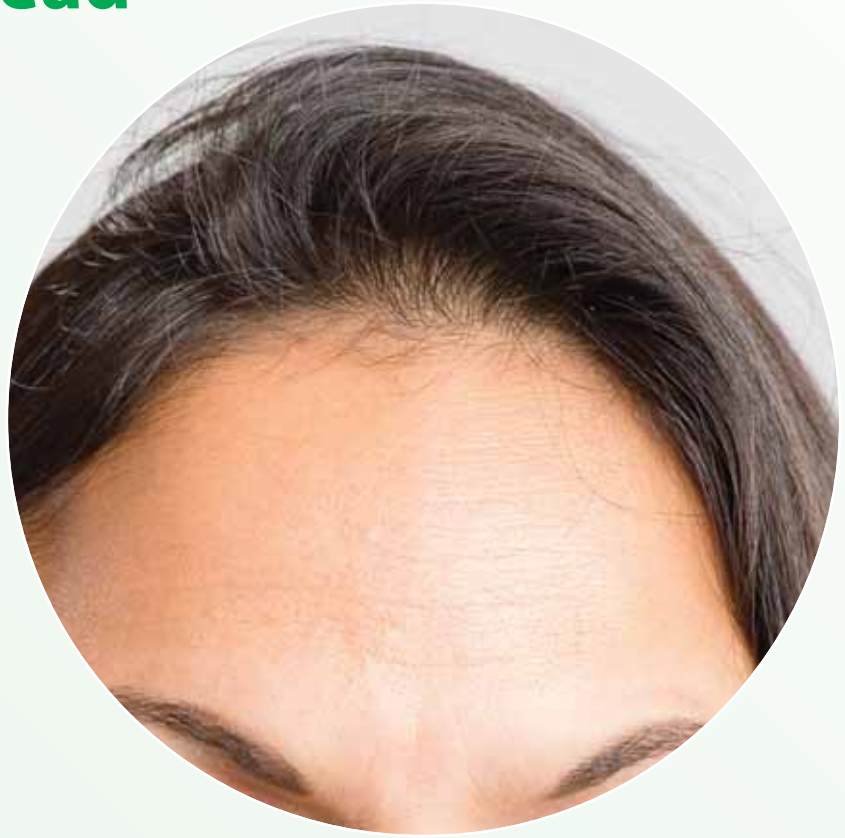▷ГԳԵԳՃԵ

Umiqarvik

Umiqarniq

Zone pileuse du visage  
(moustache et barbe)

# Forehead



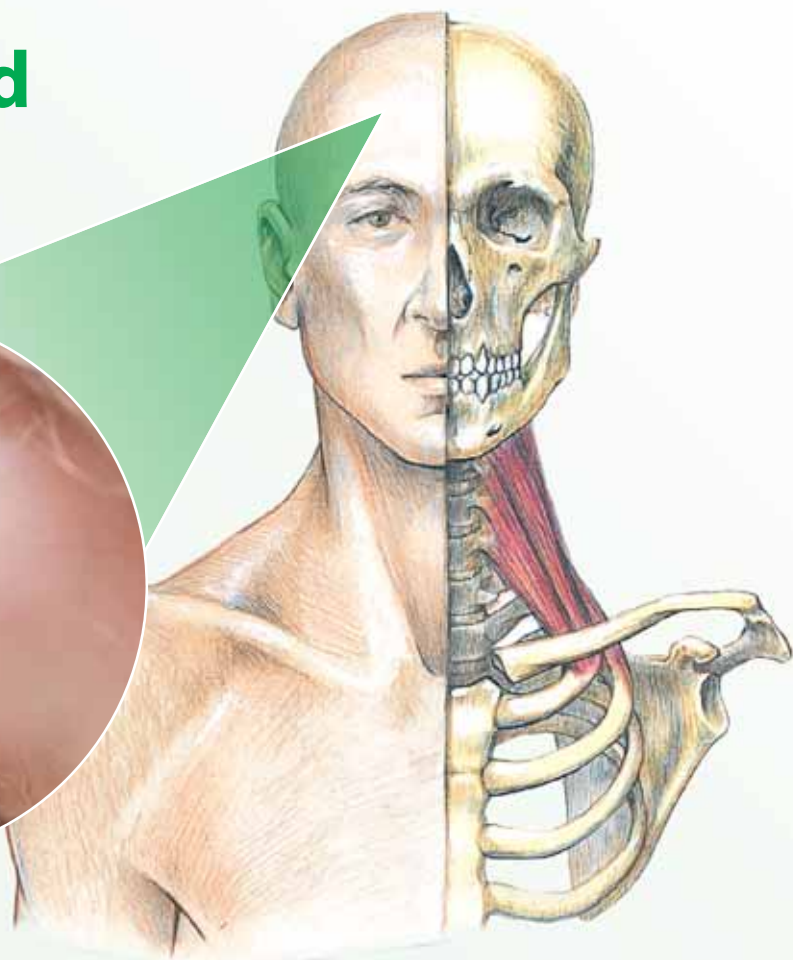
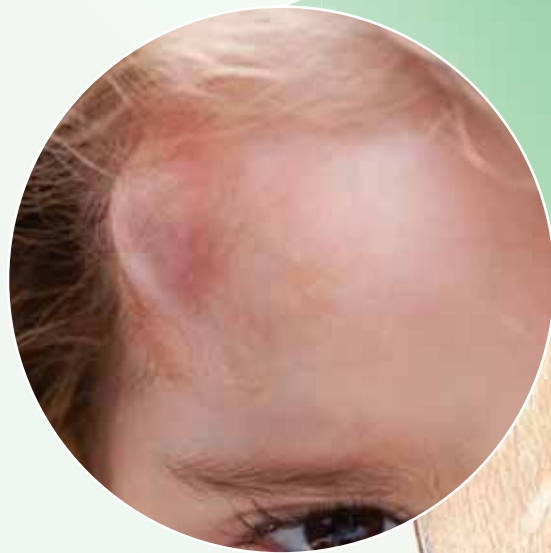ᑦᑲᑦᑲ

Qauq

Kiinaq

Front

# Forehead Bump



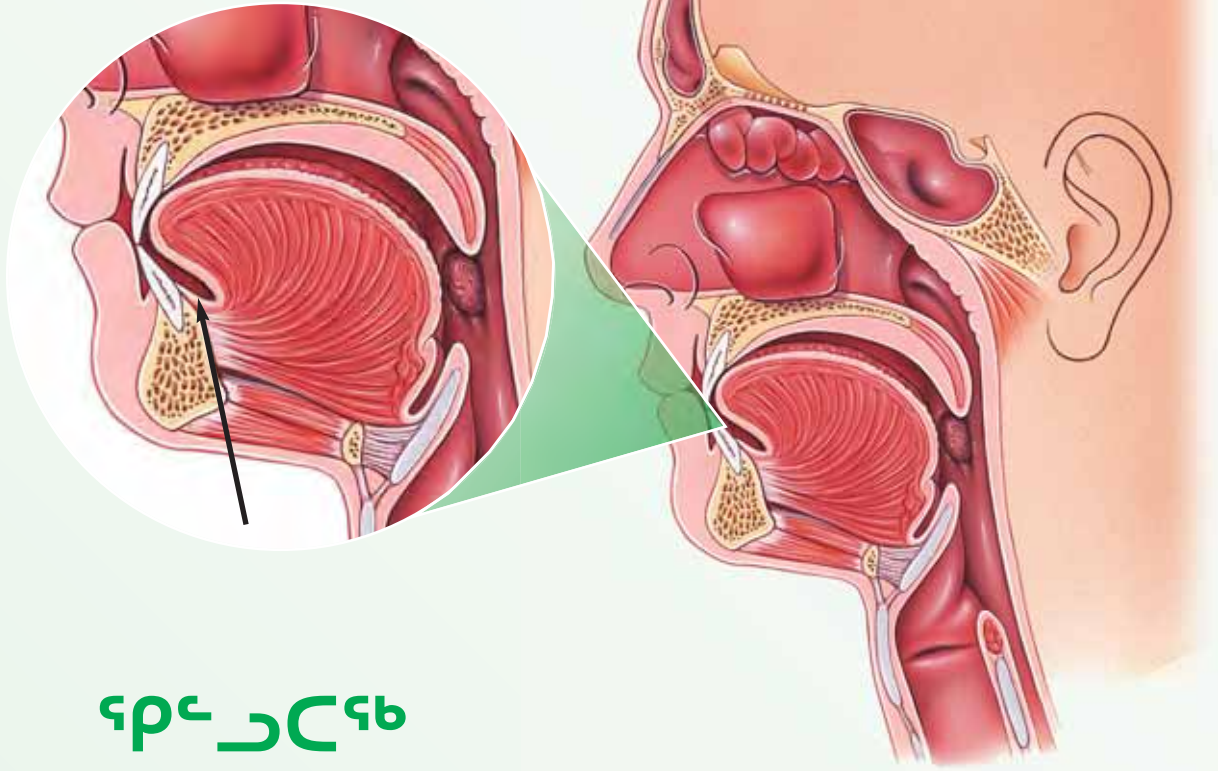
Δ ᄅᄃ ᄅᄃ

Iqsaq

Qauq

Bosse frontale

# Frenulum of the Tongue




ᑭᓯᓴᓐ ᓴᓴᓴᓐ

Qillutaq

Nuqarut

Frein de la langue

# Front Hair



𐌸𐌹𐌳𐌹𐌳𐌹

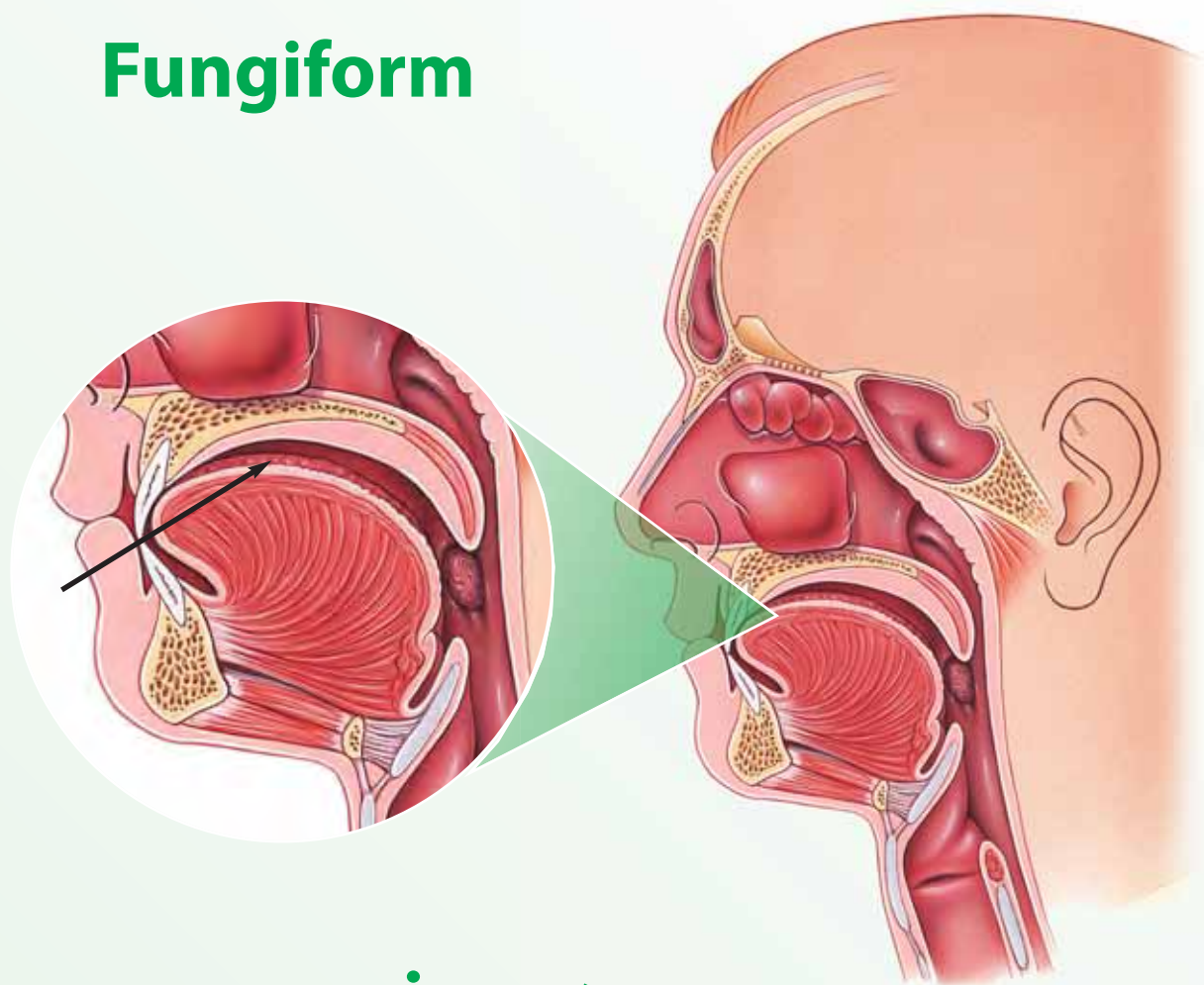
Sivuit

Hivum Nuyat

Cheveux de devant



# Fungiform



ᐃᑦᑲᐃᑦ ᑦᑲᑦᐱ/ᐱᑦᑲᐃᑦᑦ

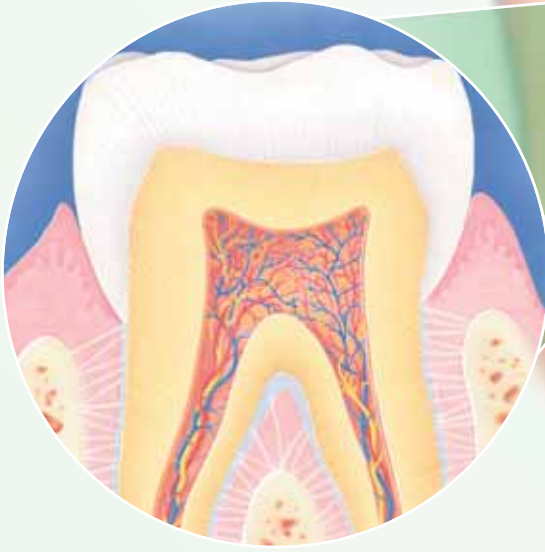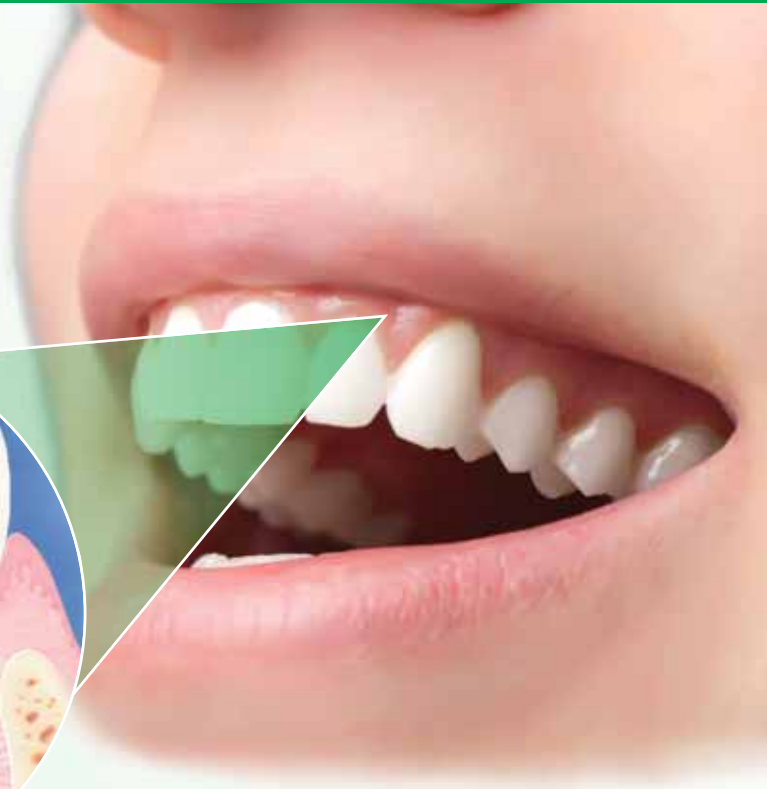Uqaup Qaanga/miqqungit

Nuvaliurvik

Papilles fungiformes



# Gum / Gingiva



Δᵇᵣᶜᵇ

Ikkiaq

Kigutinilirvik

Gencive

# Hair



نواجق

Nujait

Nuyaq

Cheveux

## Hair at the Nape of Neck



ᑕᓄᓂᓄᓂᓂᓂ ᓄᓂᓂᓂᓂᓂ

Tunusungmi Nujarusiit

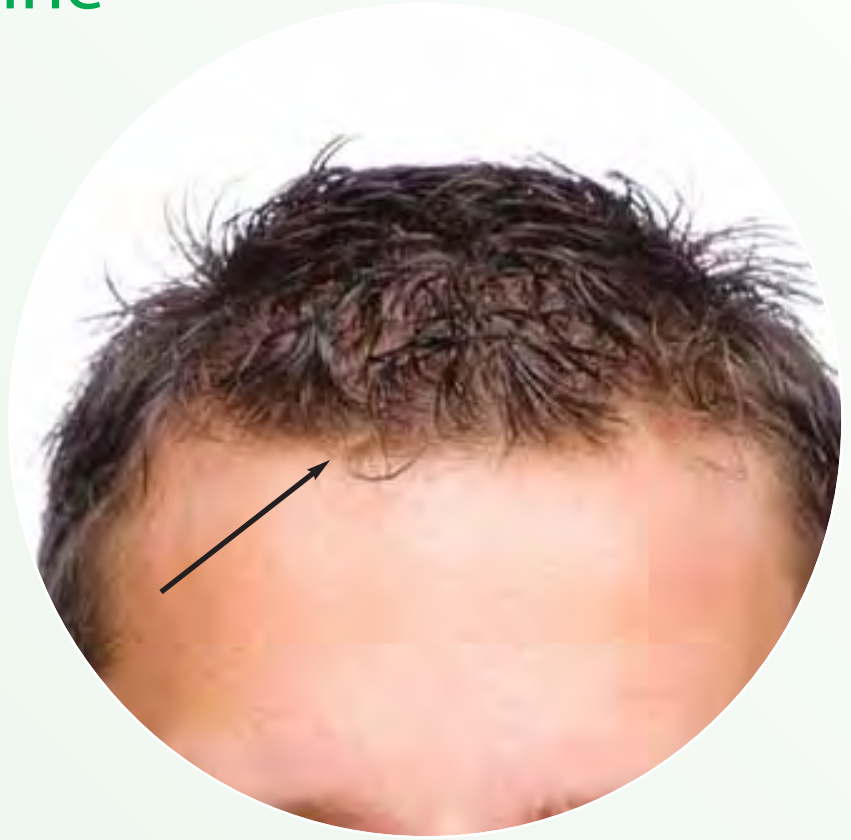
Tunuhugutit

Cheveux sur la nuque





# Hair Line



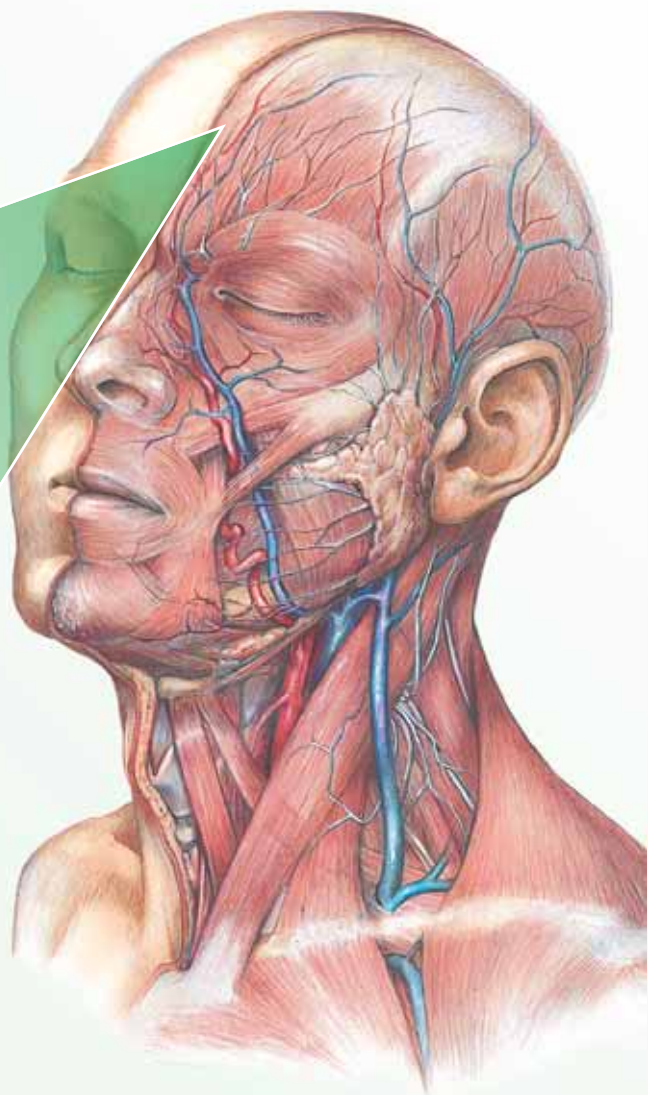
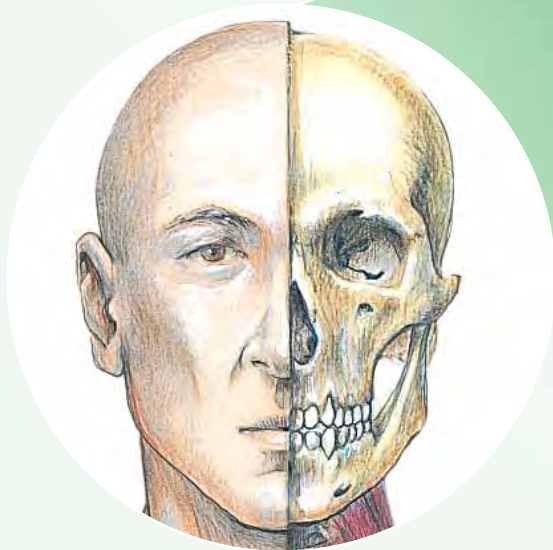
ᐃᐱᐱᐱᐱᐱᐱ

Nujarusiq

Nuyat Kiglinga

Raie des cheveux

# Head



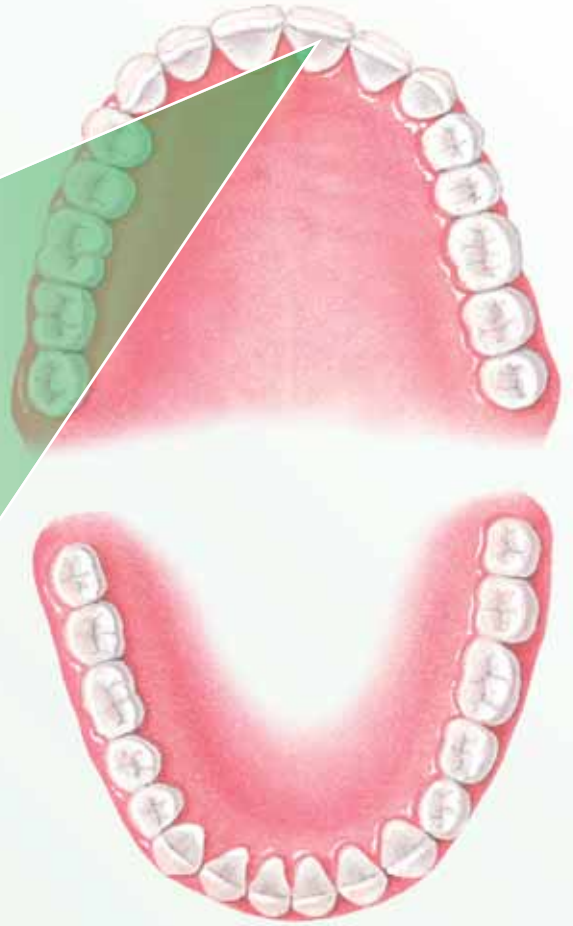ᓄᐱᓄᓄᓄ

Niaquq

Niaquq

Tête

# Incisor



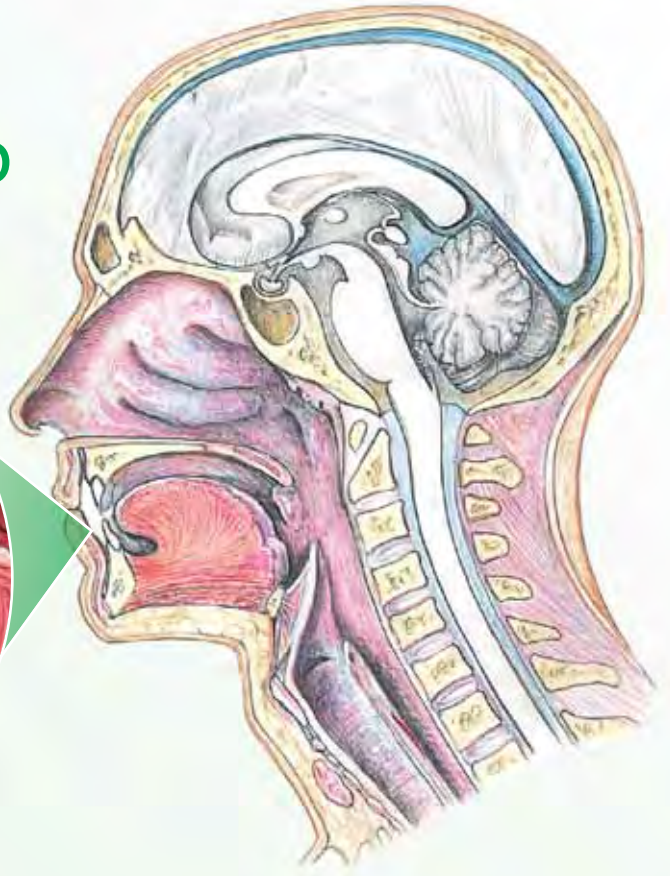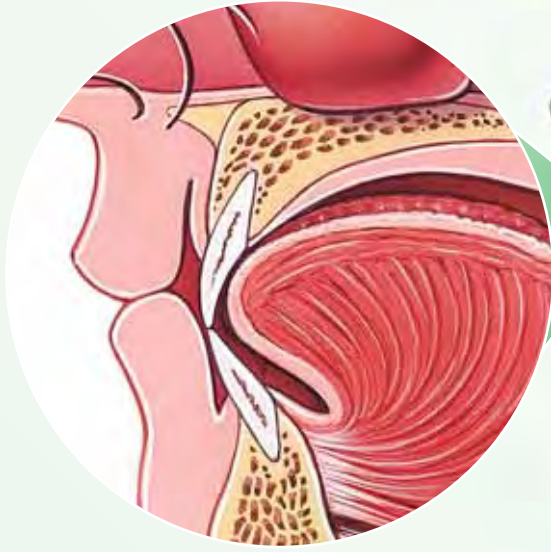ᐱᑦᐱᑦᐱᑦ

Sivuat

Hivuaq

Incisive

# Inside of the Lower Lip



ᑭᑎᑭᑎᑎᑎᑎᑎ

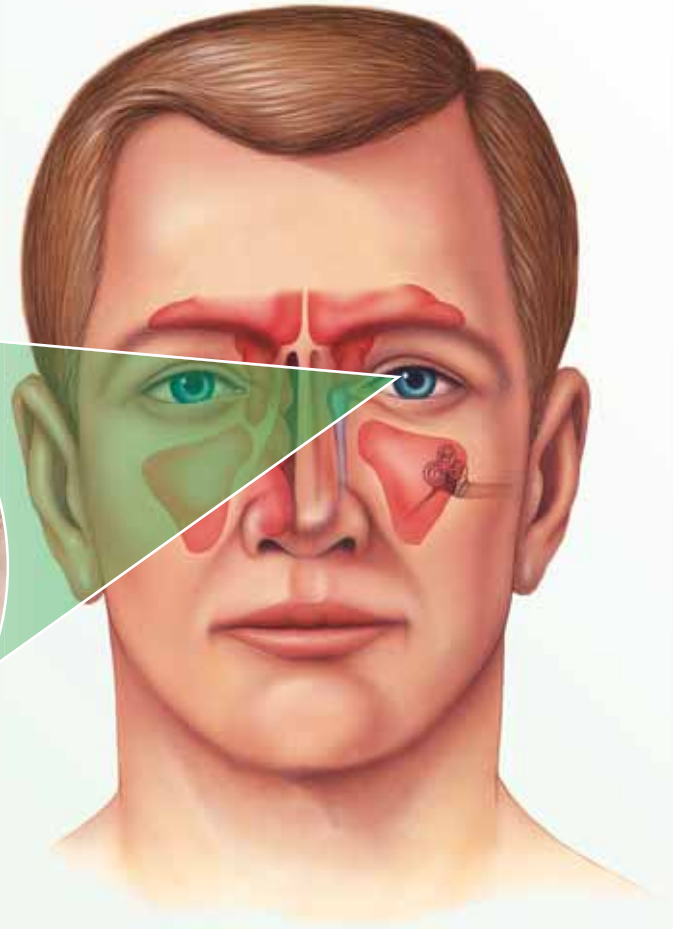
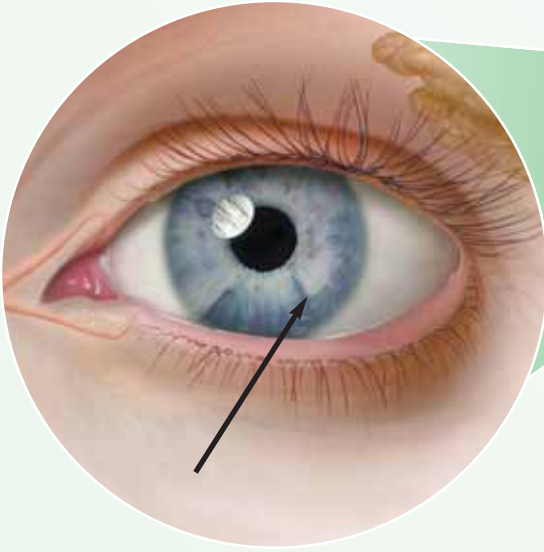
Qangasinaaq

Qaqhup Ilua

Intérieur de la lèvre  
inférieure



# Iris



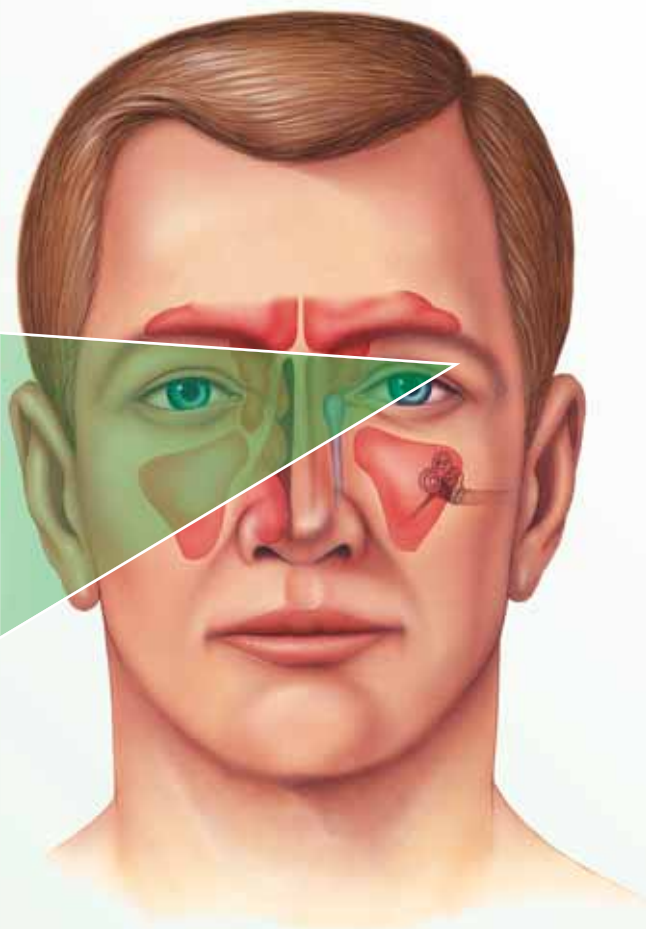
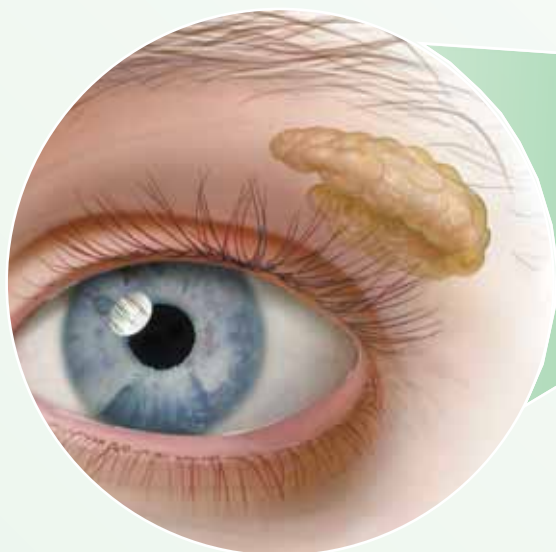Δῖῖῖ ῖῖῖῖῖῖῖῖ

Ijiup Qirnaangananinga

Tautuut

Iris

# Lacrymal Gland



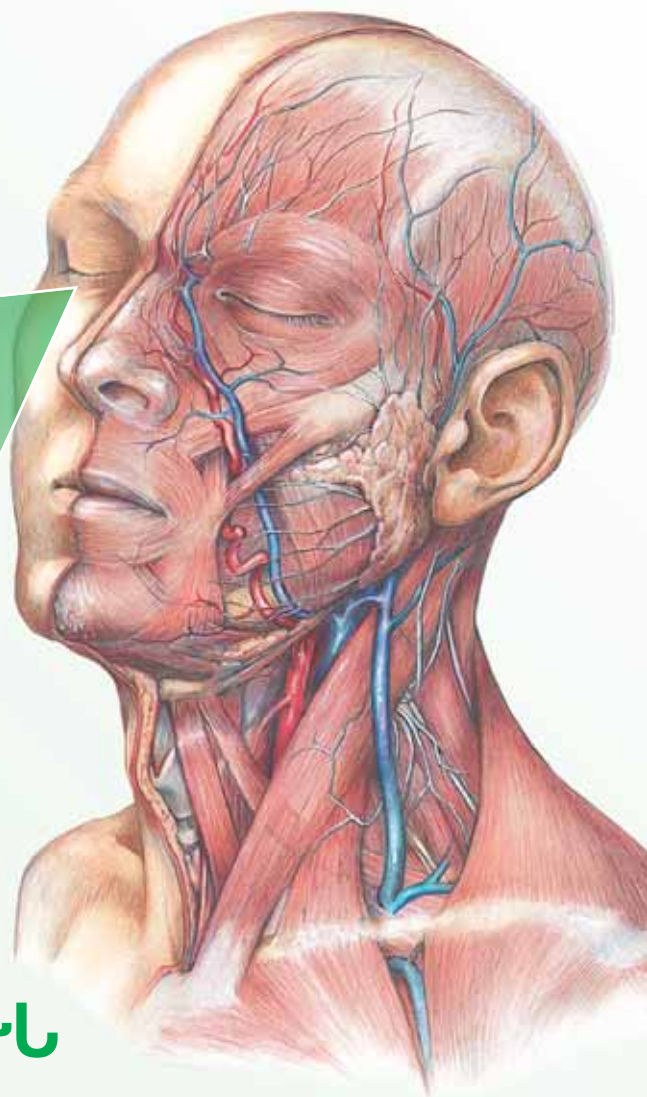
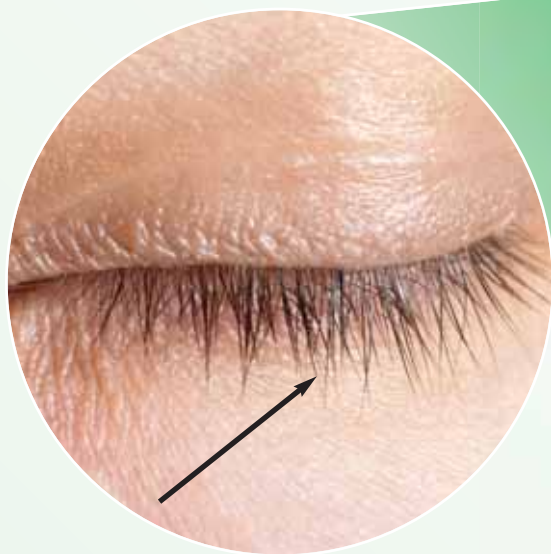ᑭᑭᑭᑭᑭᑭ

Quvviksaq

Qulvilhuq

Glande lacrymale

# Lower Eyelid



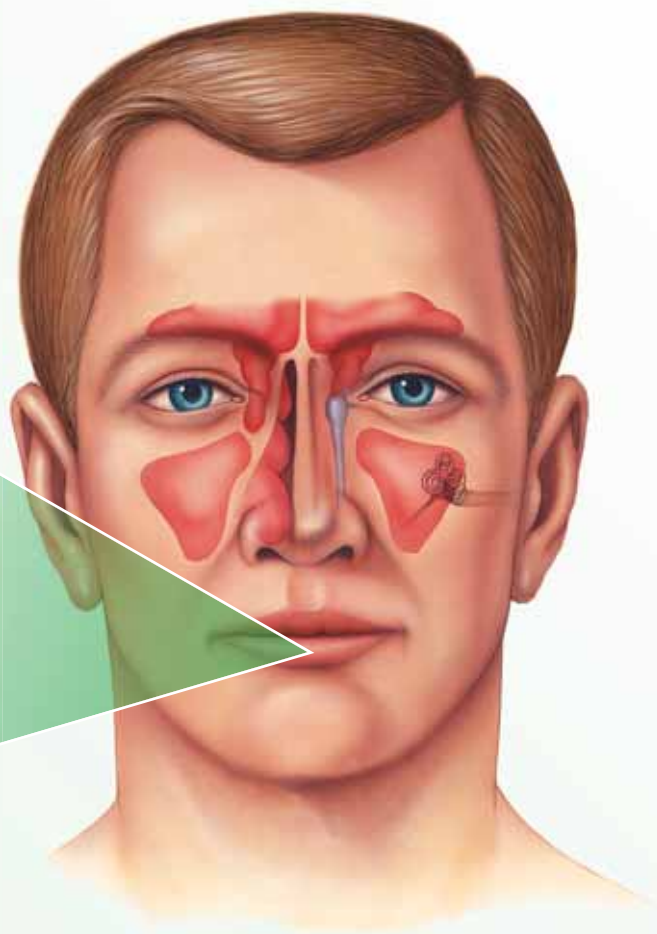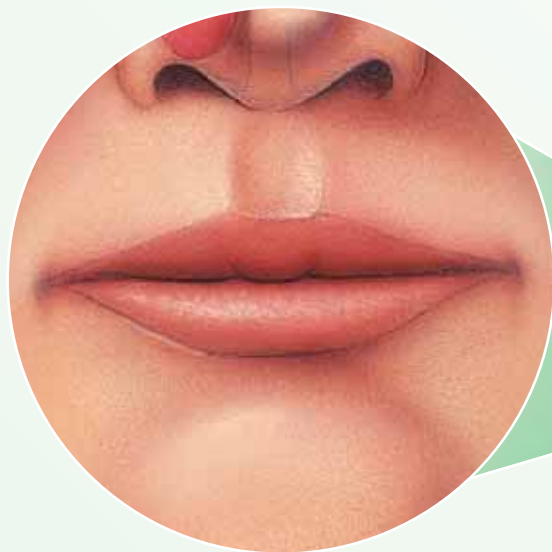ΔΡΔ< ΔΝ<ΐ<ΐ

Ijiup Atingaanga

Qulvilhuq

Paupière inférieure

# Lower Lip



قباقبا

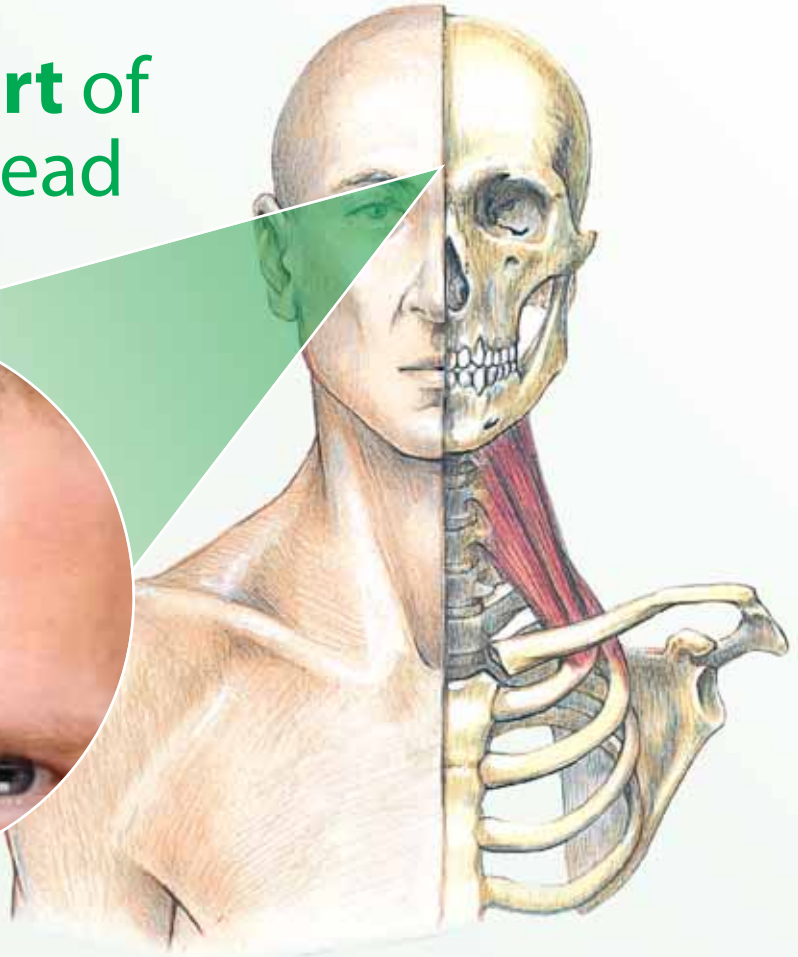
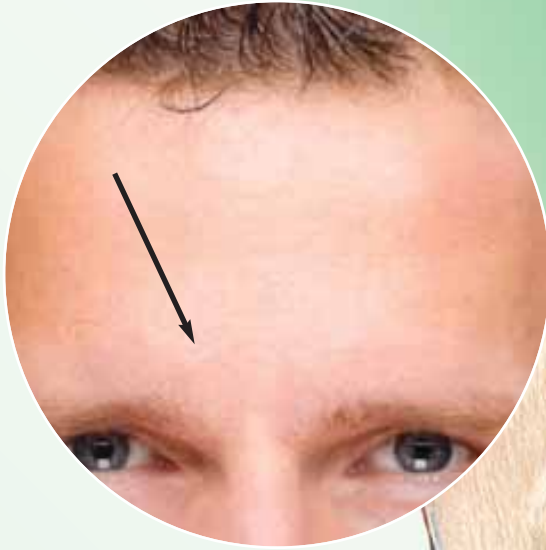Qaqtu

Qaqhuq

Lèvre supérieure / intérieur  
lèvre (inférieure)



# Lower Part of the Forehead



ԳՐՏԵՂԳՆ

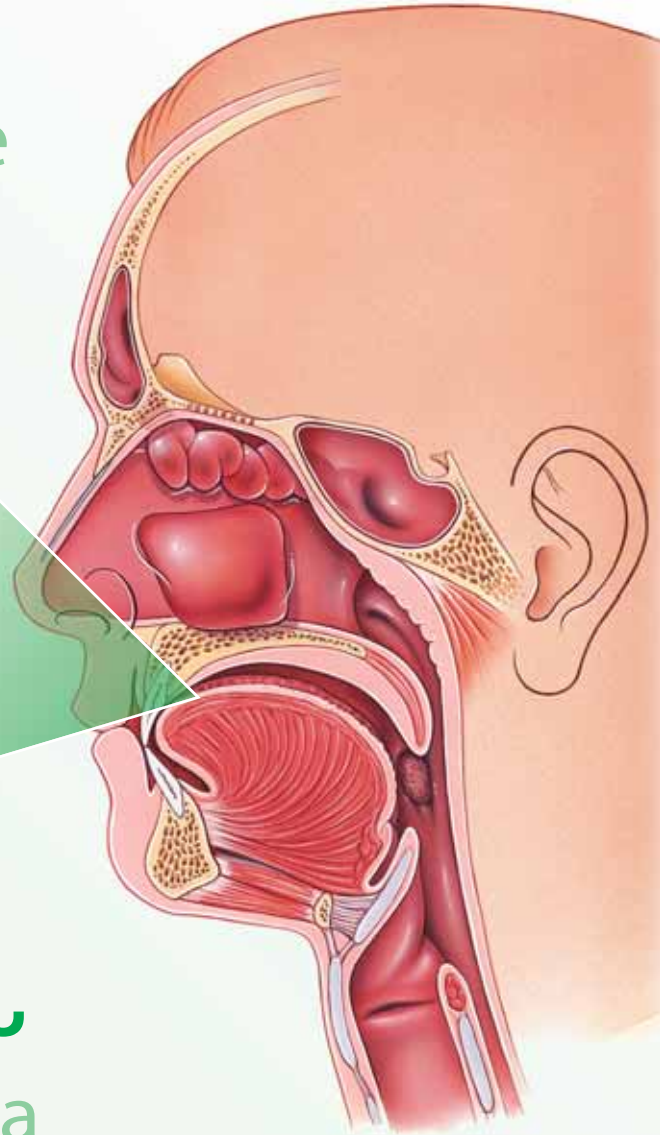
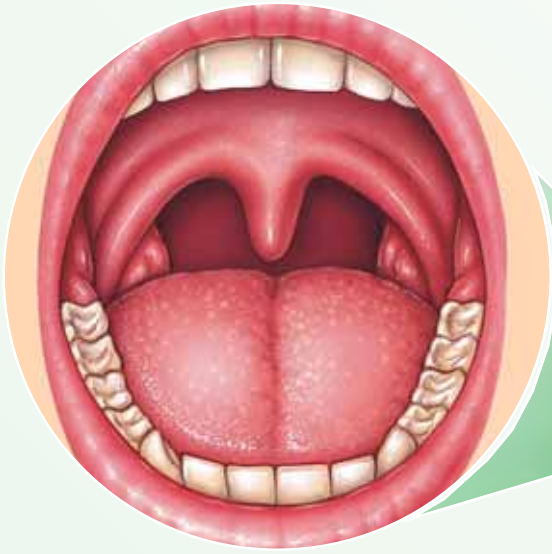Qinnguq

Qin'nguq

Partie du bas du front



# Median Line of the Tongue



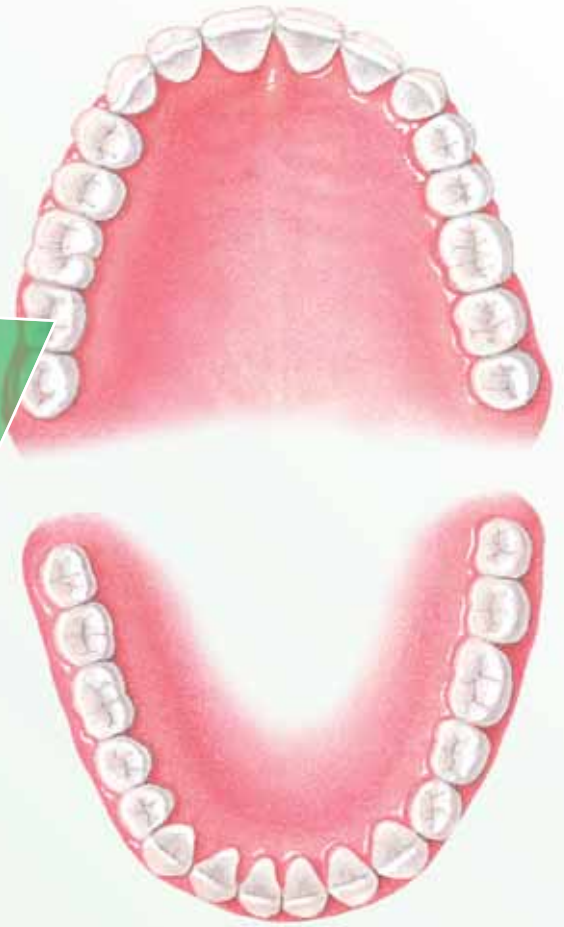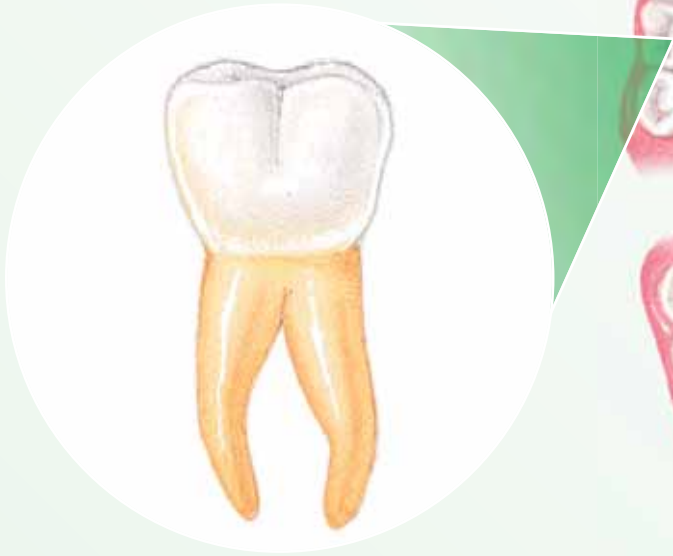▷ԳԵ▷Կ ԳՐՈ՞Ն

Uqaup Qitinga

Uqqap Qitqa

Sillon médian de la langue

# Molar



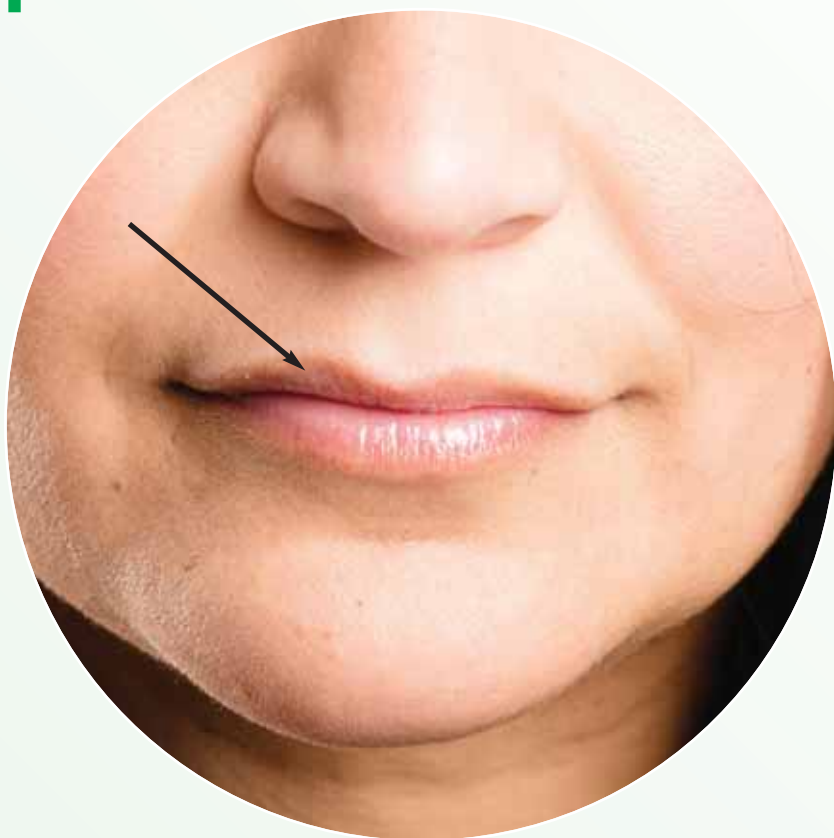Δ ၄၆ ၵ ၄၆ < ၆

Iq̄tiqqak

Iq̄hiqqak

Molaire

# Mouth



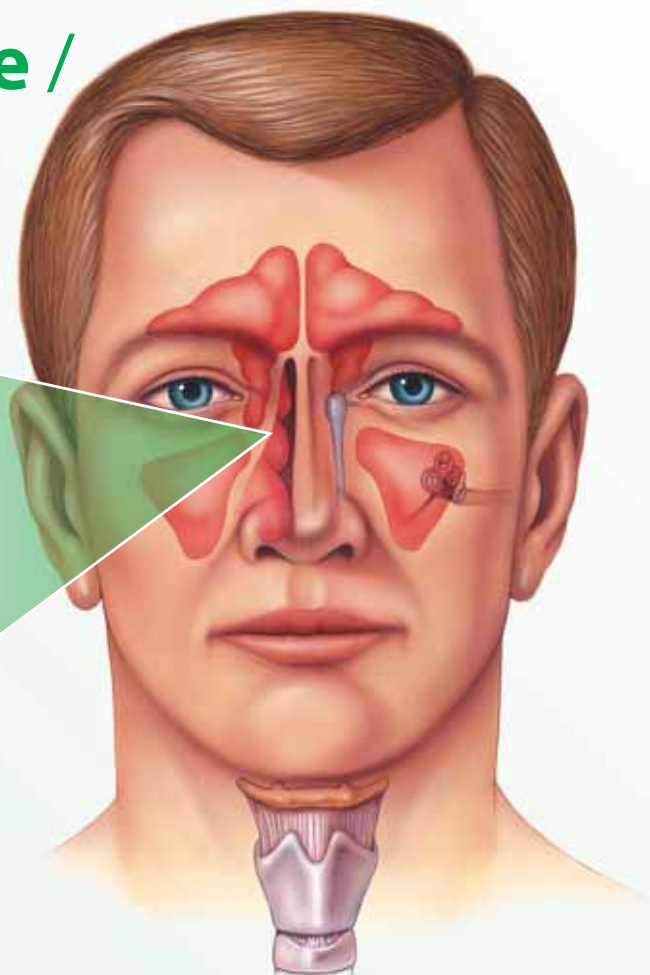
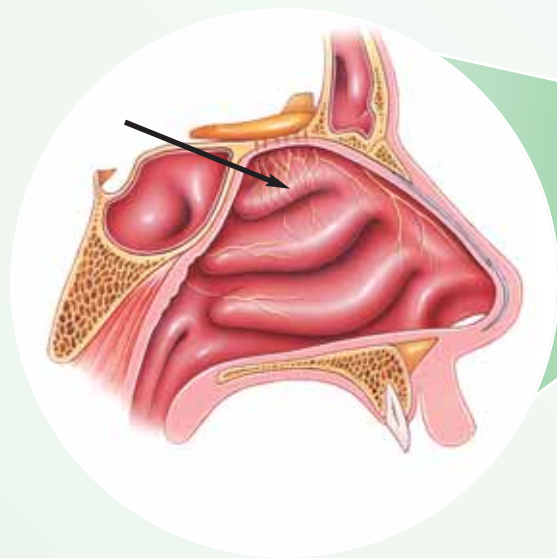
ጻብጻብ

Qaniq

Qaniq

Bouche

# Nasal Conchae / Turbinate Bones



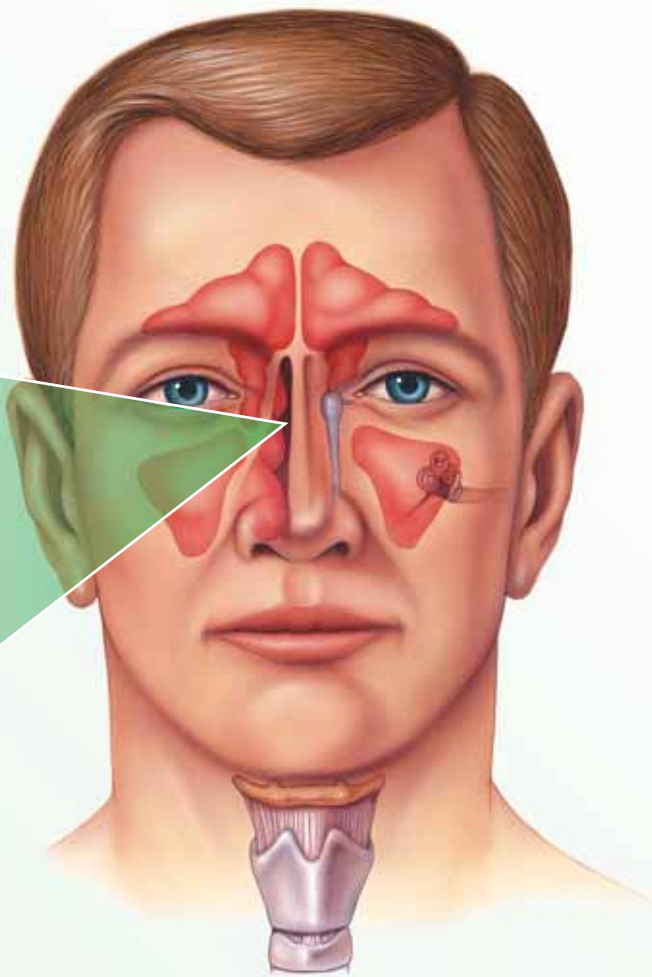
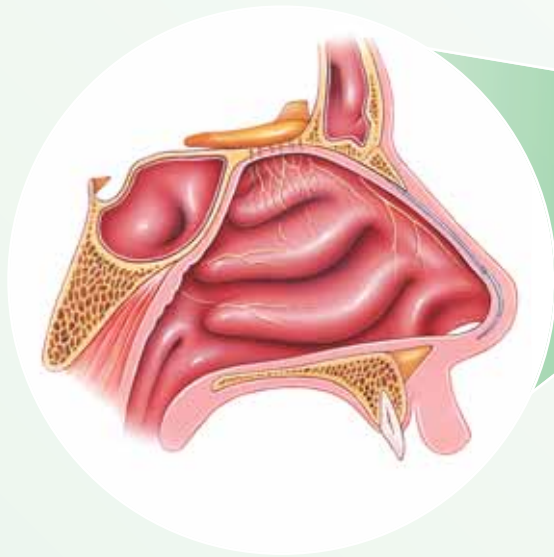
Δ J Δ C

Imujait

Umiitaa

Cornets

# Nasal Fossa



ΔΝῤῥῖσῤῥῖ

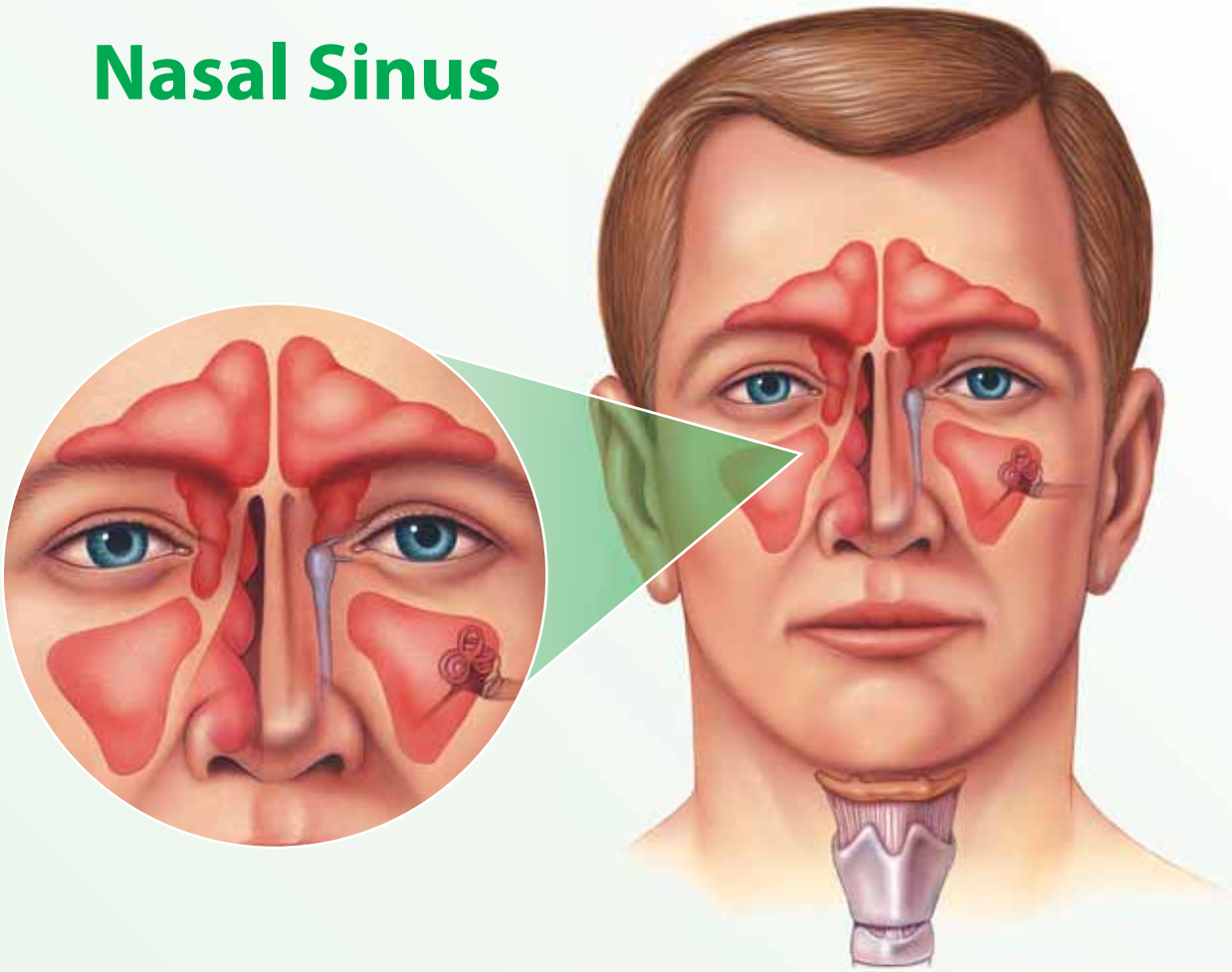
Itiqqirniq

Hurluk

Fosse nasale



# Nasal Sinus



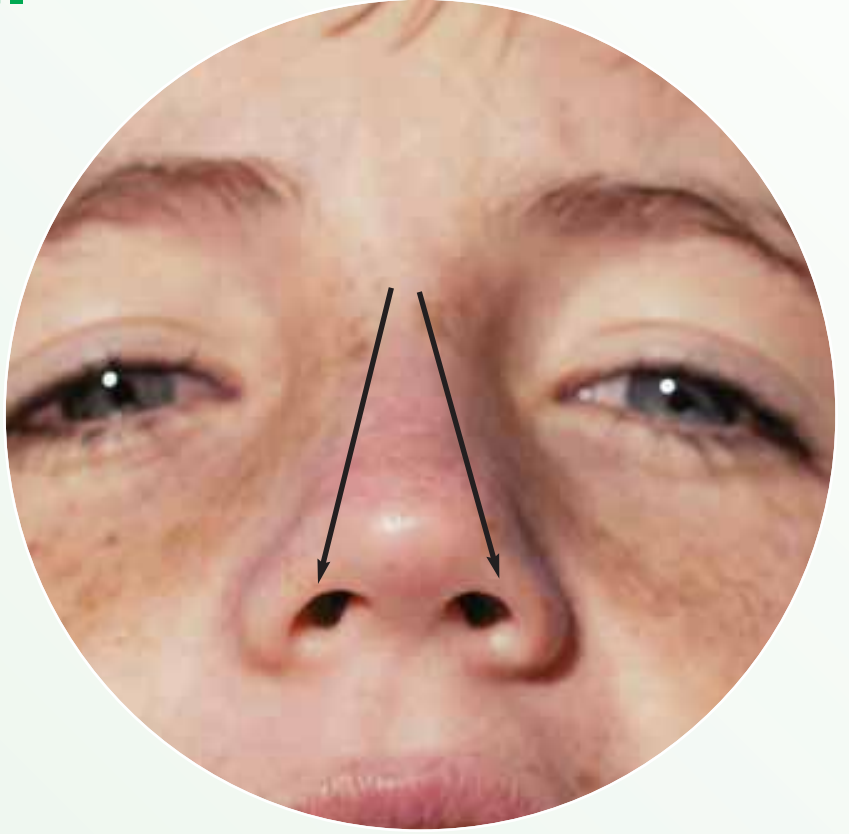
ΔΛΙΝΟ

immutit

Hurluup Qaqqulaanga

Sinus nasaux

# Nostril



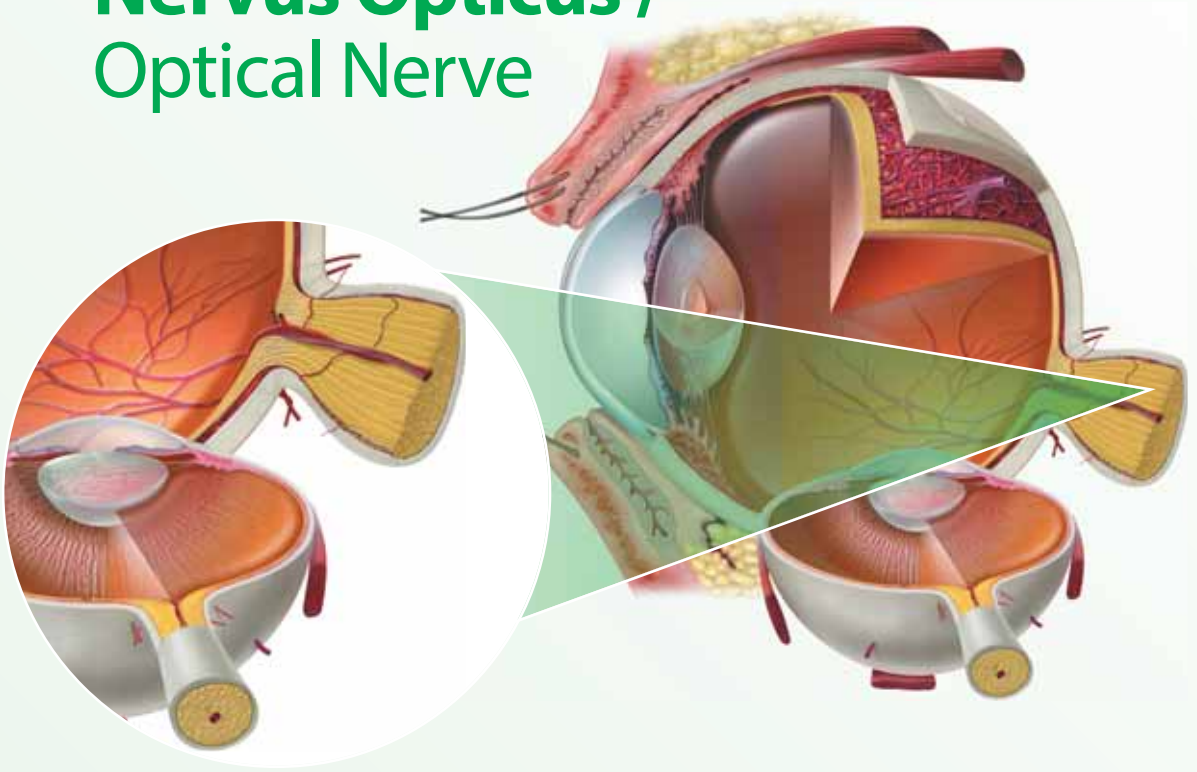
بؤرۈك

Surluk

Hurluk

Narine

# Nervus Opticus / Optical Nerve



Δῖῖῖ ΔΛῖῖῖ

Ijiup Ipiutanga

Iyip Attataa

Nerf optique

# Nose



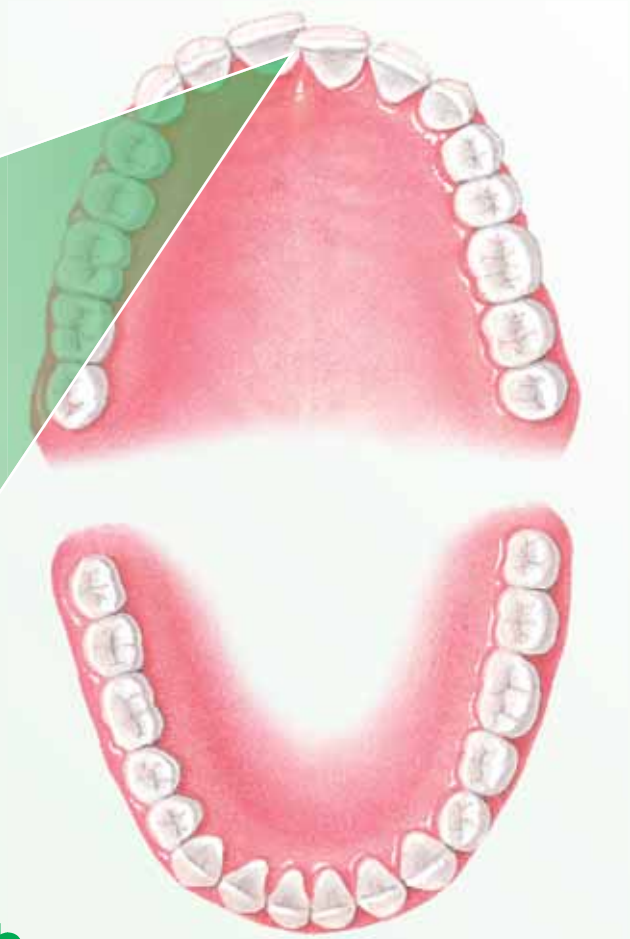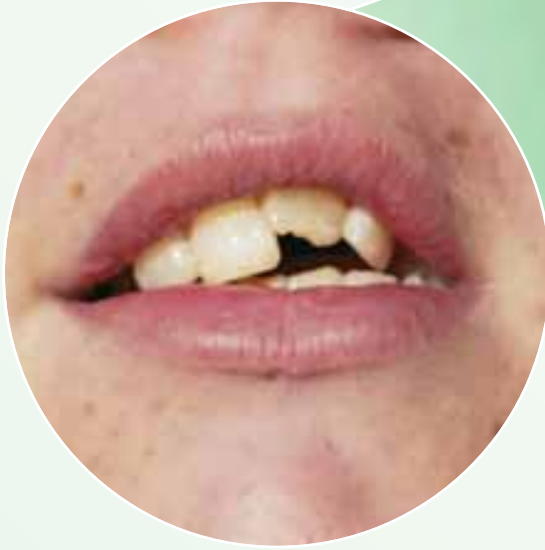
ᄒᄒᄒᄒ

Qingaaq

Qingaaq

Nez

# Overlapping Teeth



ᐆᓯᓂᐱᐅᓴᐅᓴᓴᐅᓴᐅᓴᐅᓴᐅᓴ

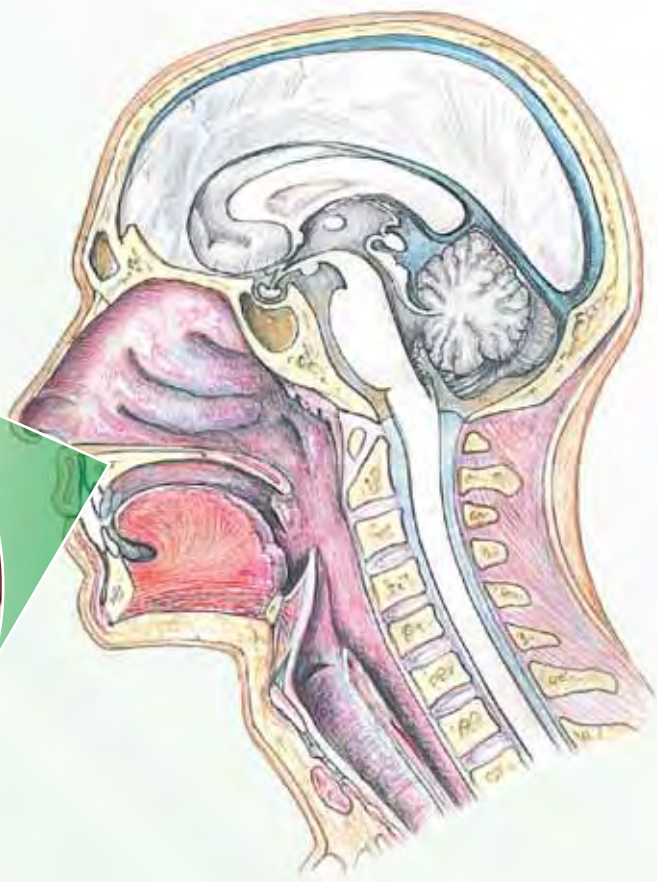
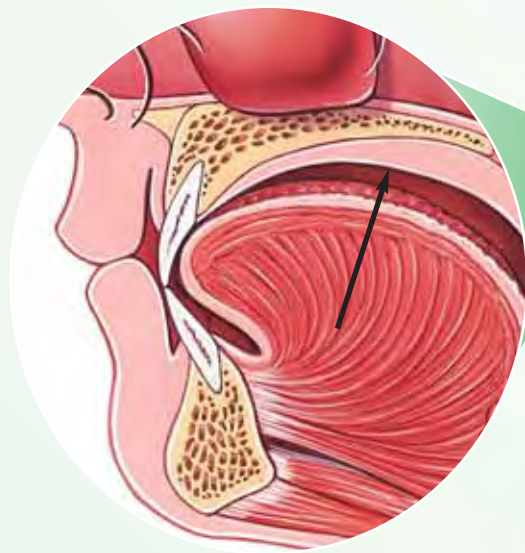
Kigutippalaaqtuq

Kigutit Qaliriiktut

Dents qui se chevauchent



# Palate



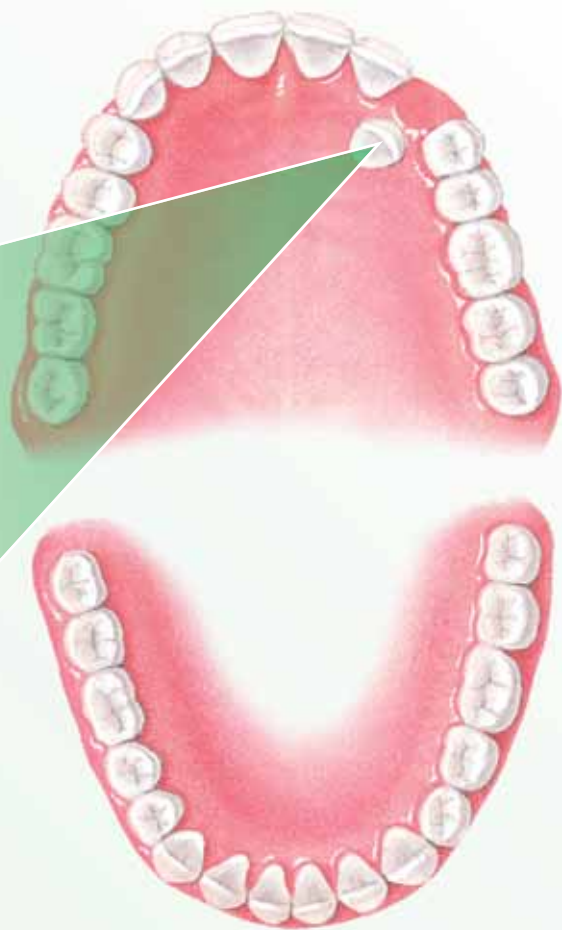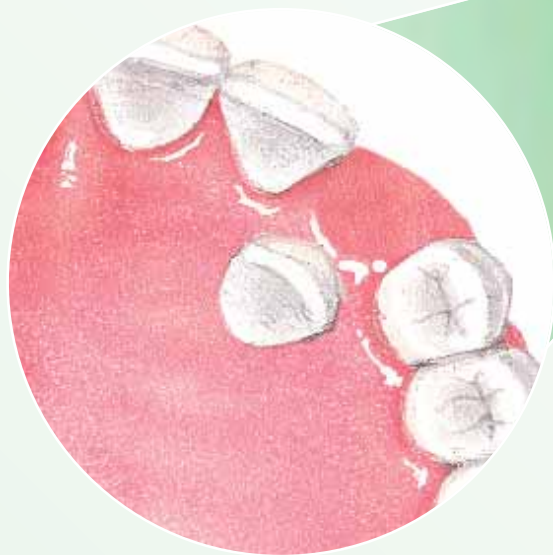
قِرْلَاق

Qilak

Qilagaq

Palais

# Palate Tooth



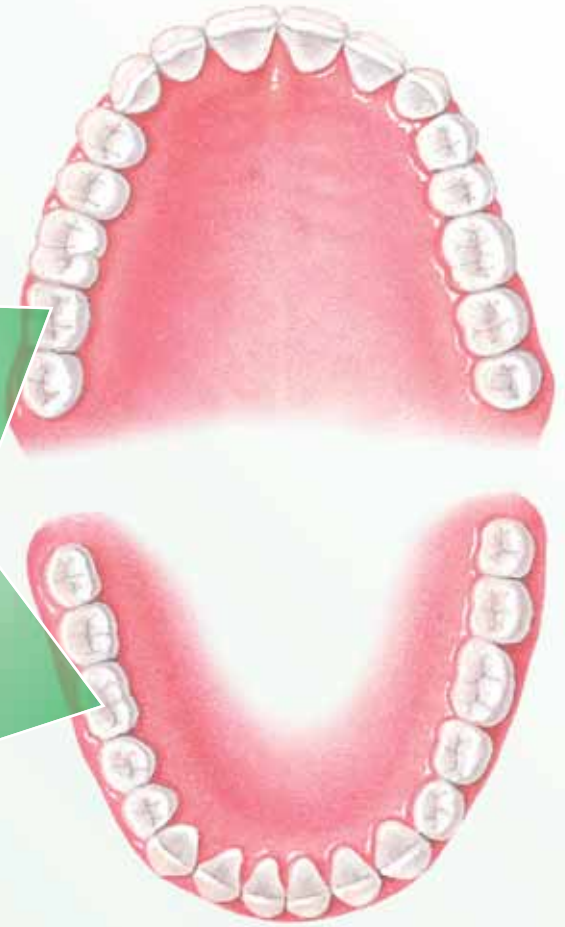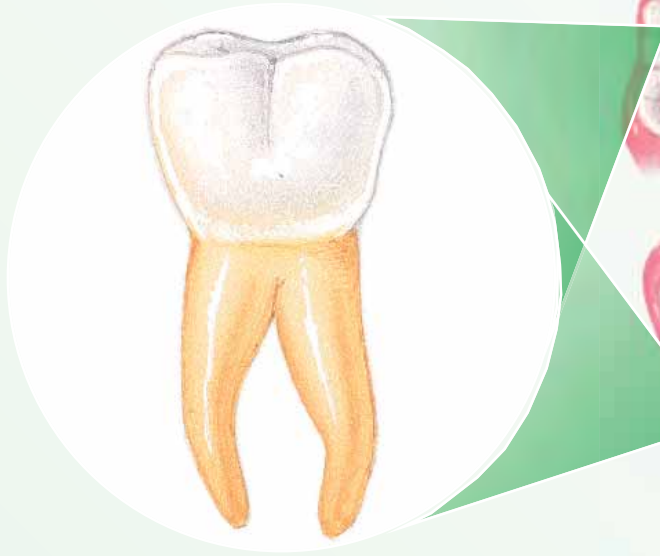ԳՐՅԿԼՈ

Qilummati

Qilangagut kigut nauyuq

Dent de sagesse

# Premolar



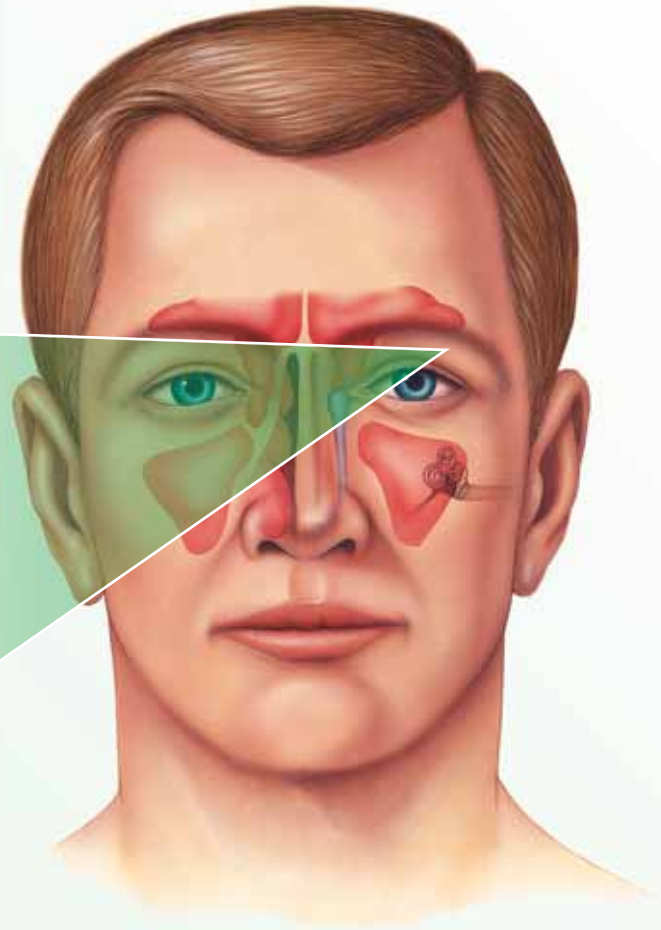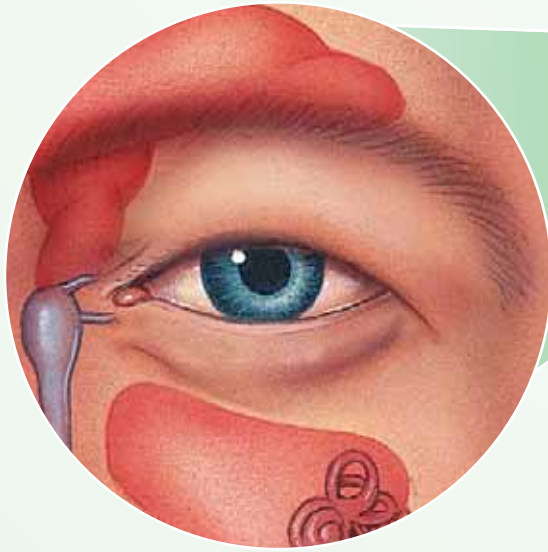
△ ㄆ ㄆ ㄆ ㄆ

Iqłiqpaq

Iqhiqpaup Tuglia

Prémolaire

# Puffy Eye



>↳↲↵↶

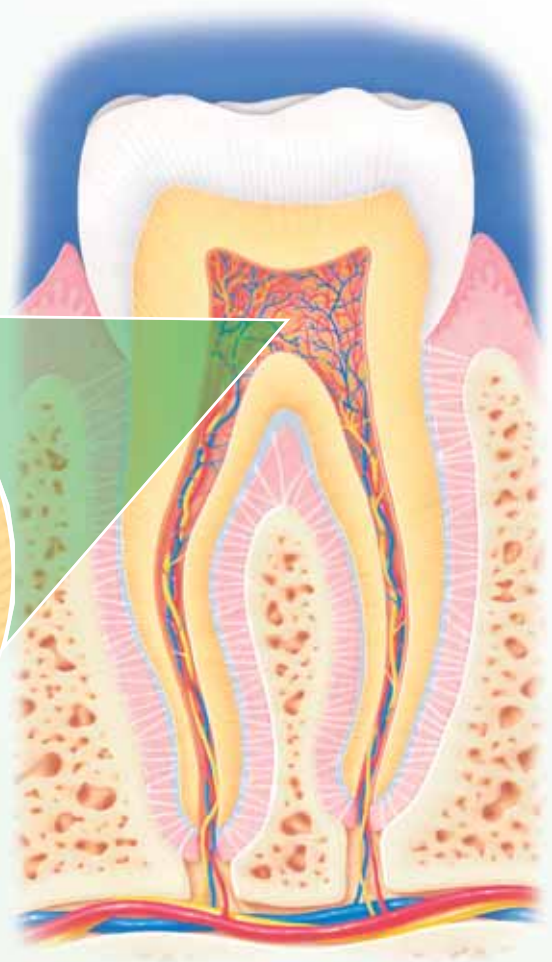
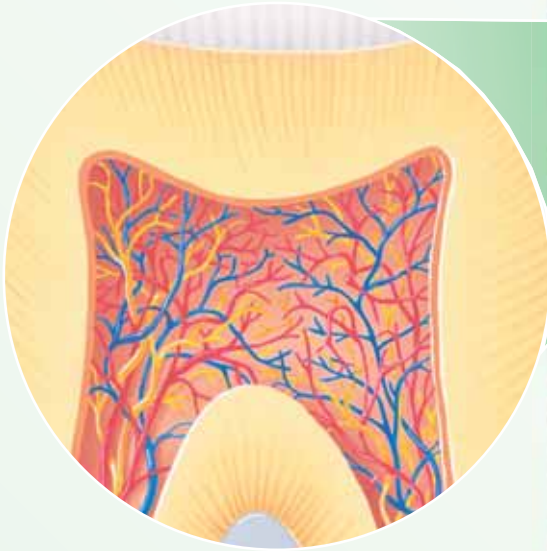
Pujjijuq

lik Puvipkaqtuk

Poche sous l'oeil



# Pulp



ᐱᑭᑦᑎᑦᑎᑦ ᐃᑦᐱᑦᑎᑦᑎᑦᑎᑦ

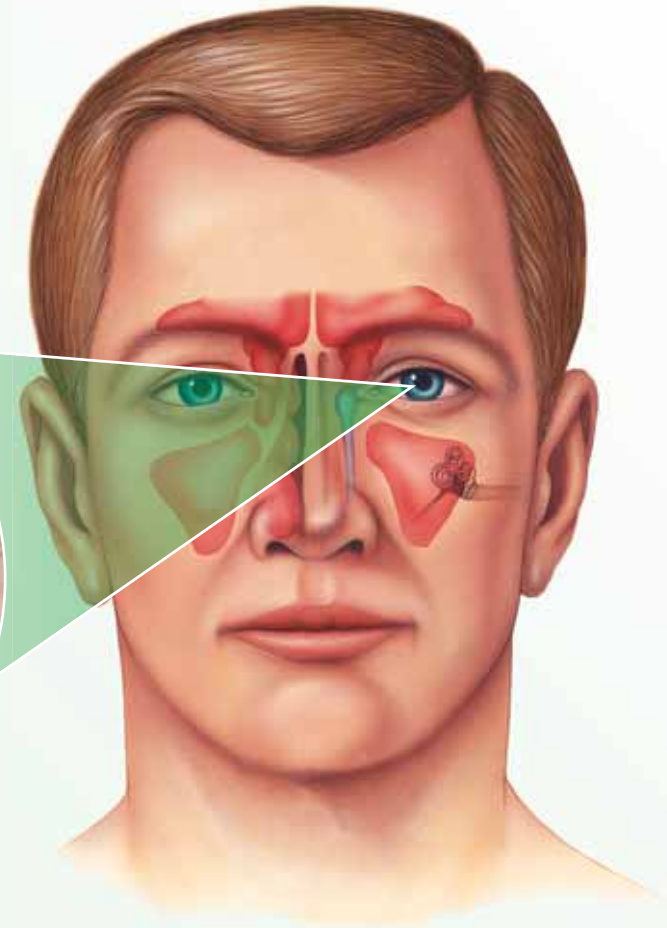
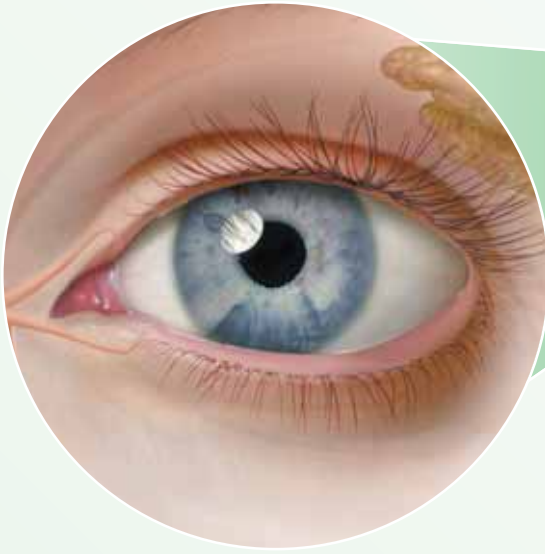
Kigutiup Ikpingniajjutinga

Kigutip Manngua

Pulpe



# Pupil



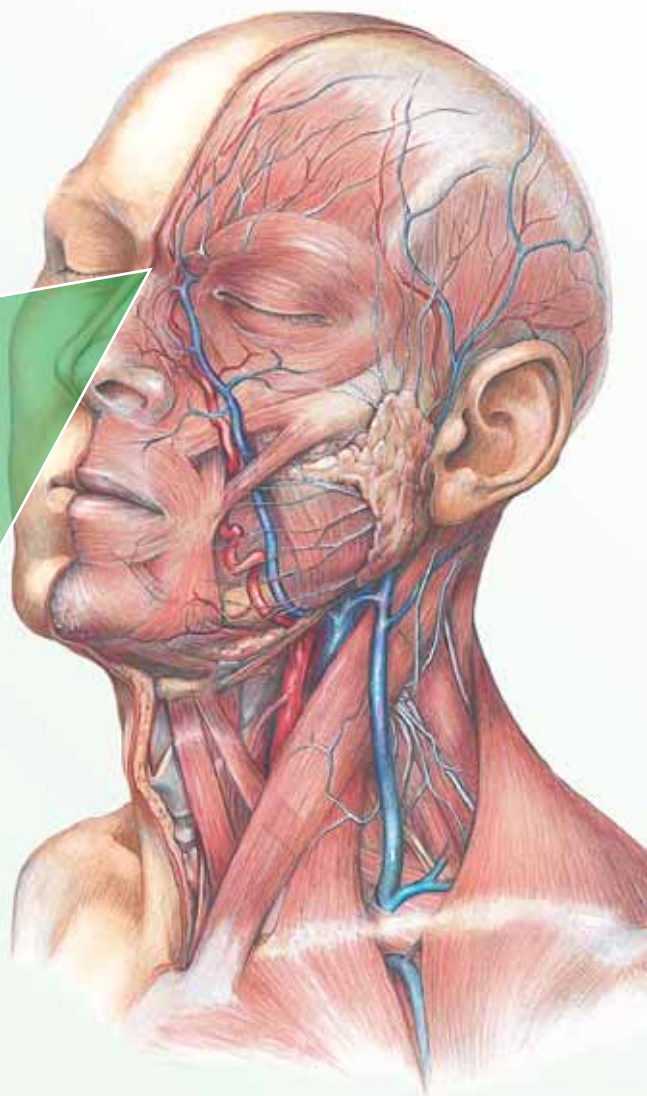
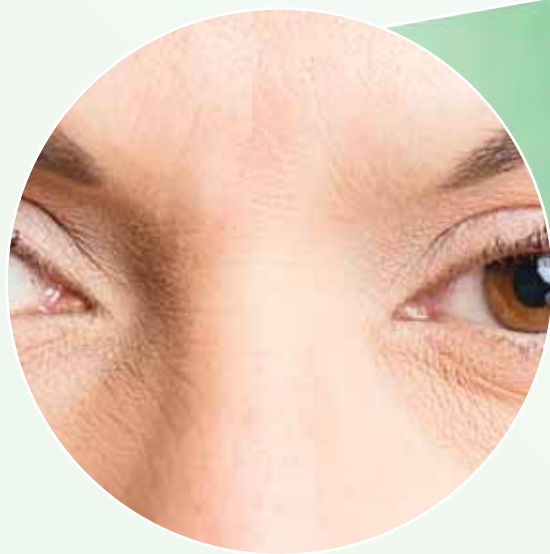ᑕᑦᑲᑦᑲᑦ

Takunnati

Takkuvik

Pupille

# Radix / Glabella / Columella



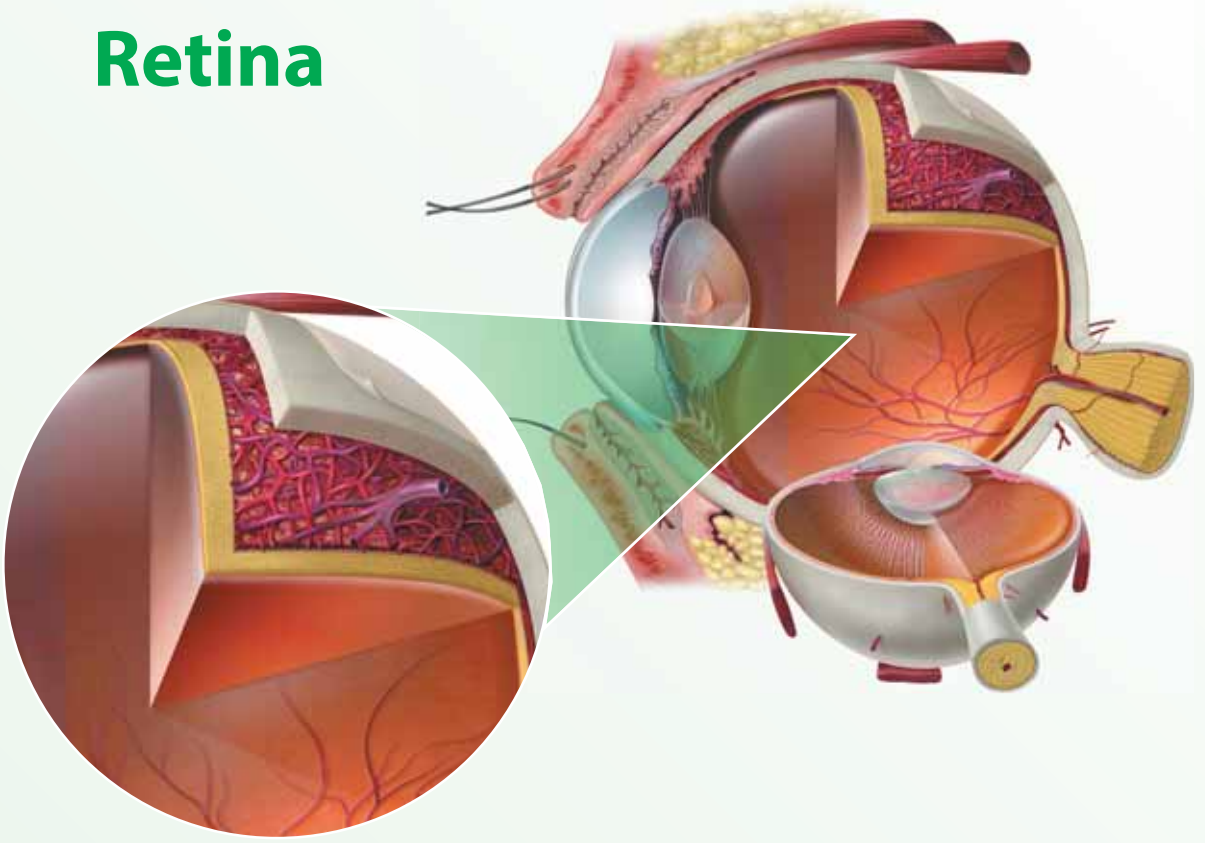
ᐱᑦᑦᑦᑦᑦᑦᑦᑦ

Akuliaq

Qin'nguq

Racine du nez glabelle,  
espace entre les narines

# Retina



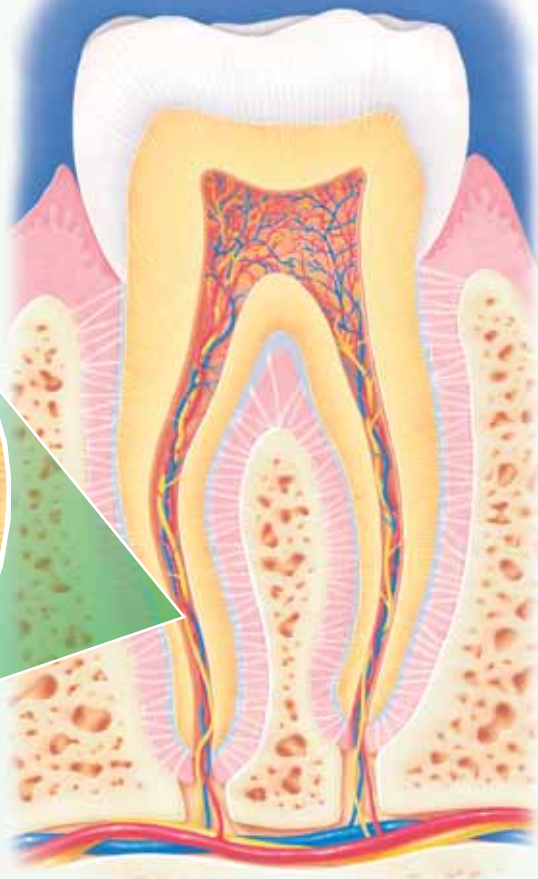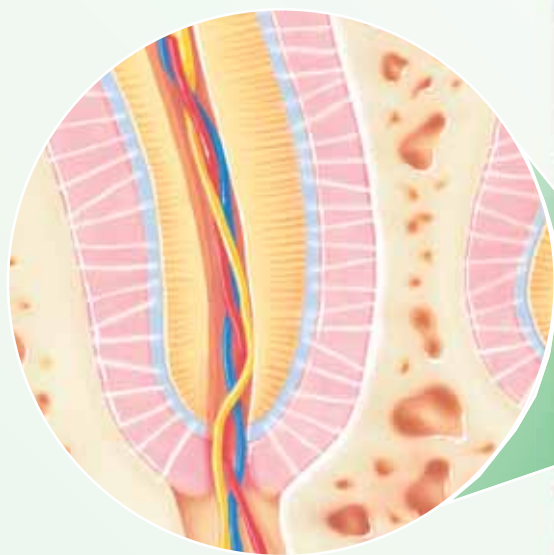
Δῖῑῑ Δῑῑῑῑῑῑῑ

Ijiup ilupaarutanga

Iyip Tautuutaa

Rétine

# Root



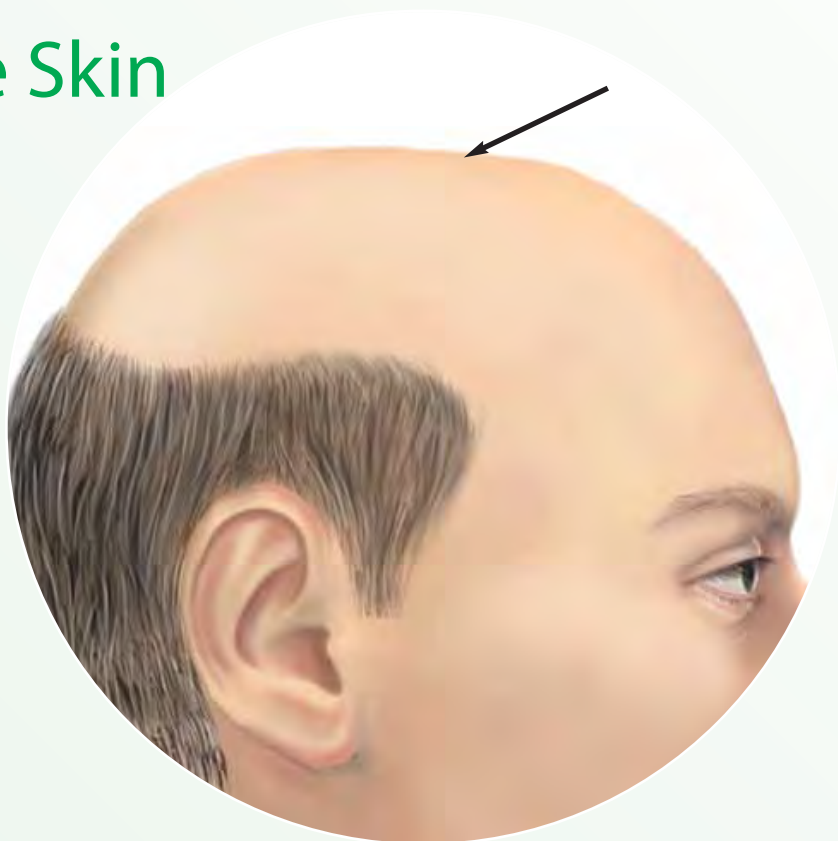
ᄇᄆᄆᄆᄆ

Mannguq

Manngua

Racine

## Scalp, Visible Skin



ᐅᐅᐱᐅ

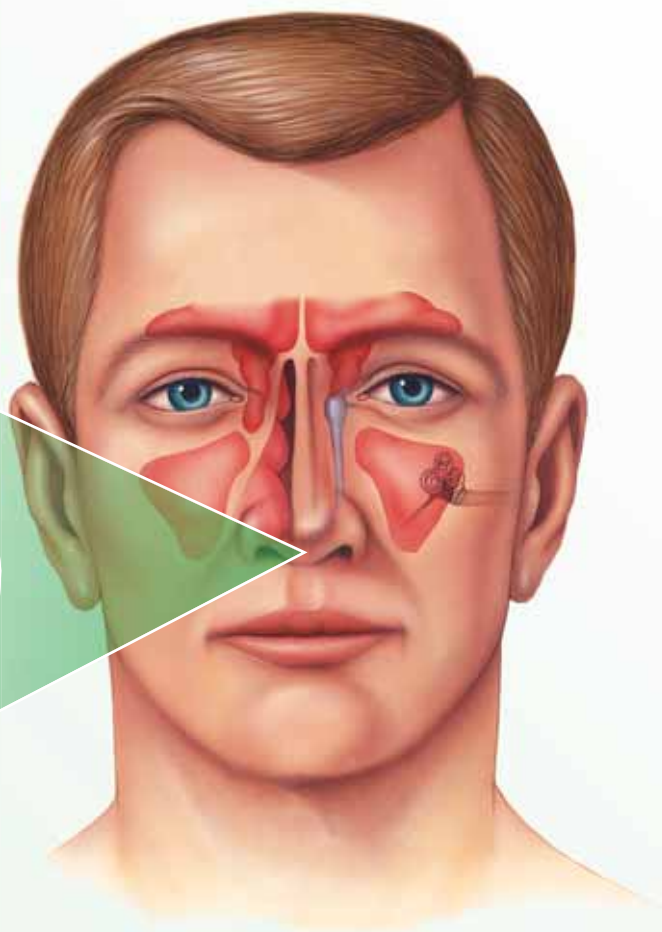
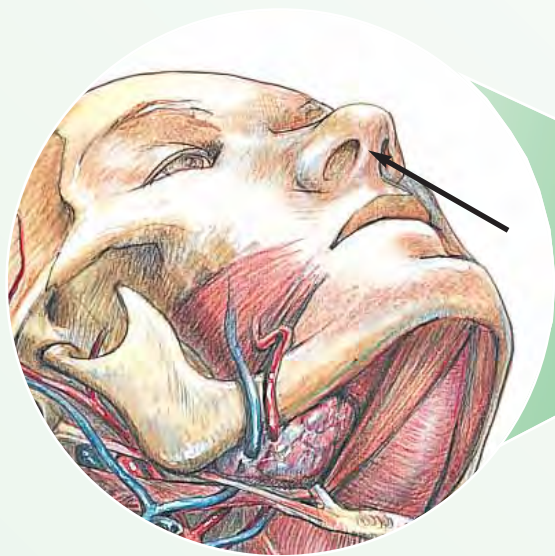
Utuvik

Niaqqup Amia

Cuir chevelu, peau visible



# Septum



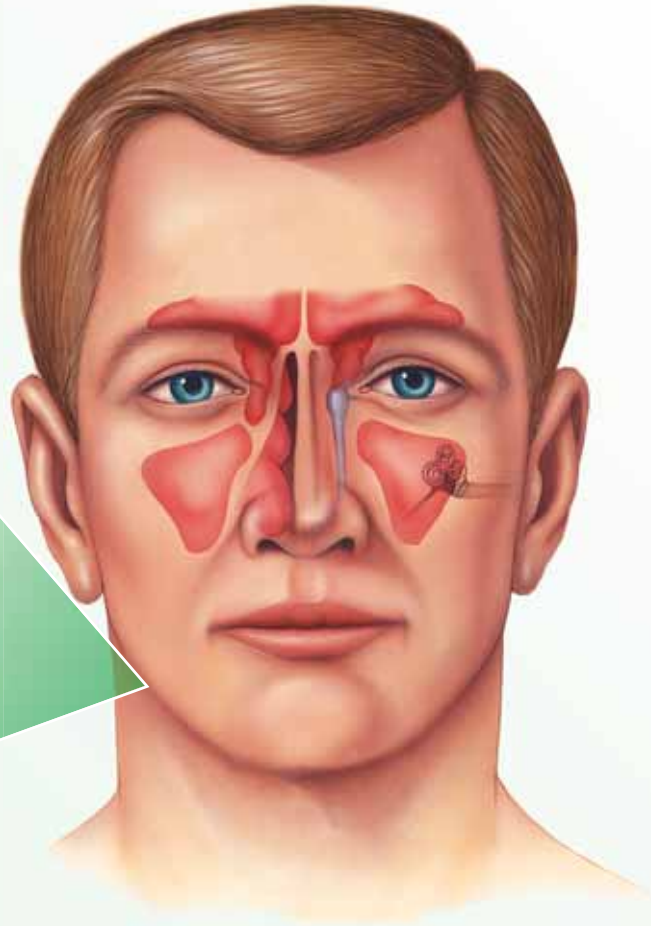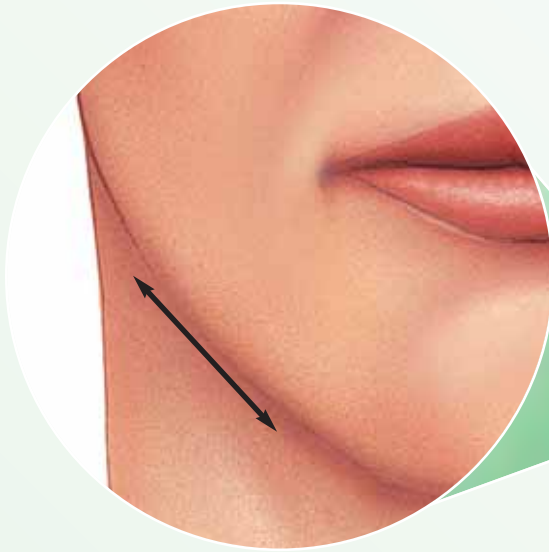
ᐱᑖᑖᐱᑦ ᐱᑖᑖᐱᑦ

Qingaup Nataqqunga

Qaqqulaaq

Espace entre les narines

# Side of the Jaw



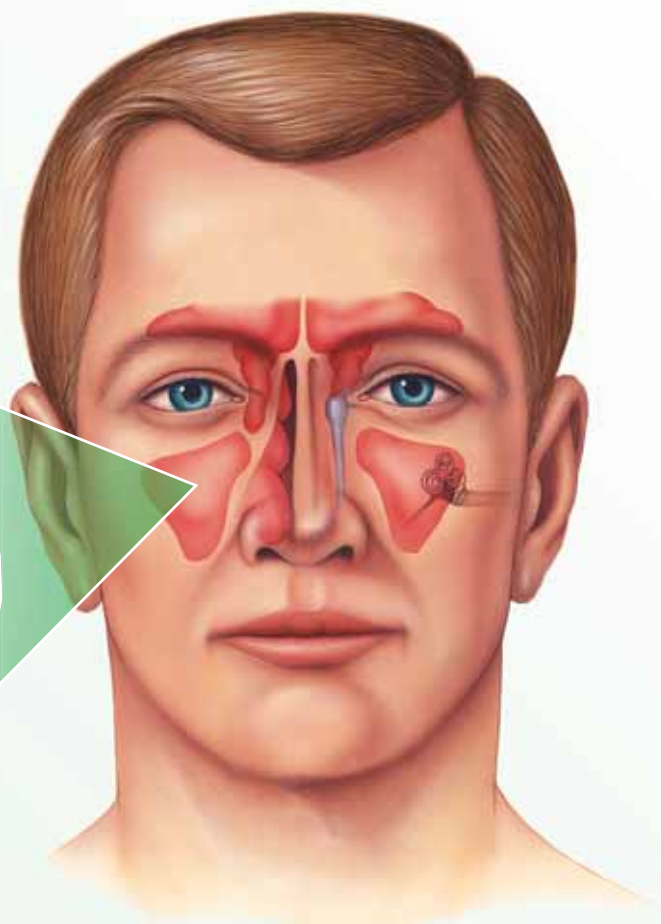
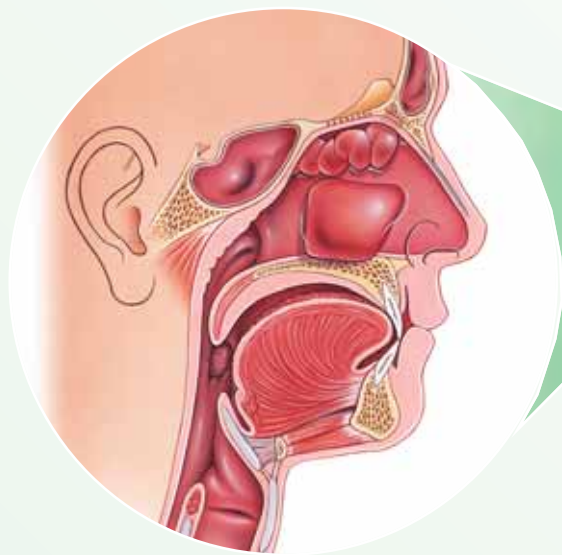ᐃᐃᑦᑲ

Tutaq

Agliruaq

Côté de la mâchoire

# Sinus



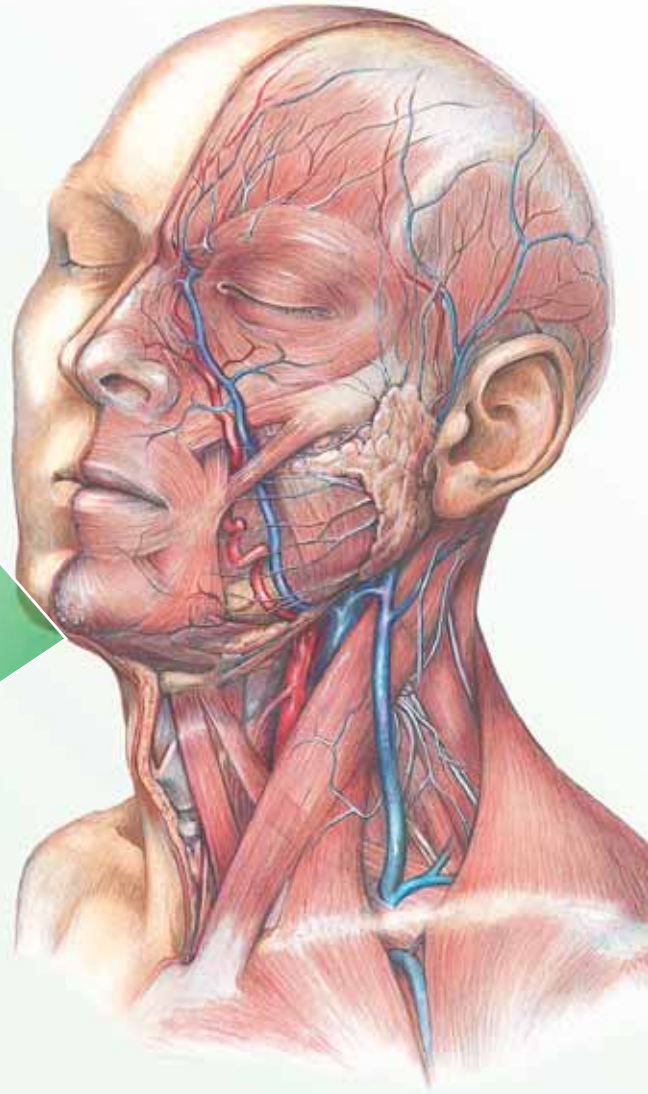
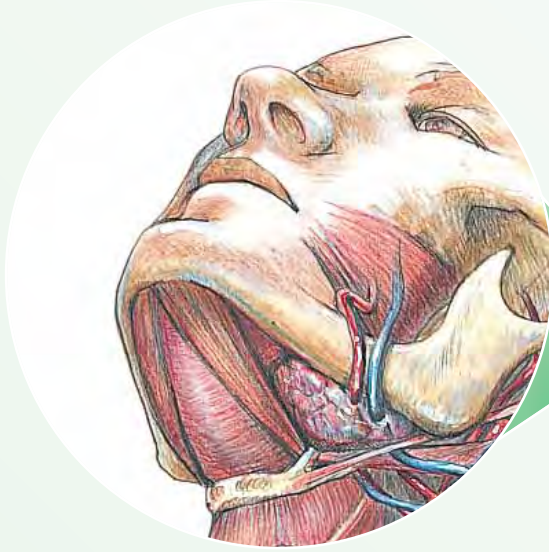
ΔΝῚᐁᐁᐁᐁᐁᐁ

Itiqqirniq

Hurlu

Sinus

# Submental Area



ᠠᠪᠢᠷᠢᠯᠤᠬᠤ

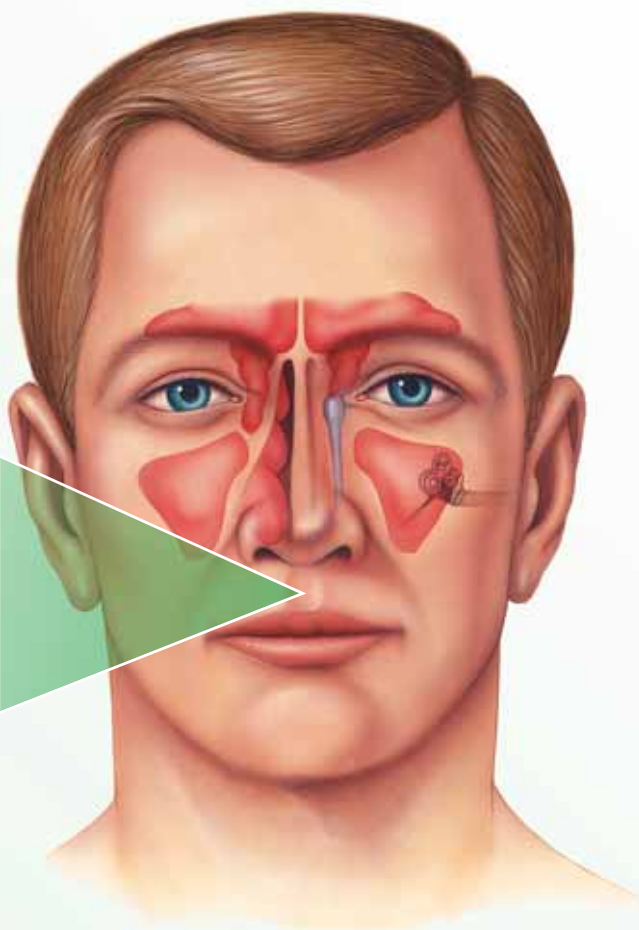
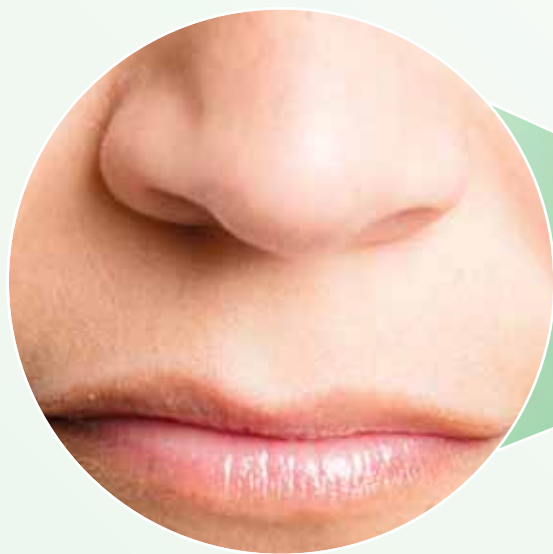Qakirluk

Qakilhuq

Région sous-mentale  
(espace entre menton et cou)



# Subnasal / Nasolabial Groove



Δ 𐌆𐌇𐌈𐌉

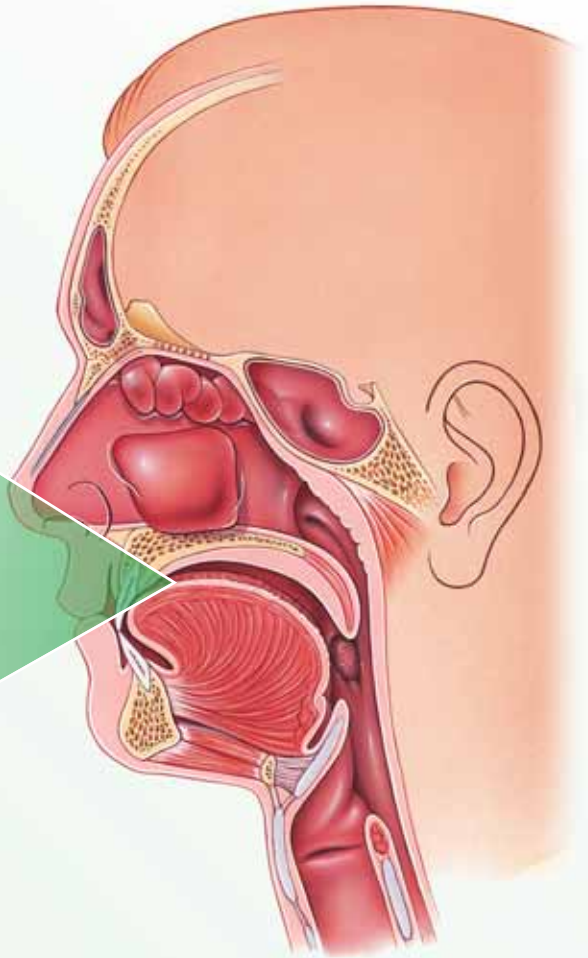
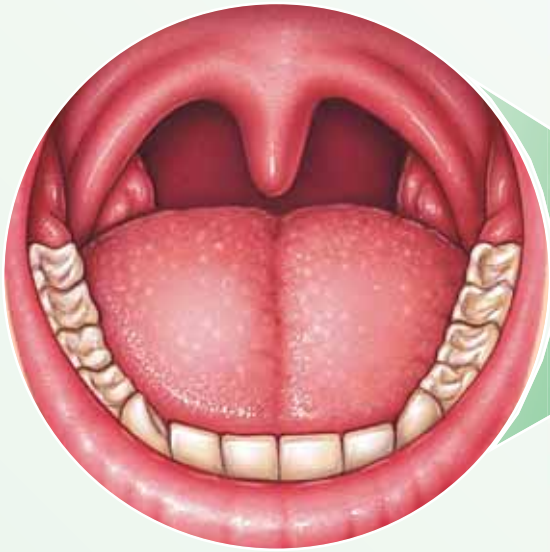Iluqsaq

Kakkiviaq

Silon sub-nasal ou  
naso-labial



# Taste Buds



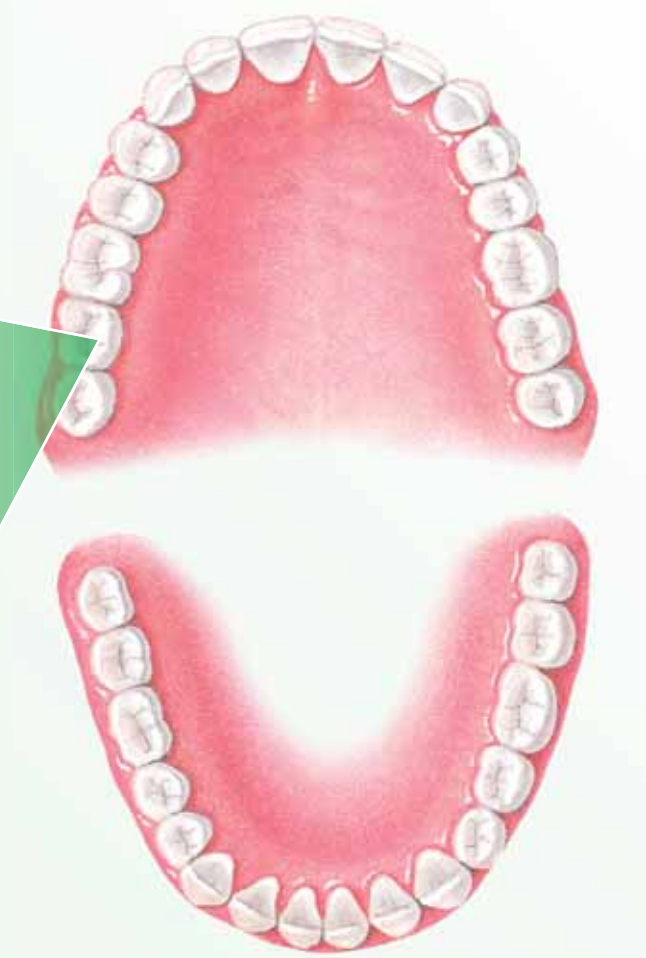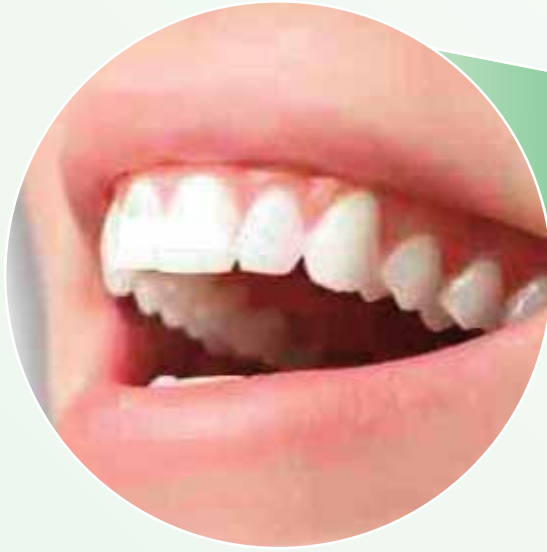▷ᐅᐅᐅᐅᐅ ᐅᐅᐅᐅᐅᐅ

Uqakkut Naimajjutit

Niqinik Ilitaqhidjutit

Papilles gustatives

# Teeth



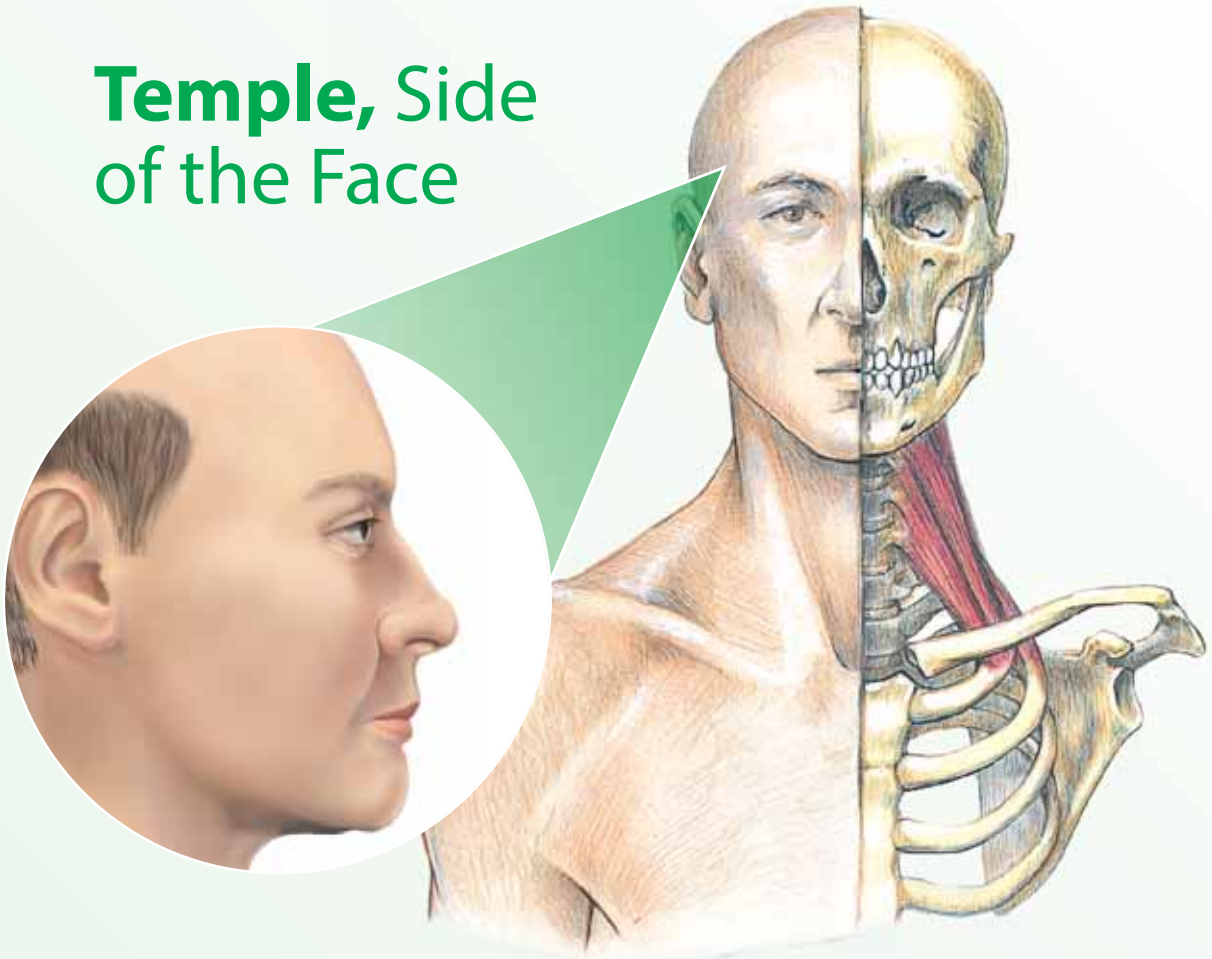
ᐱᐭᐅ

Kigutit

Kigutit

Dents

# Temple, Side of the Face



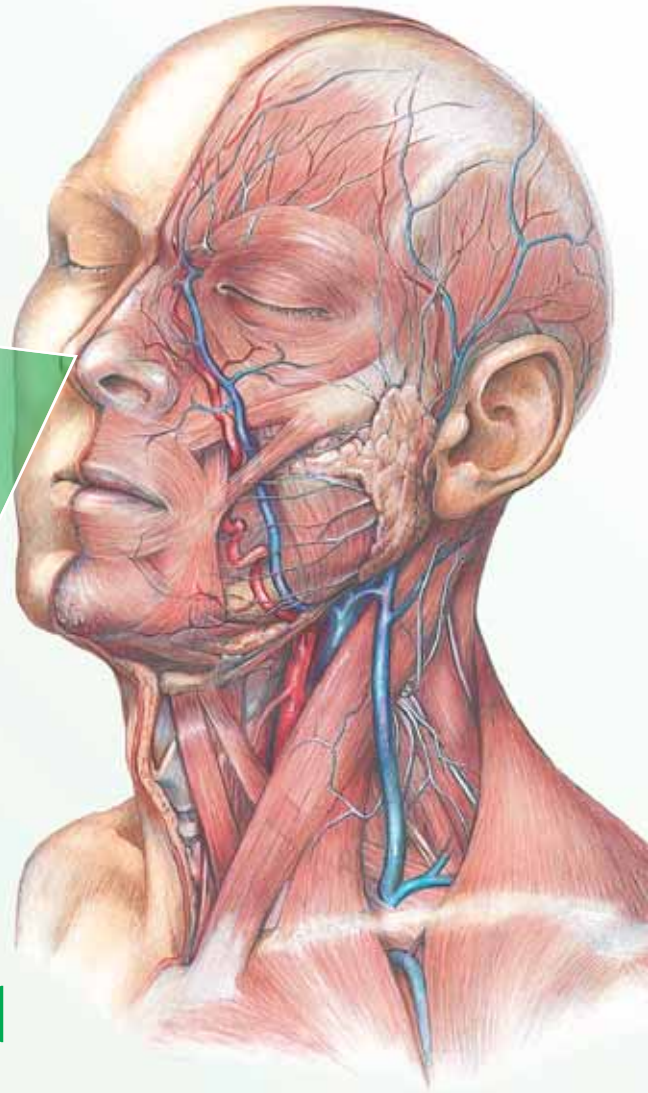
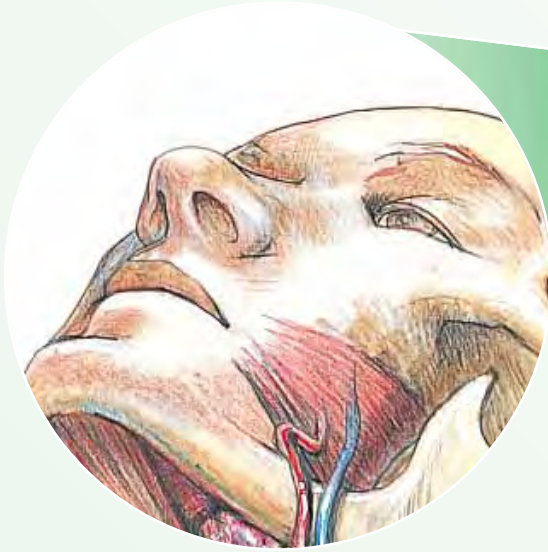Δ ᑭᑲ ᐱ ᑭᑲ

Iqsaq

Tuuttiniq

Tempe, côté du visage

# Tip of the Nose



ᑭᓯᓂᓄᓂ ᓄᓂᓄᓂ

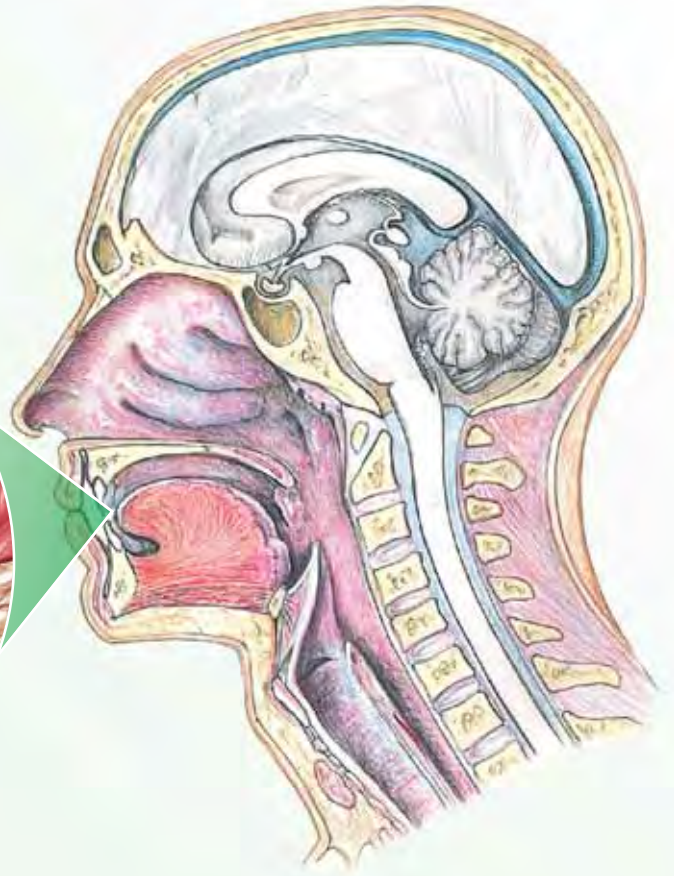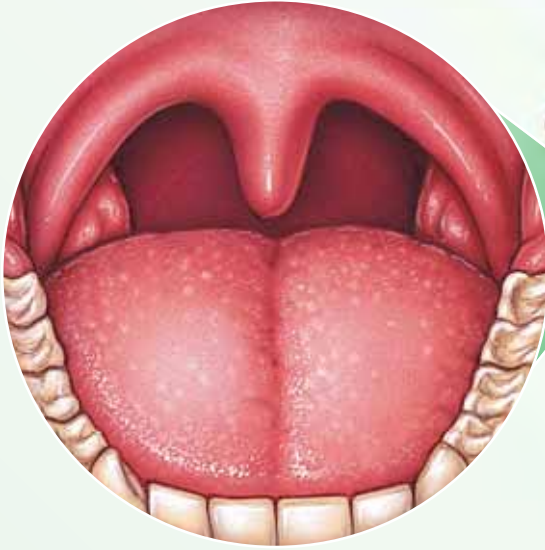
Qingaup Nuvua

Qingaup Nuvua

Pointe du nez



# Tip of the Tongue



ᐅᑦᑲᐅᑦ ᐅᑦᑲᐅᑦ

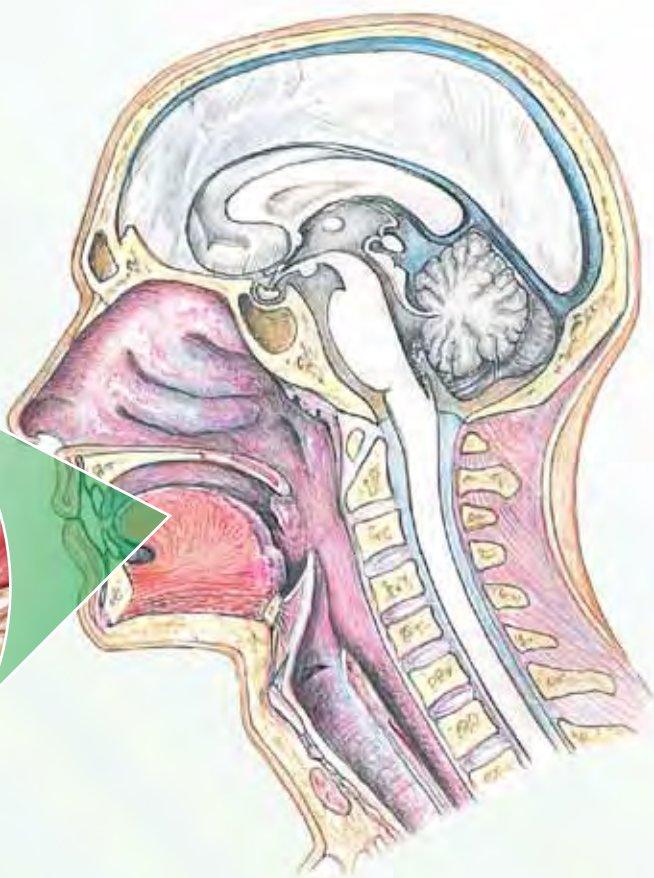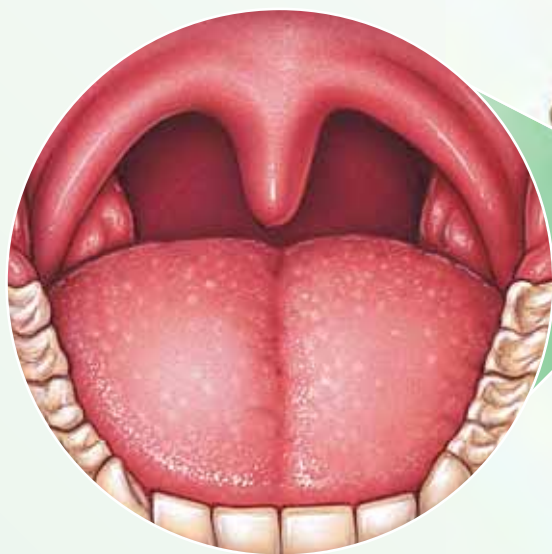
Uqaup Nuvua

Uqqap Nuvua

Pointe de la langue



# Tongue



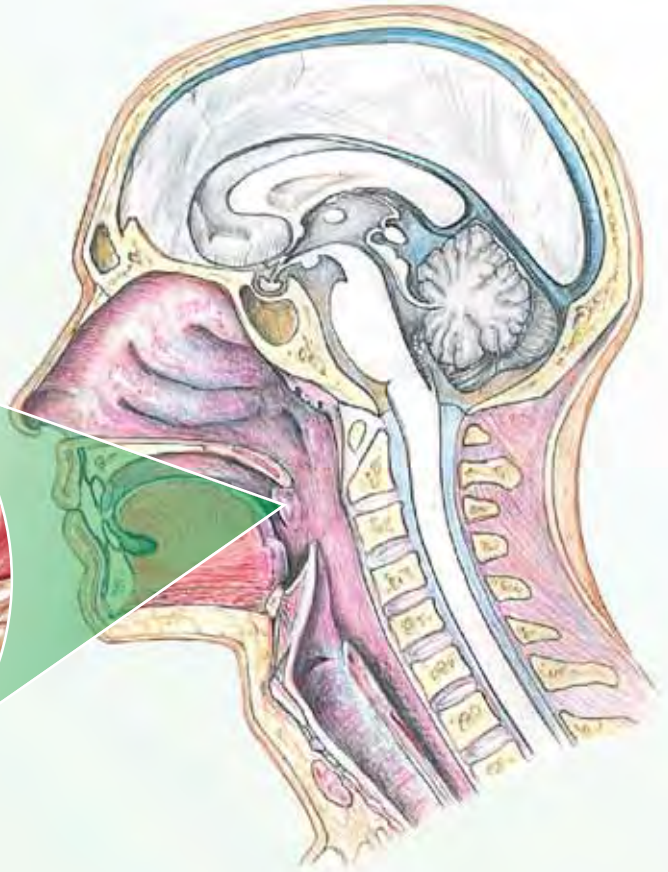
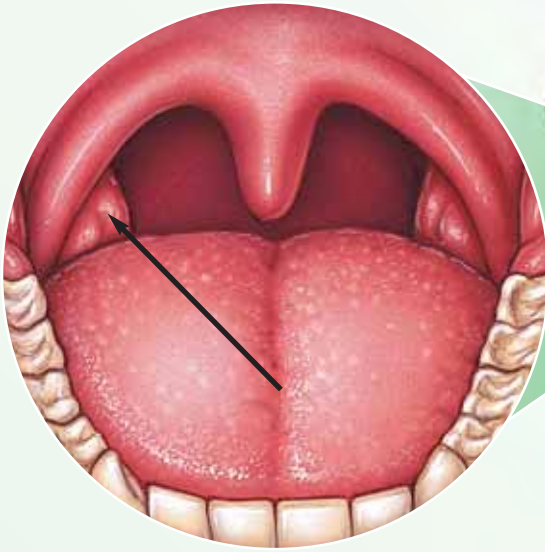
▷ ᄅᄅᄅ

Uqaq

Uqaq

Langue

# Tonsil



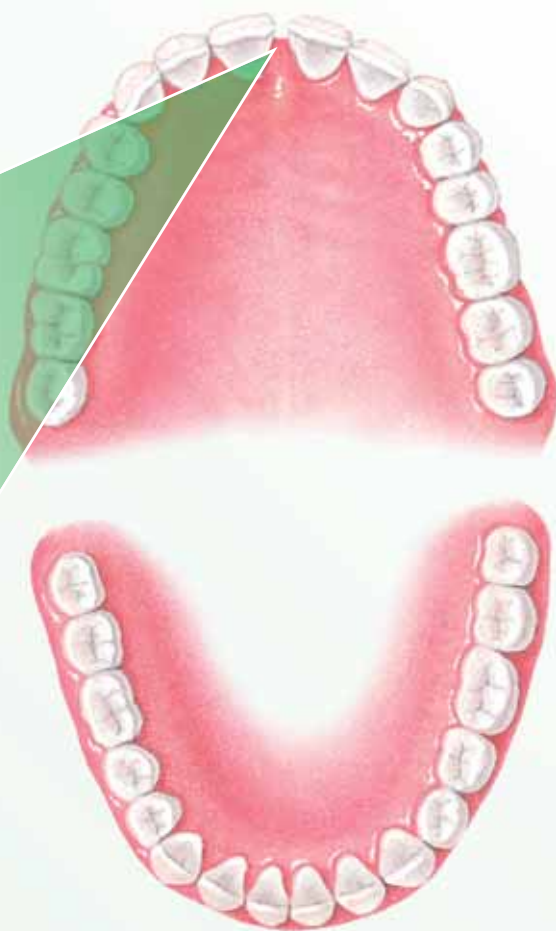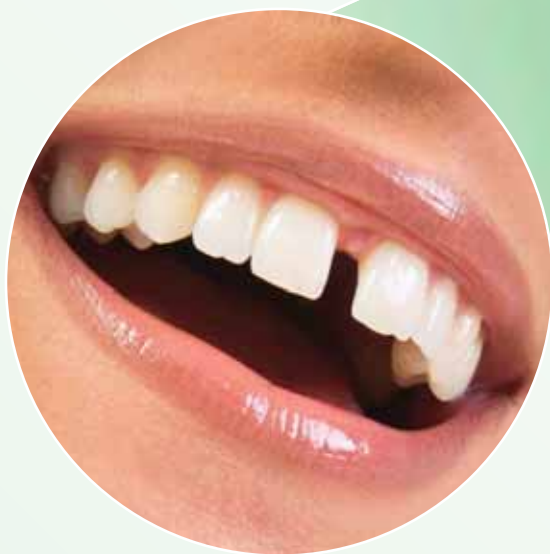ᄎᄎᄎᄎᄎᄎᄎᄎᄎ

Qiliqsinaq

Qiniqhinaq

Amygdale

# Tooth Gap



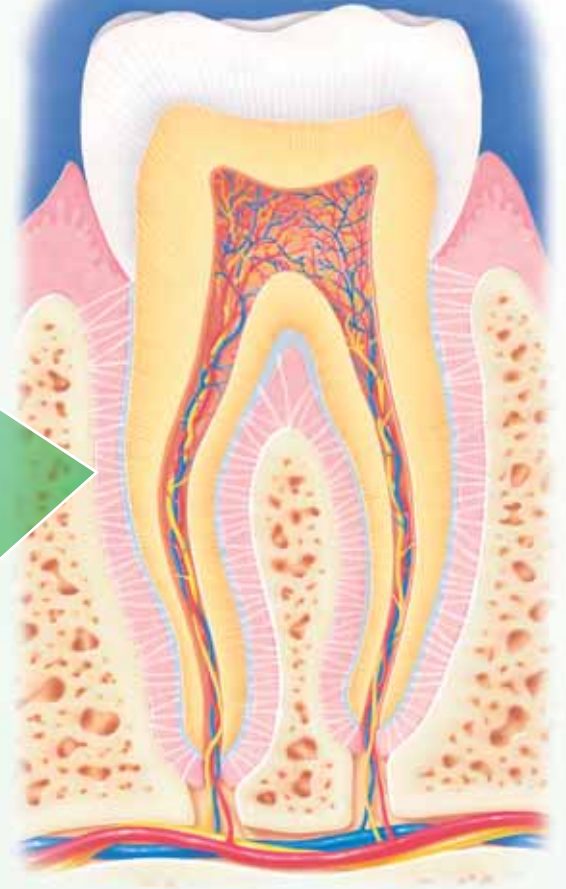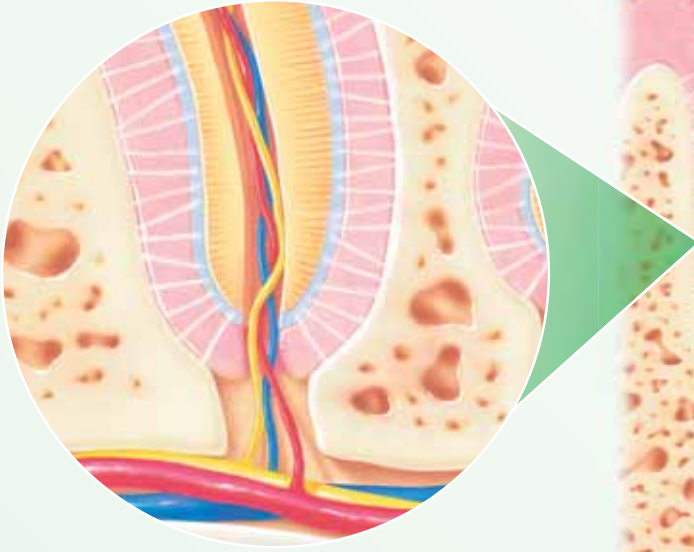
ᐅᐃᐅᐅᐅ

Kinngiq

Kigutip Akutturnia

Absence de dent,  
brèche-dent

# Tooth Socket



ԲՅՈՒՆԳԱԾ

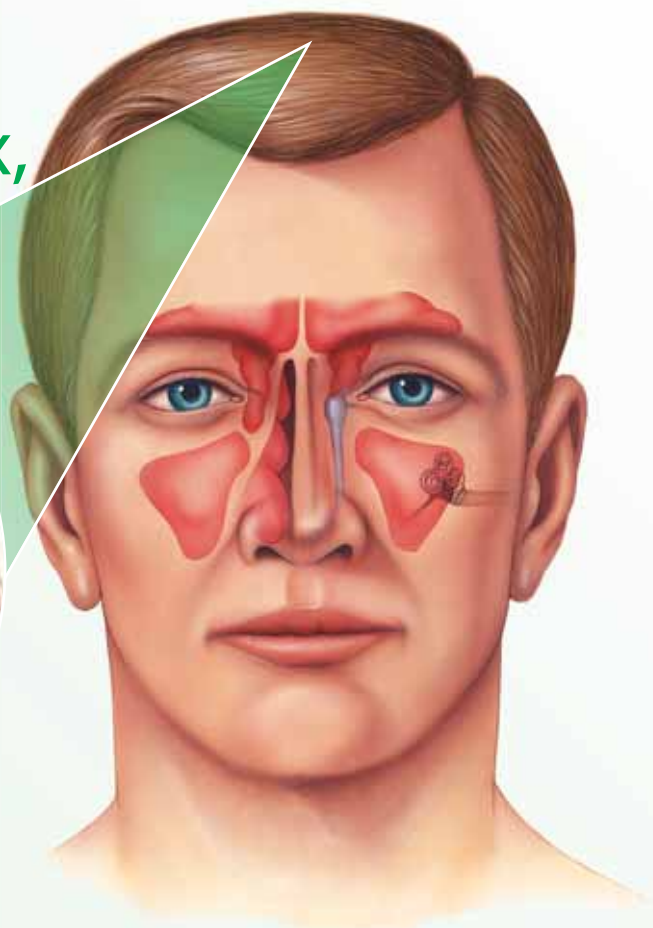Kigutiqarvik

Kigutaiqhirvik

Alvéole dentaire



# Top of the Head / Vertex, Tuft of Hair



бъꞤꞤ

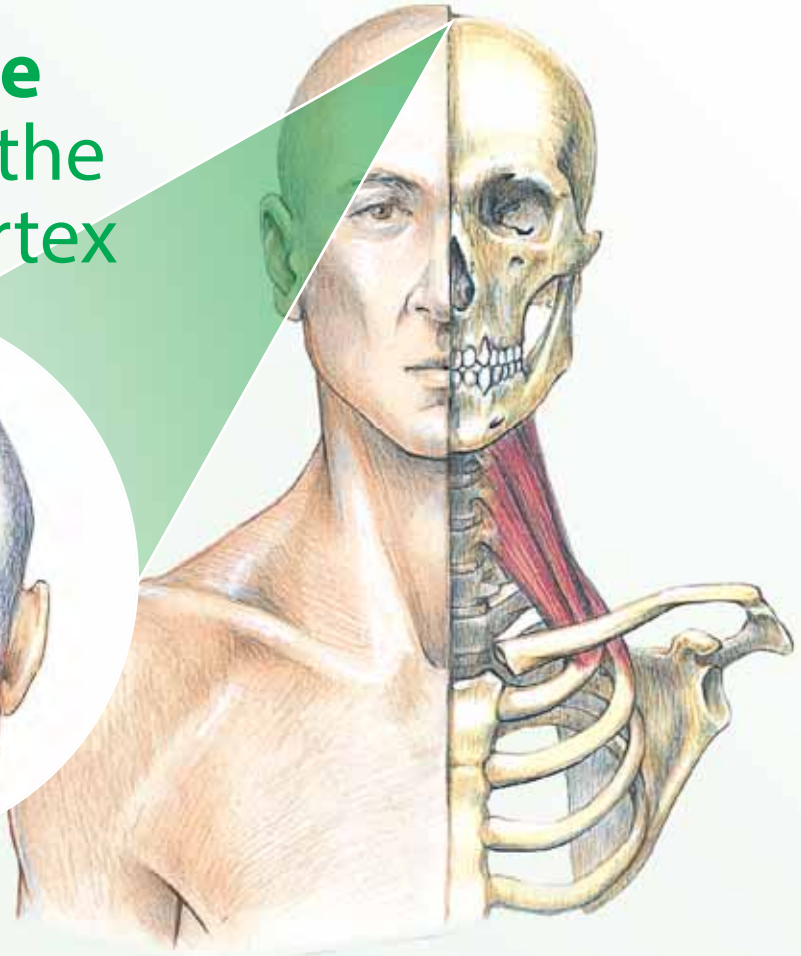
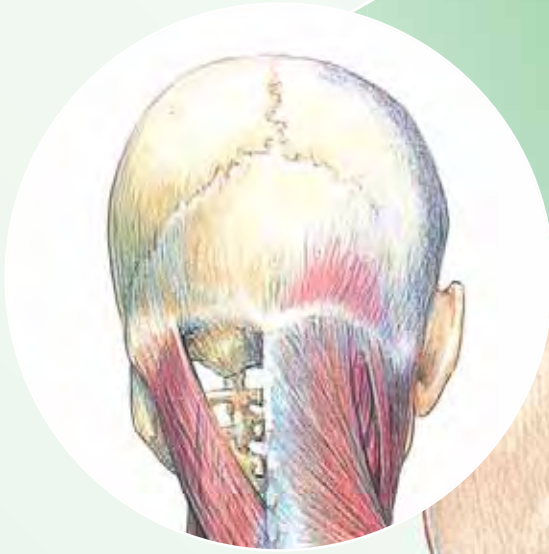Kajjiq

Kaavyiq

Sommet de la tête,  
épi de cheveux



# Top of the Head, of the Skull / Vertex



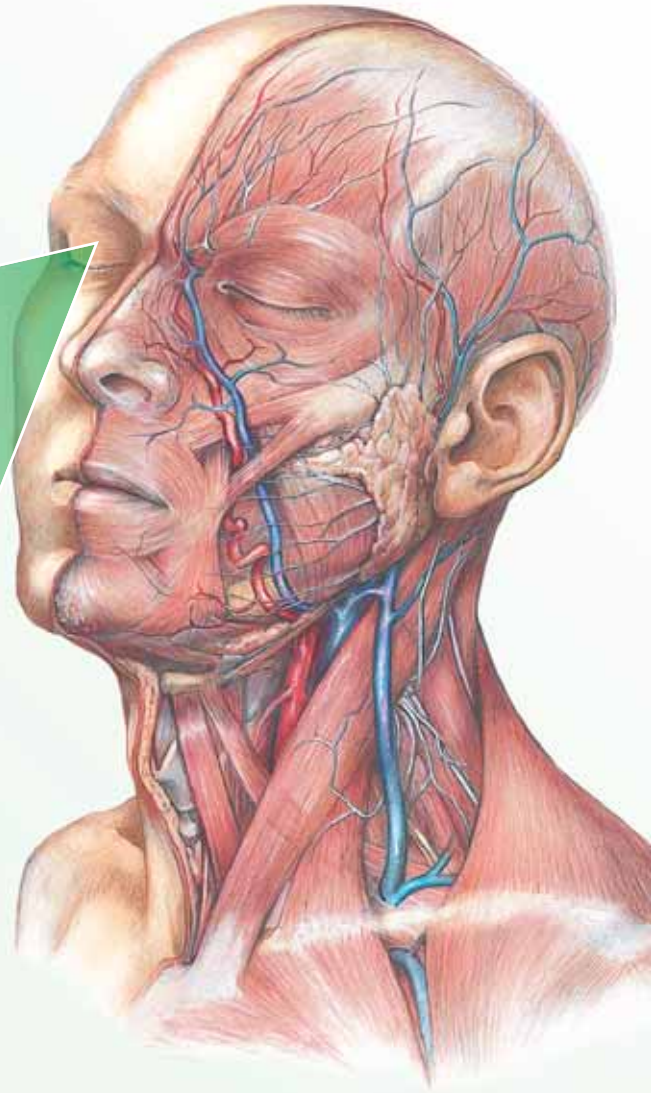
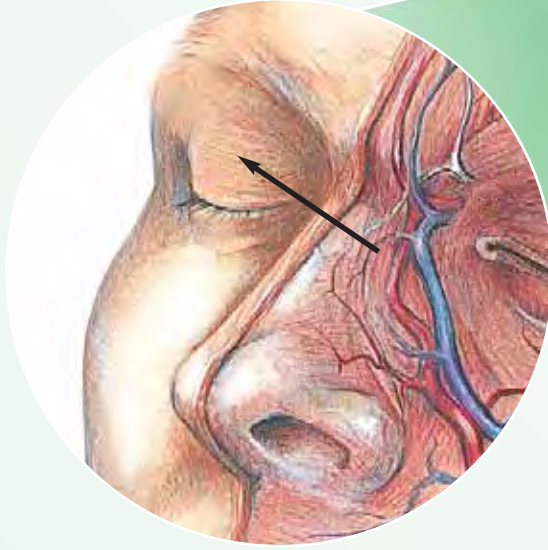ᐱᑲᑲᑦᑲ

Makkaq

Hivu

Sommet de la tête,  
du crâne

# Upper Eyelid



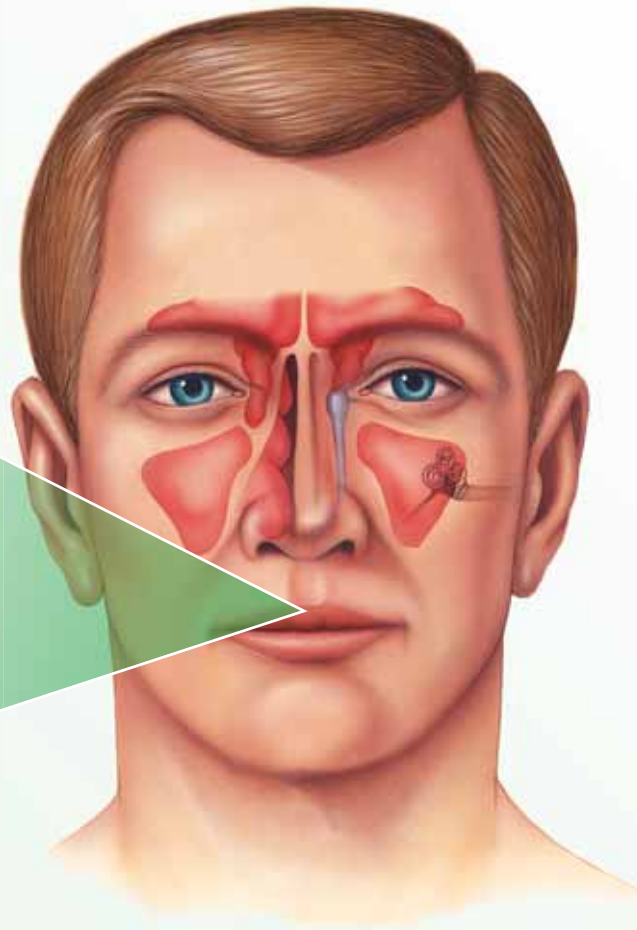
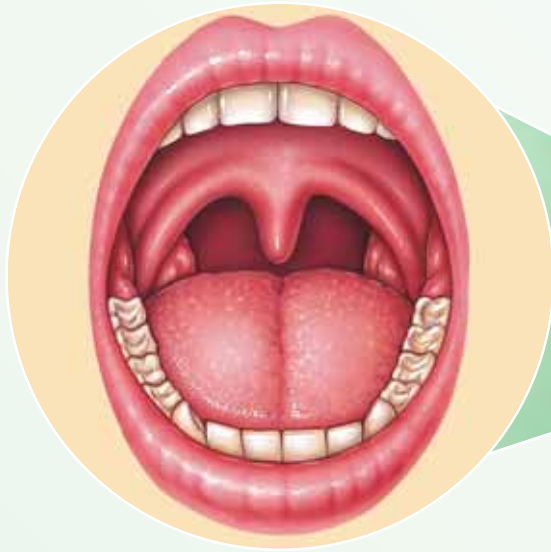ᲒᲞᲠᲚ

Punngati

Qablunak

Paupière supérieure

# Upper Lip / Inside of the Lower Lip



ᑭᑦᑲᑦᑲᑦᑲᑦᑲᑦ

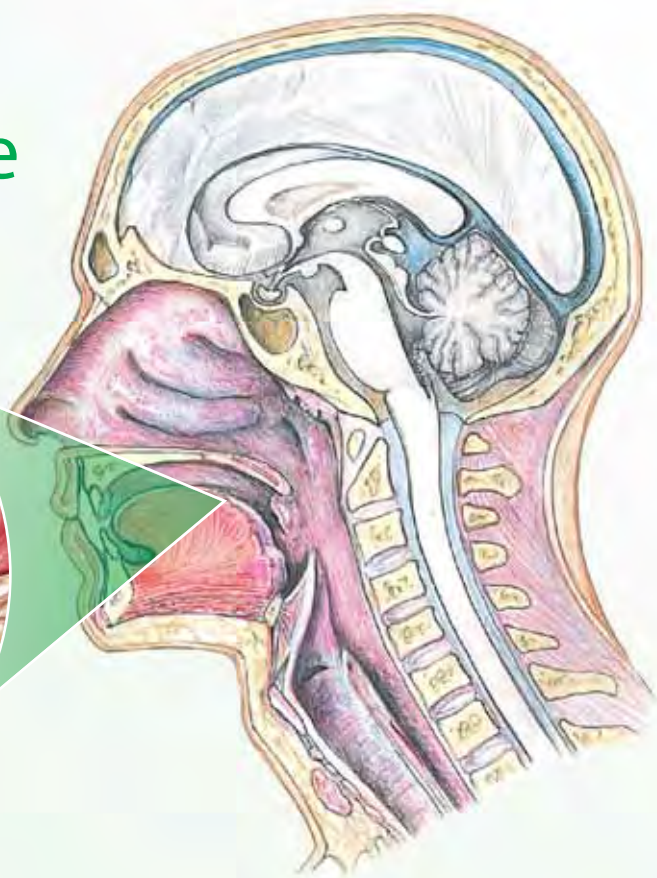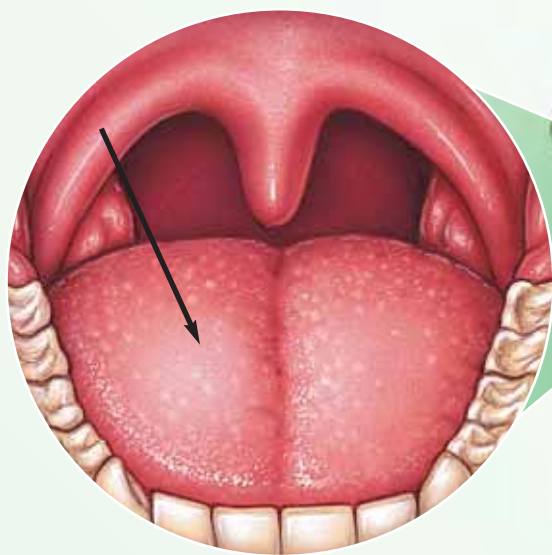
Qarngasinaaq

Umilruq

Lèvre supérieure /  
intérieur de la lèvre  
inférieure



## Upper Side of the Tongue



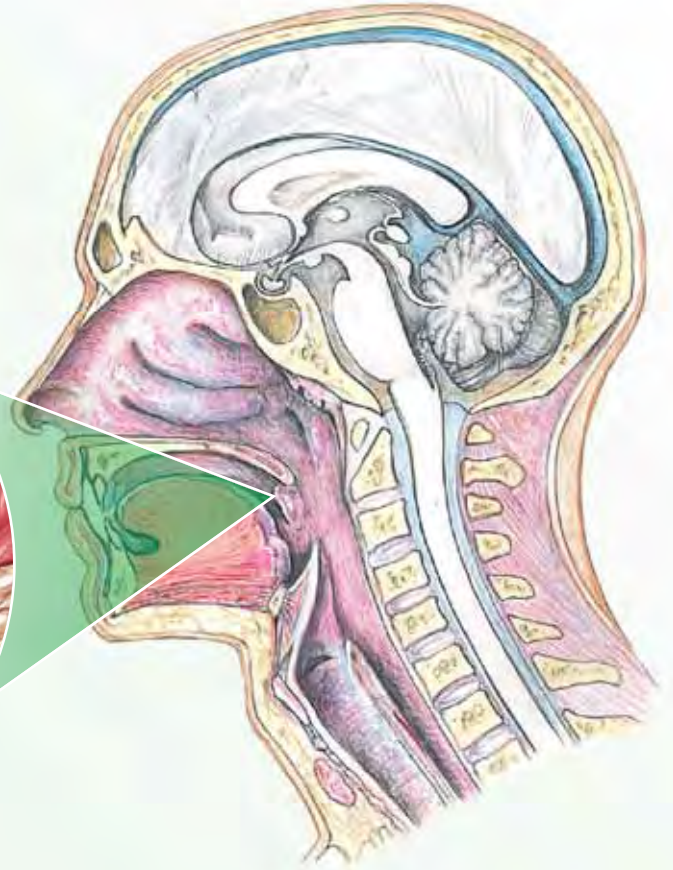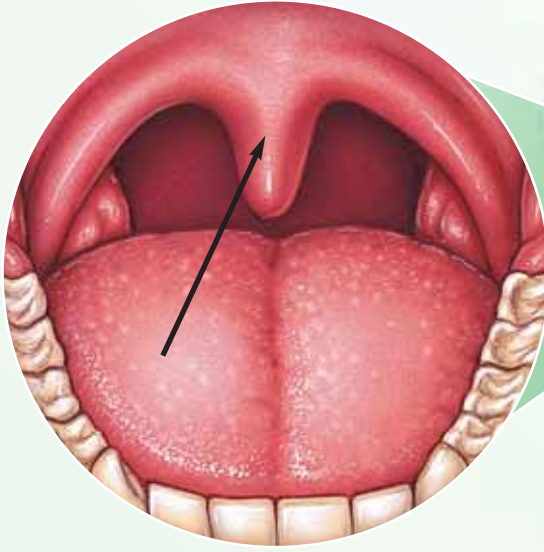
▷ᑦᑲ▷ᑦ ᑦᑲᑦᑲ

Uqaup Qaanga

Uqqap Qaanga

Face supérieure de la langue

# Uvula



σῦλῶν

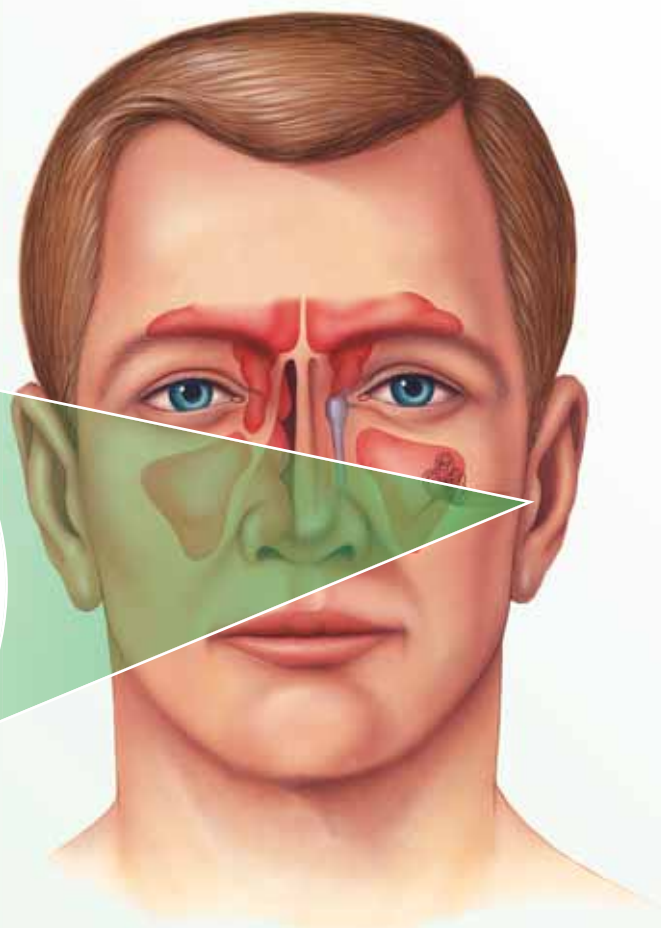
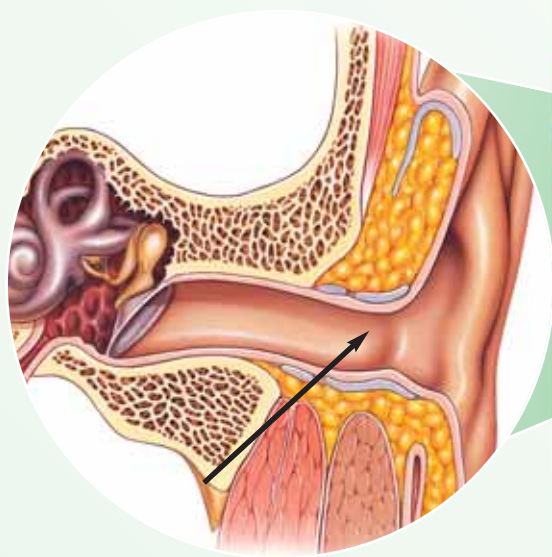Niriliktaq

Niriliktaq

Lulette



# Vestibule



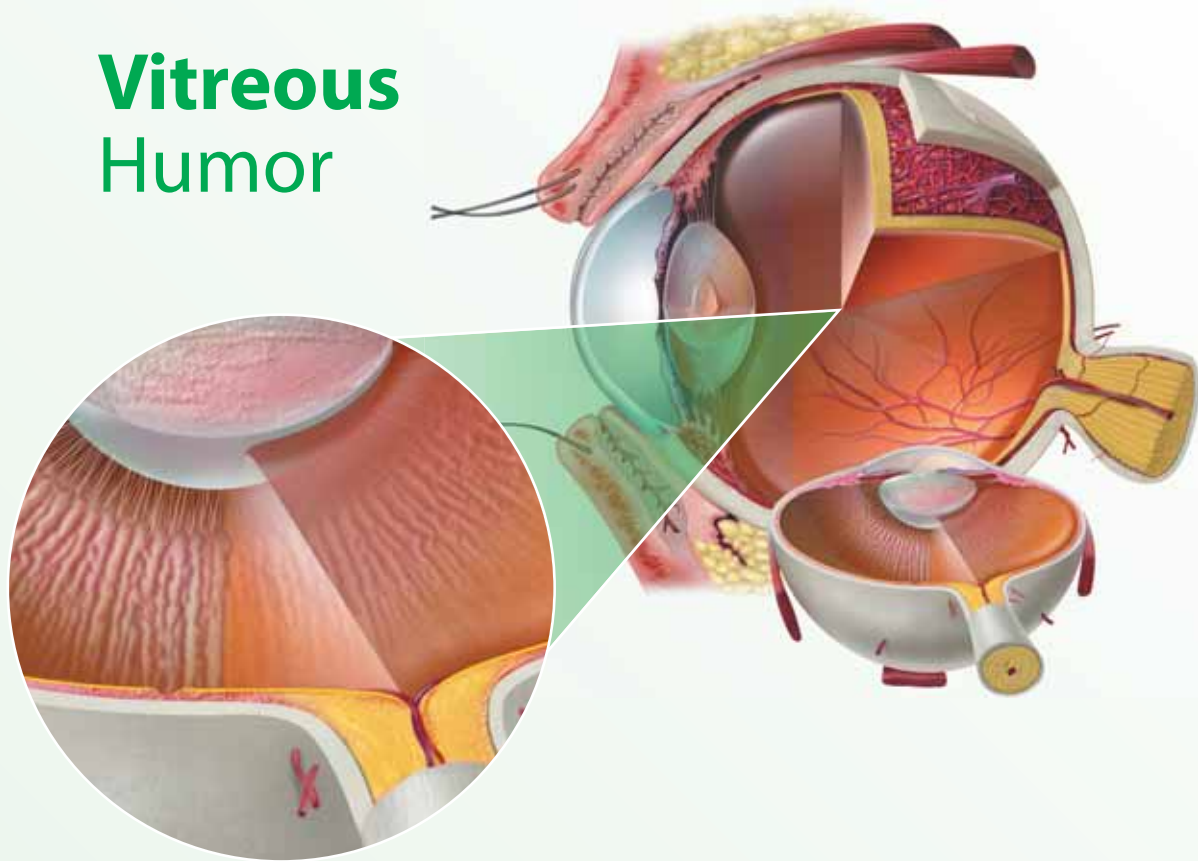
ᑯᑦᑲᑲᑲᑲᑲᑲ

Naliqqariigut

Hiutip Tuhaadjutaa

Vestibule

# Vitreous Humor



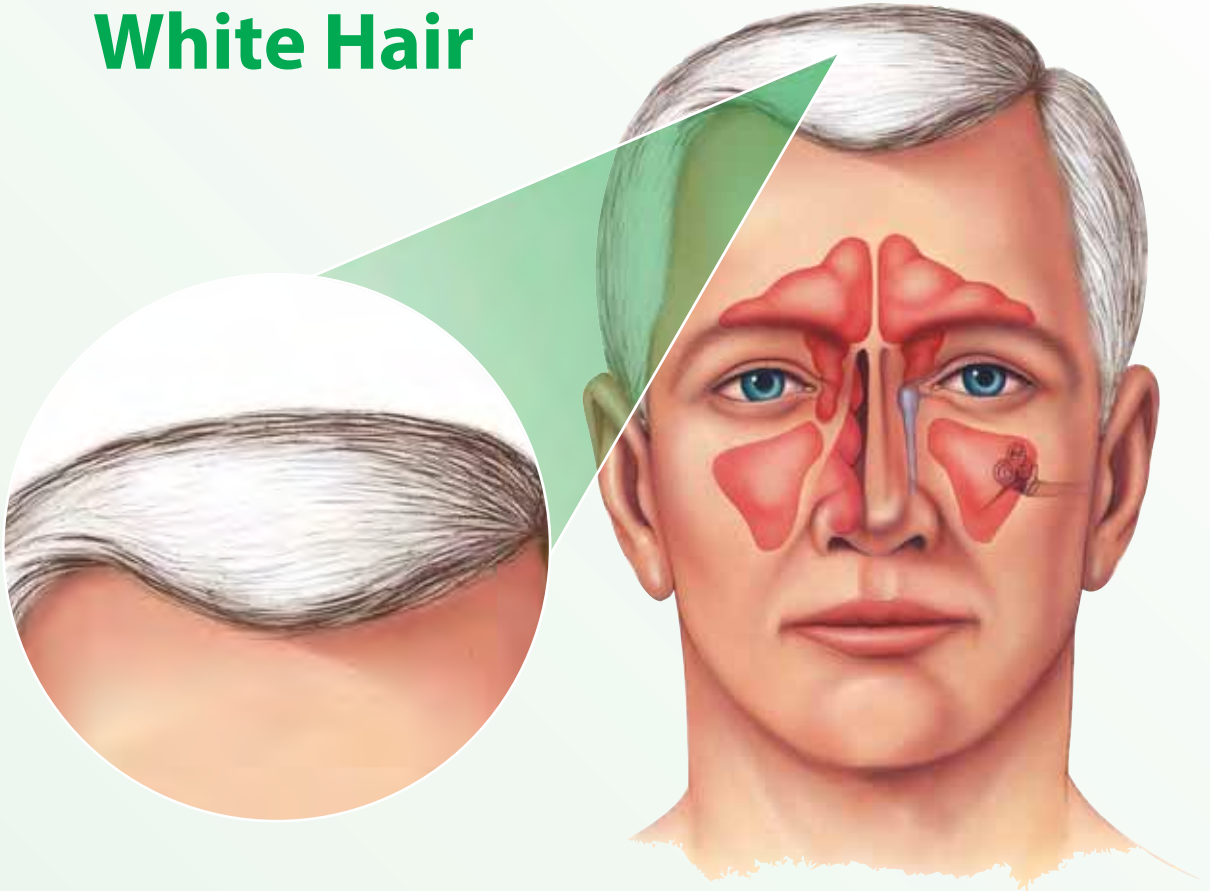ΔΡΔ< ΔL°J

Ijiup Imanga

Iyip Imaqutaa

Corps vitré

# White Hair



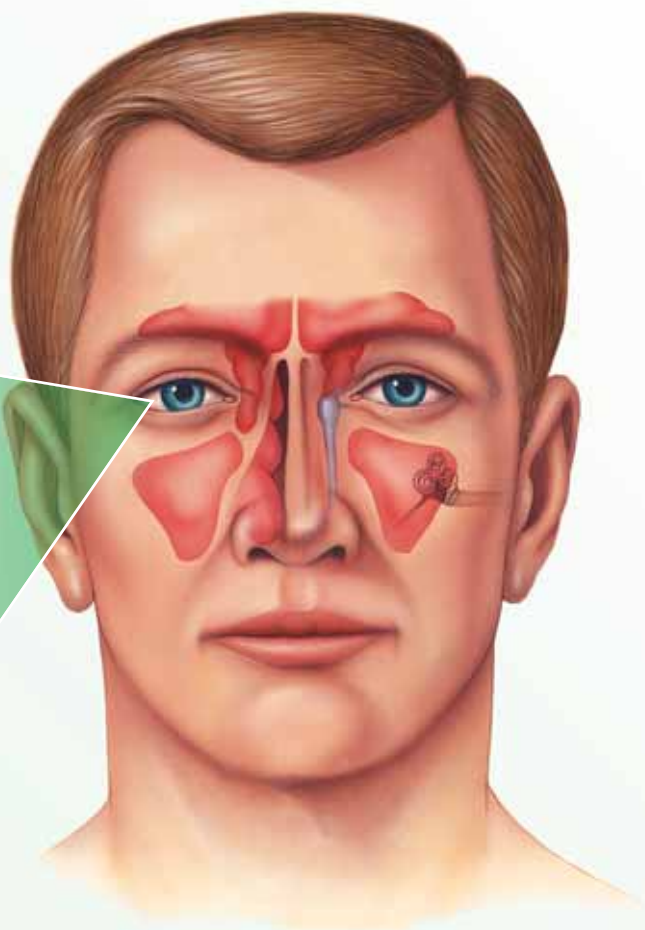
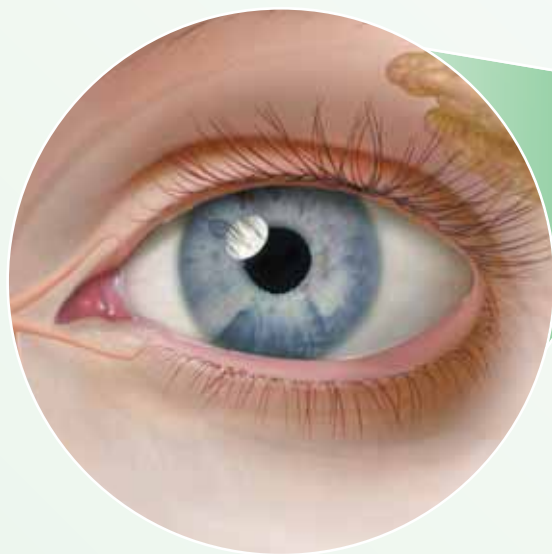
᠑ᠢᠢᠴ

Qiiq

Qiiq

Cheveu blanc

# White of the Eye



ᑦᑯᑦ ᑦᑯᑦ ᑦᑯᑦ

Quviqsaq

Quviqhaq

Blanc de l'œil





# Muscles

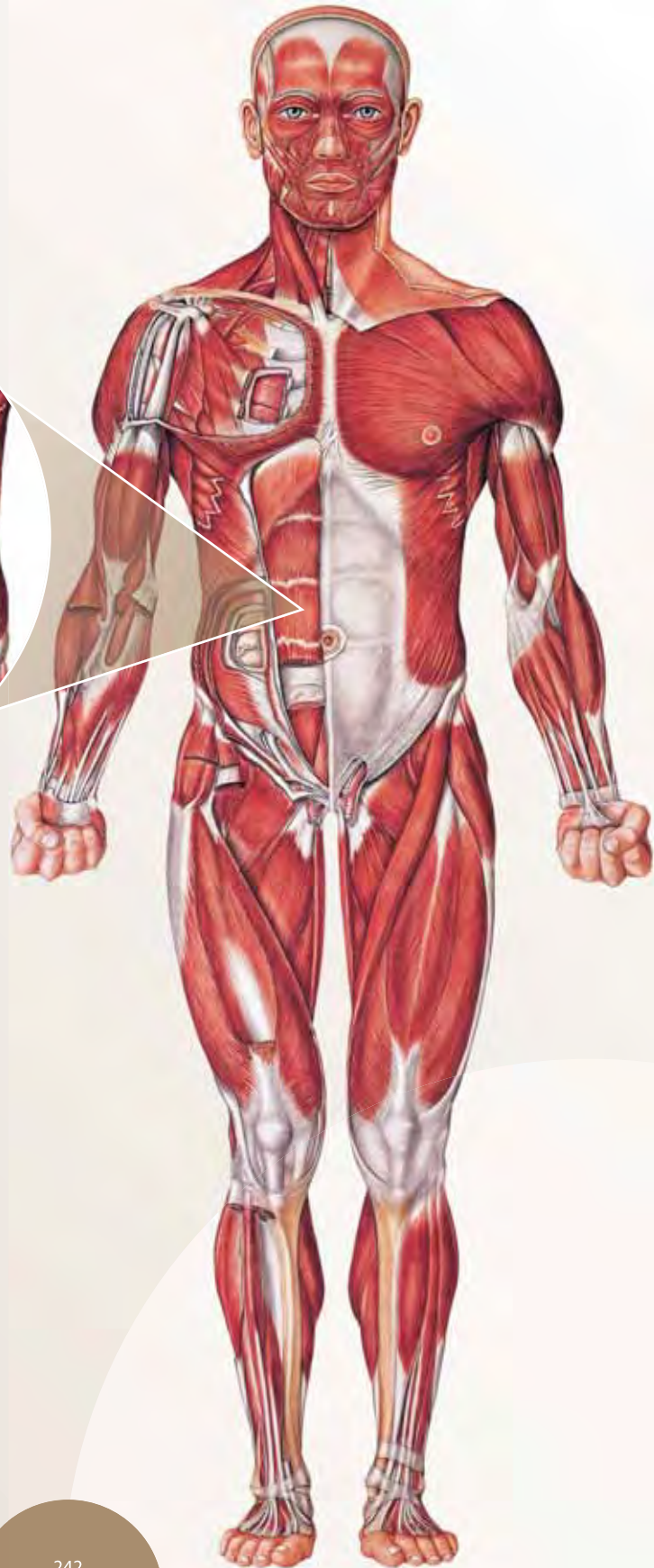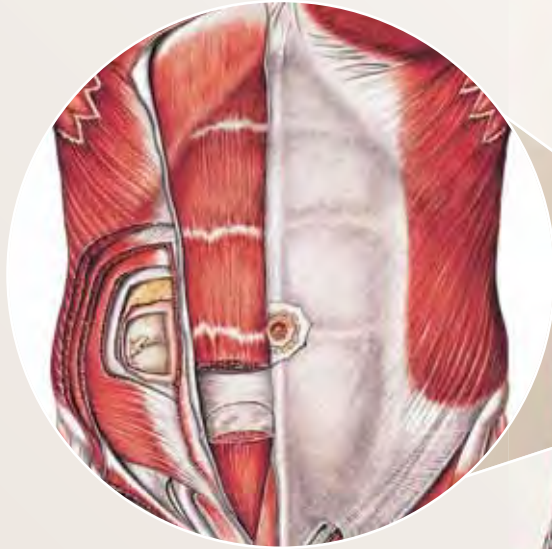
ᓃᓱᓴ

Nukiit

Nukik

Muscles

# Abdominal Muscle



نافه

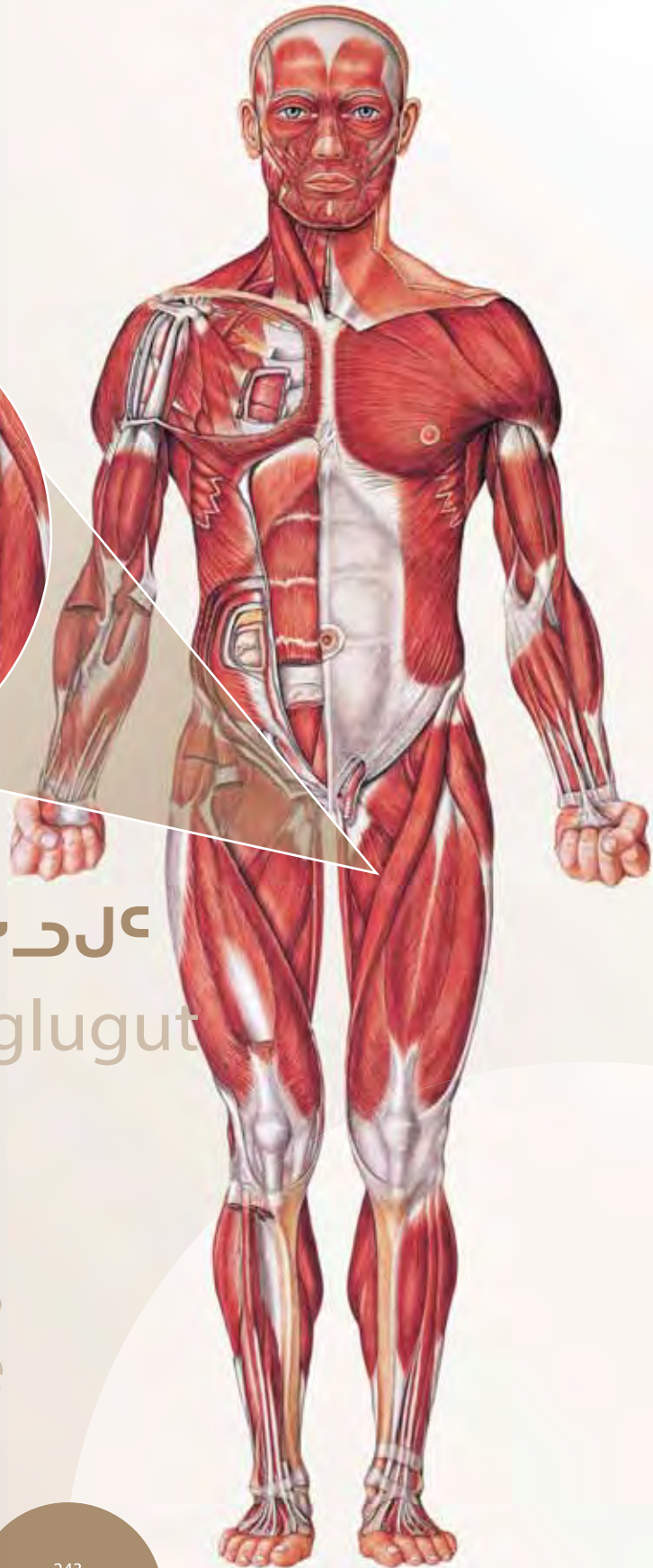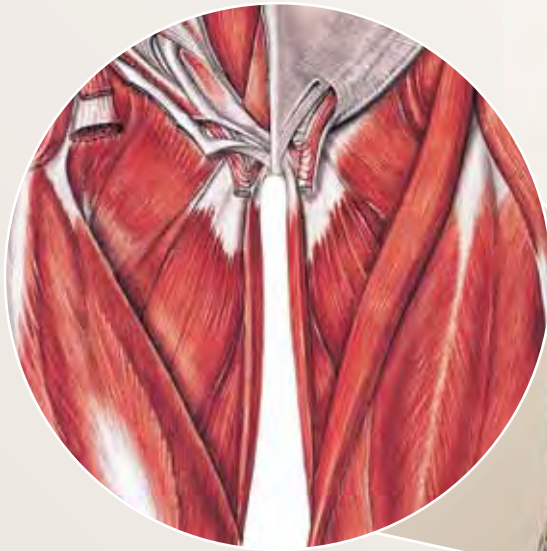
Naarlugut

Naarlugut

Muscle

abdominal

# Adductor Muscles of the Thigh



ᑎᑦᑎᑦᑎ ᑎᑦᑎᑦᑎ ᑎᑦᑎᑦᑎ  
Nukik Ilutaglugut  
Ilutak  
Muscles  
adducteurs  
de la cuisse

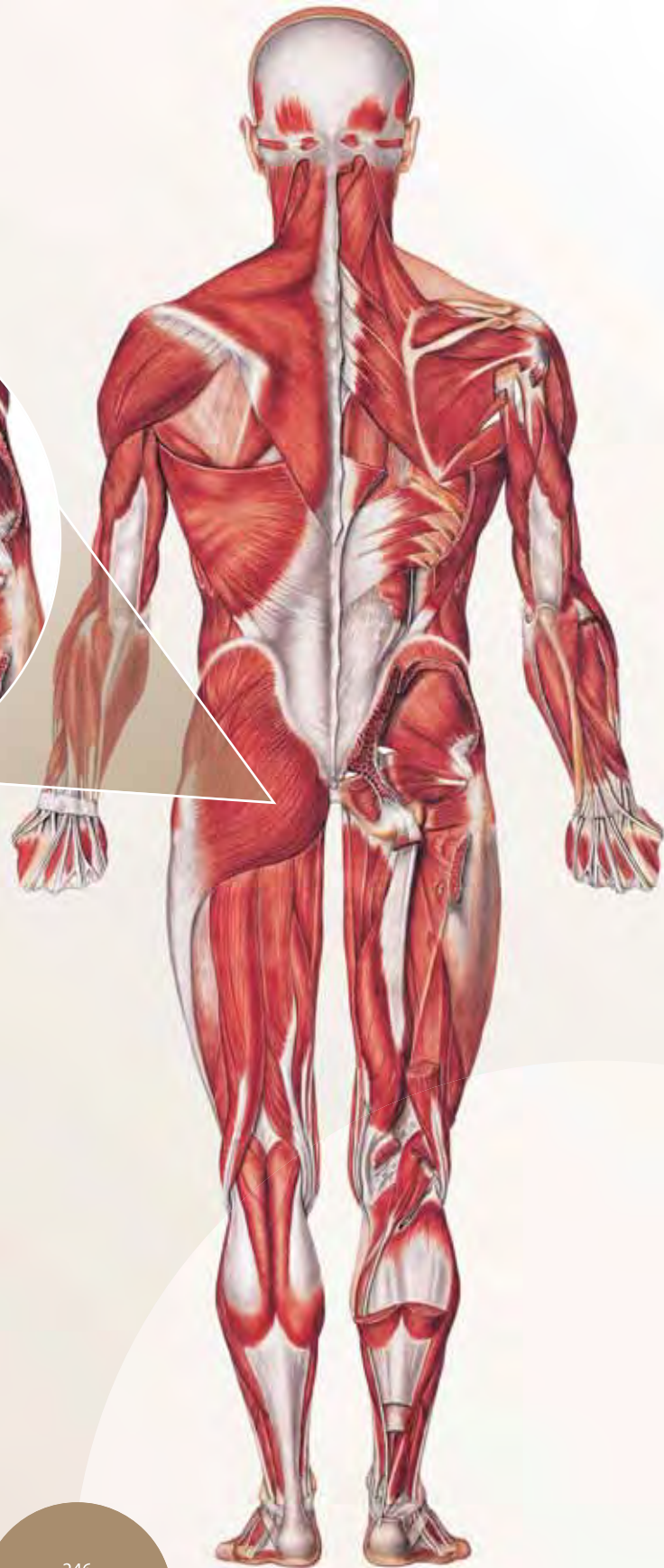
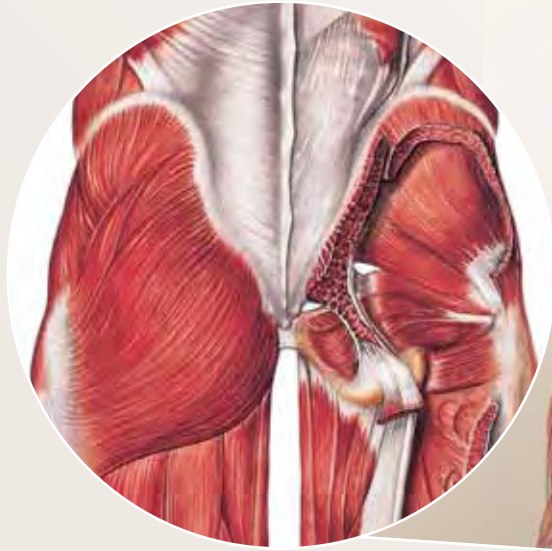








# Buttocks



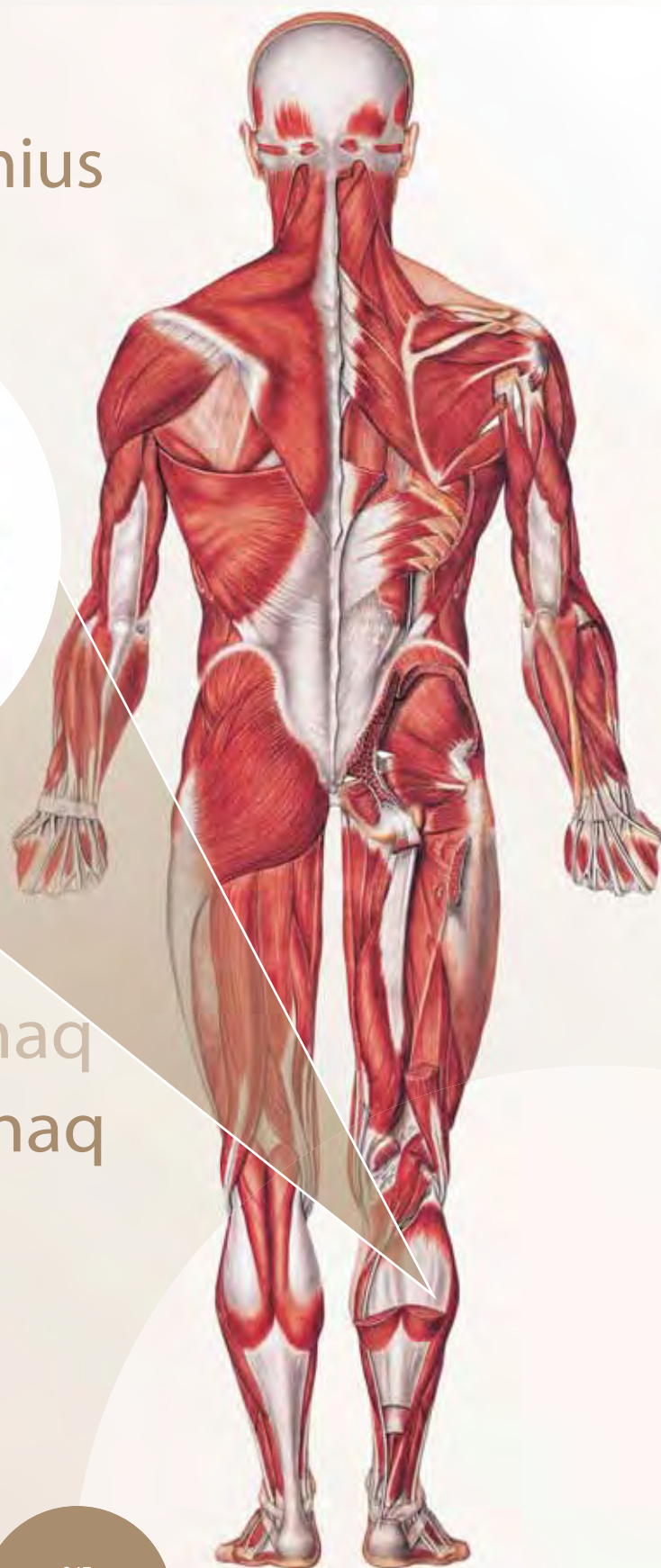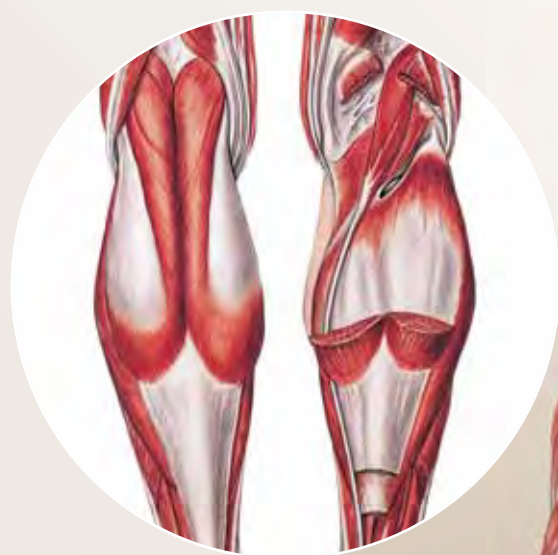▷ᐆ<ᐅᐆ

Ukpatiik

Ukpatik

Fesses

# Calf / Gastrocnemius Muscle



ᄒᄒᄒᄒᄒᄒ

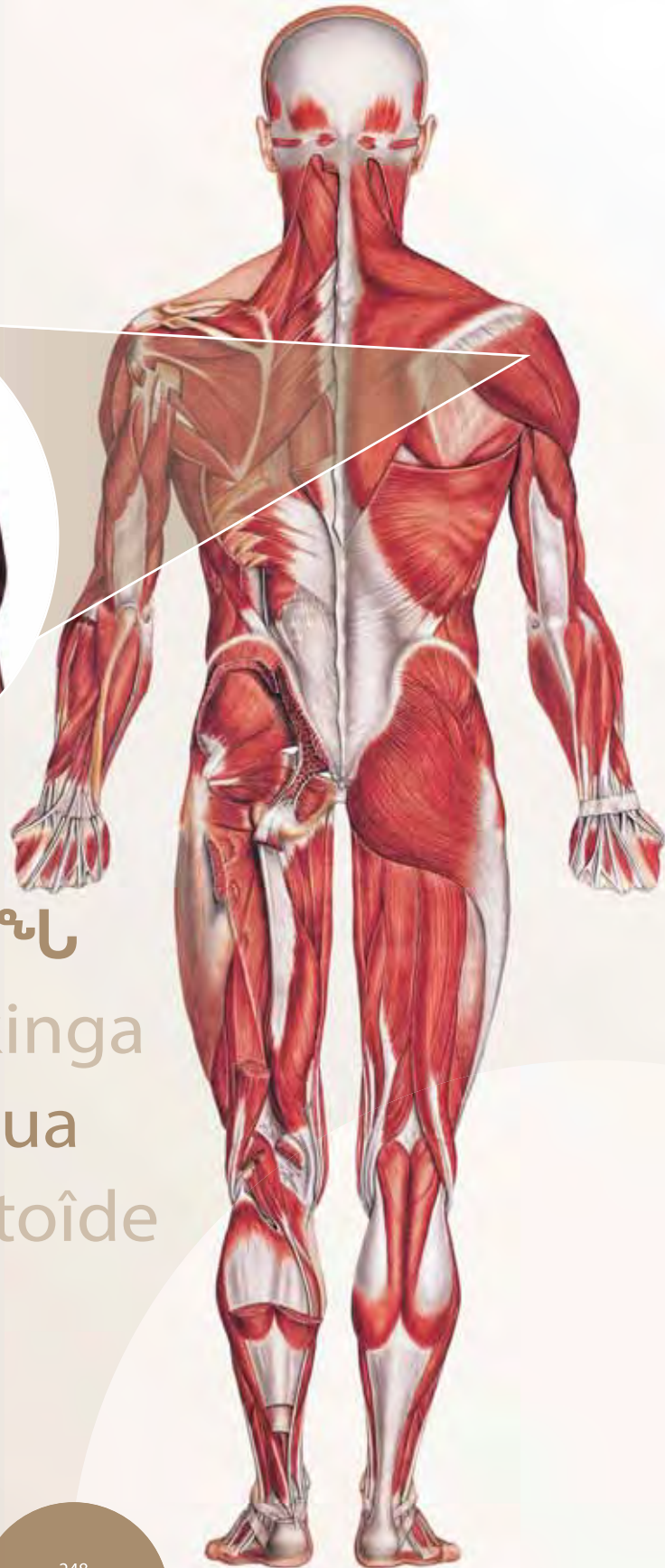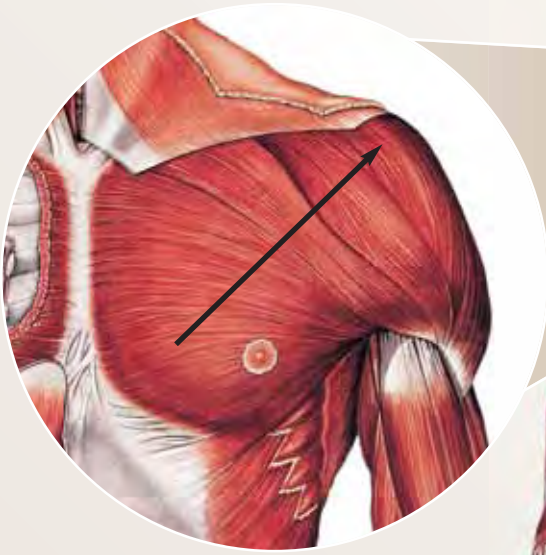
Nakasungnaq

Nakahungnaq

Mollet



# Deltoid Muscle

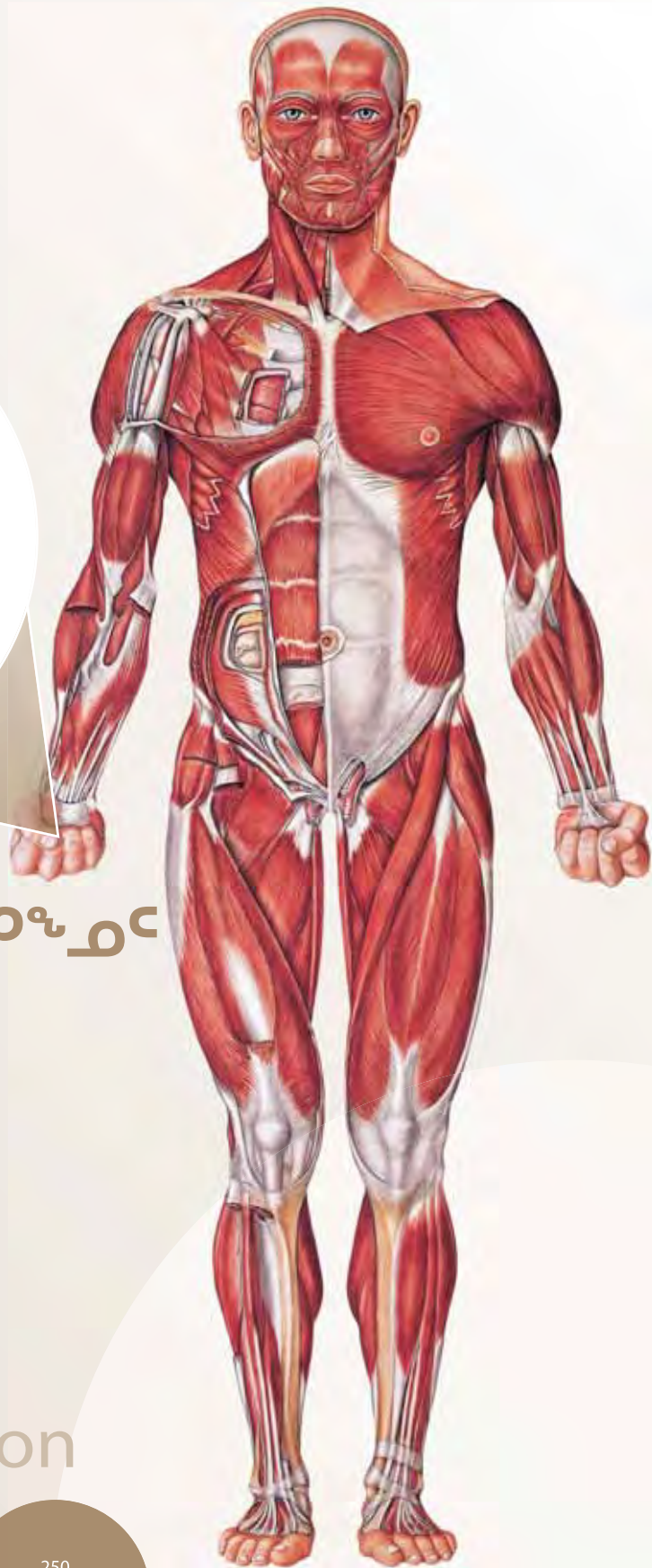
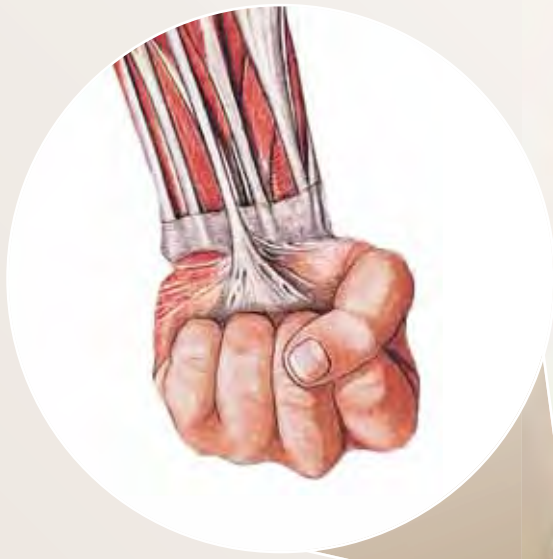
ՎնՎ՛ ԵՐ՞Ն  
Aariap Nukinga  
Tuigup Ivalua  
Muscle deltoïde





# Flexion/s



በፍርሰት ወይም በፍር  
ፈላጊነት

Timlimaaq  
nukingnut  
iqijarninga  
Iqimmirutit  
Pli du menton



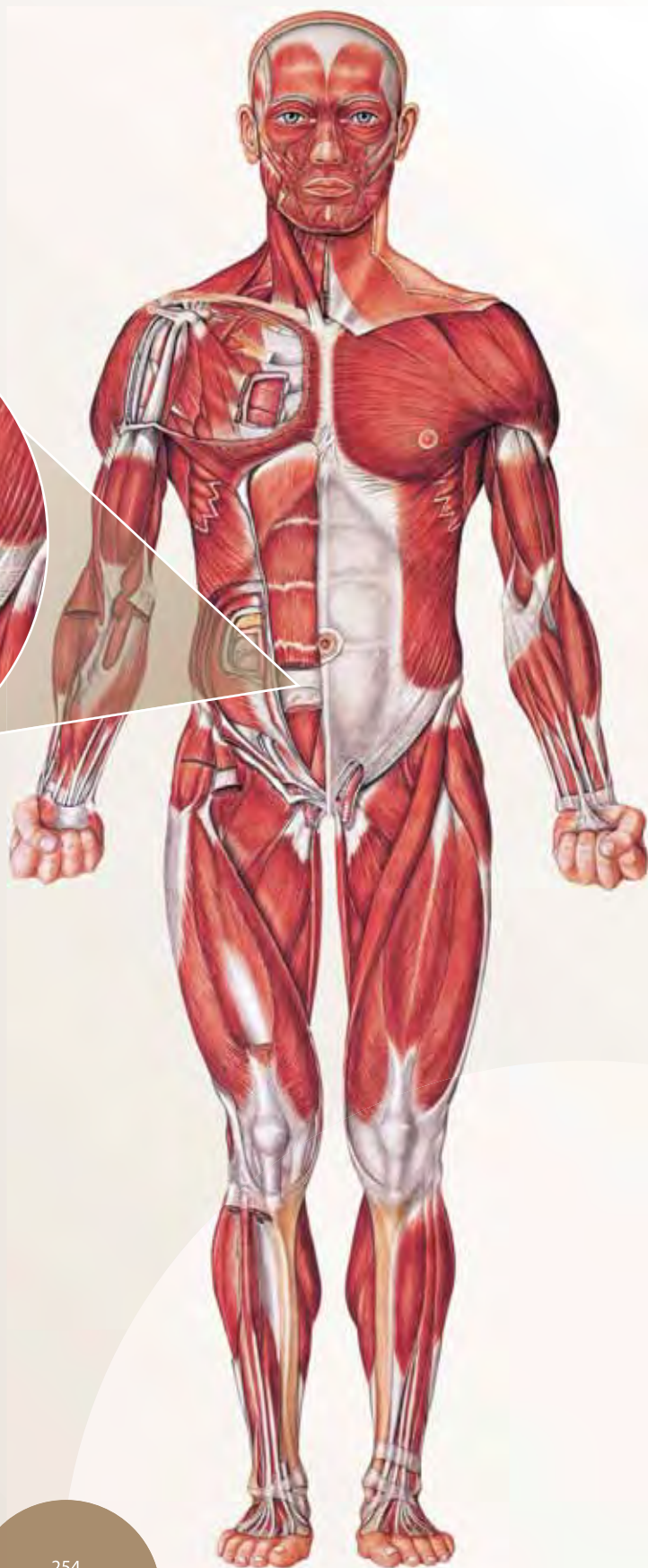
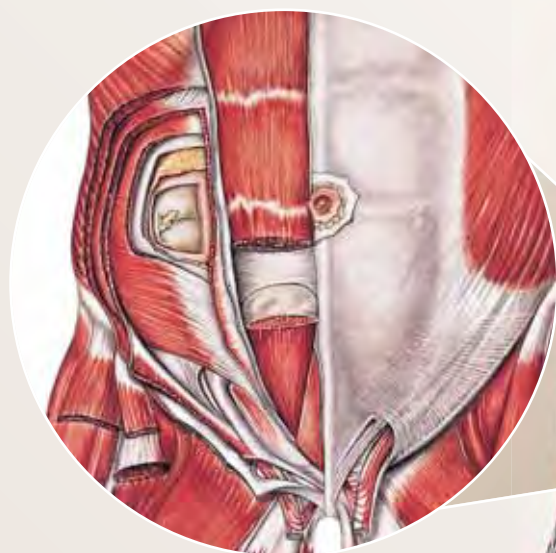






# Hernia



ԳՆՈՆ

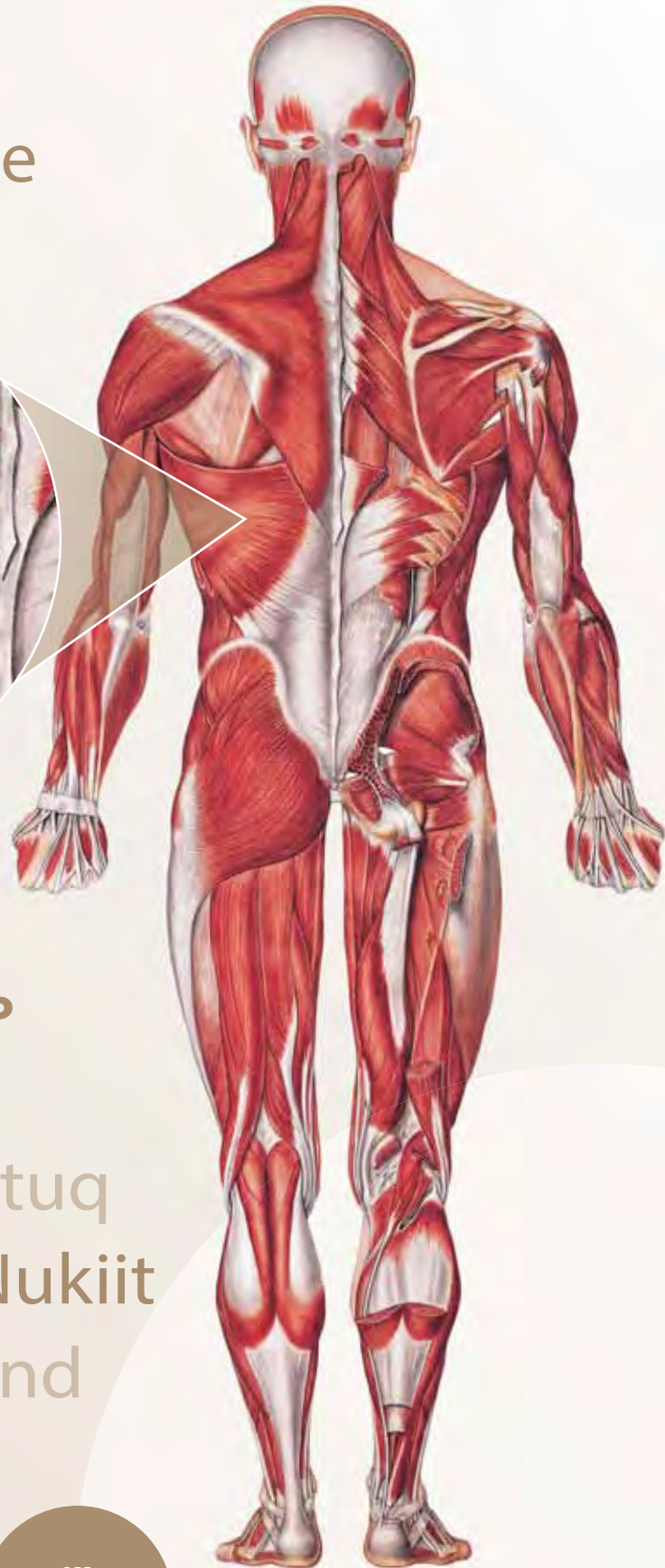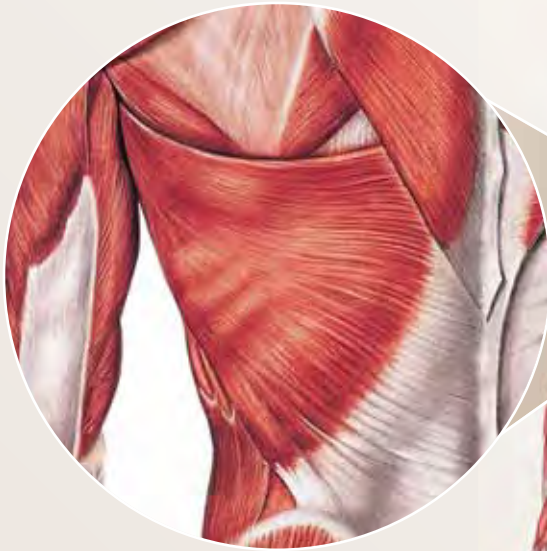
Qatik

Aniniq

Hernie



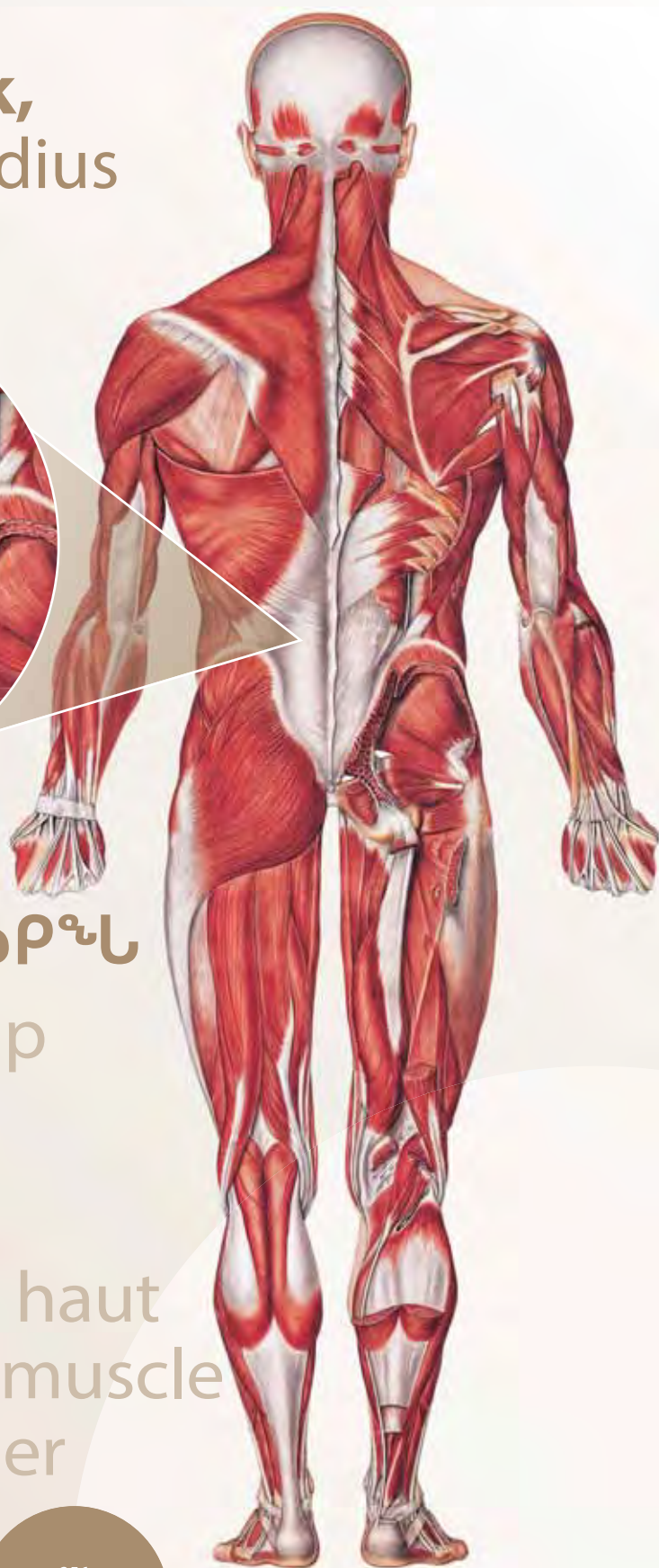
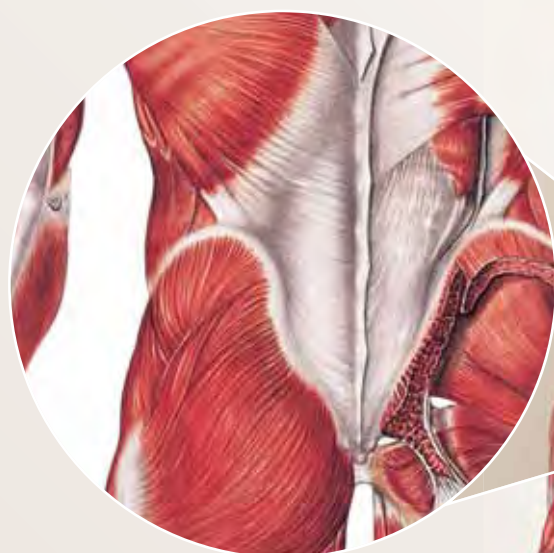
# Latissimus Dorsi Muscle



ᓄᓯᓴ  
ᓴᓂᓴᓴᓴᓴᓴᓴᓴᓴ

Nukik  
Sanirarmiittuq  
Haniraup Nukiit  
Muscle grand  
dorsal

# Lower Back, Gluteus Medius Muscle



ᐃᑦᑎᓐᓇᑦ ᓄᑭᓐᓴ

Kuuttinnaap

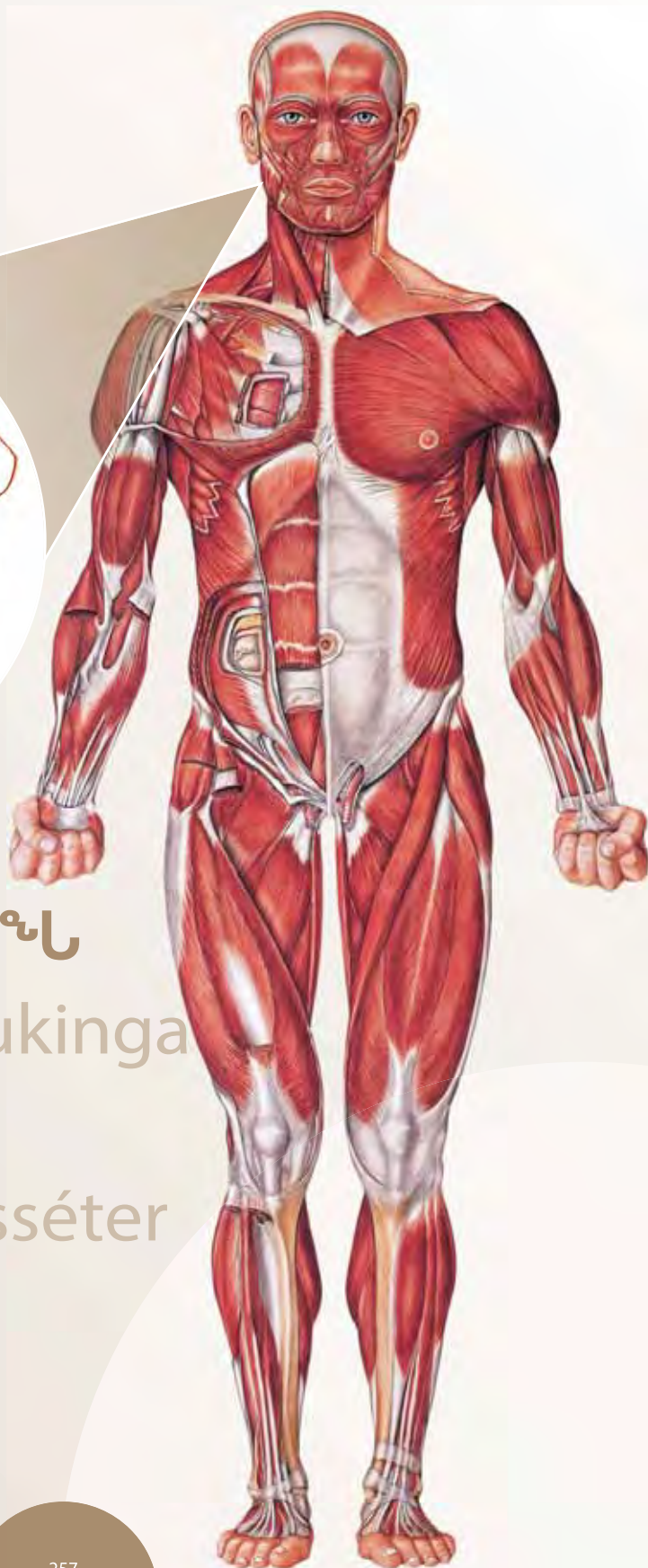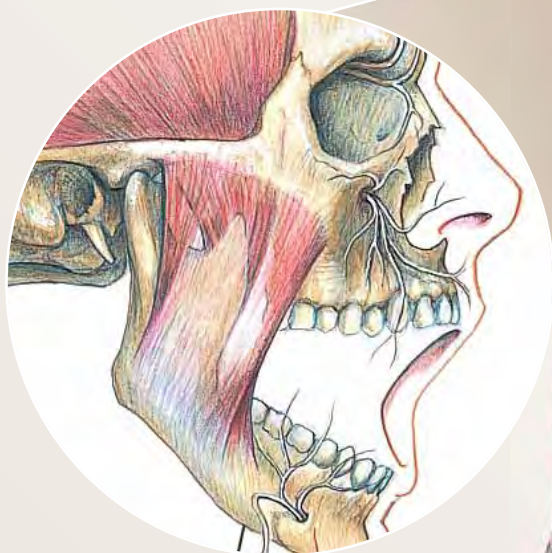
Nukinga

Kuuttiniq

Bas du dos, haut  
de la fesse, muscle  
moyenfessier



# Masseter Muscle



ᐱᓄᓴᓴᓴᓴ ᐱᓄᓴᓴᓴᓴ

Agli ruup Nukinga

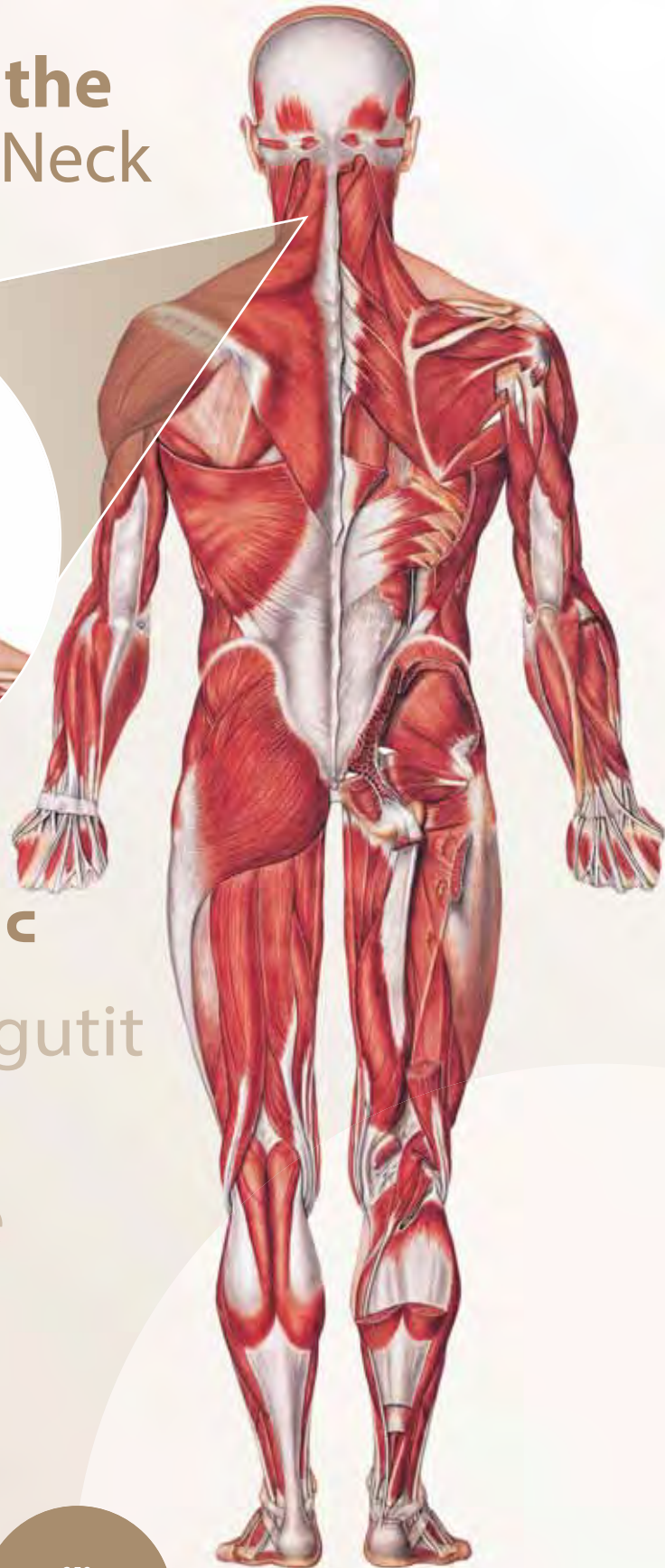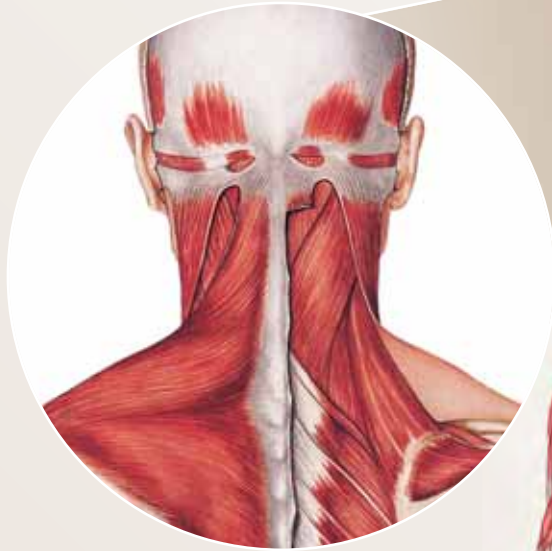Tuttak

Muscle masséter





# Muscles of the Back of the Neck



תנוסוגלוגיט

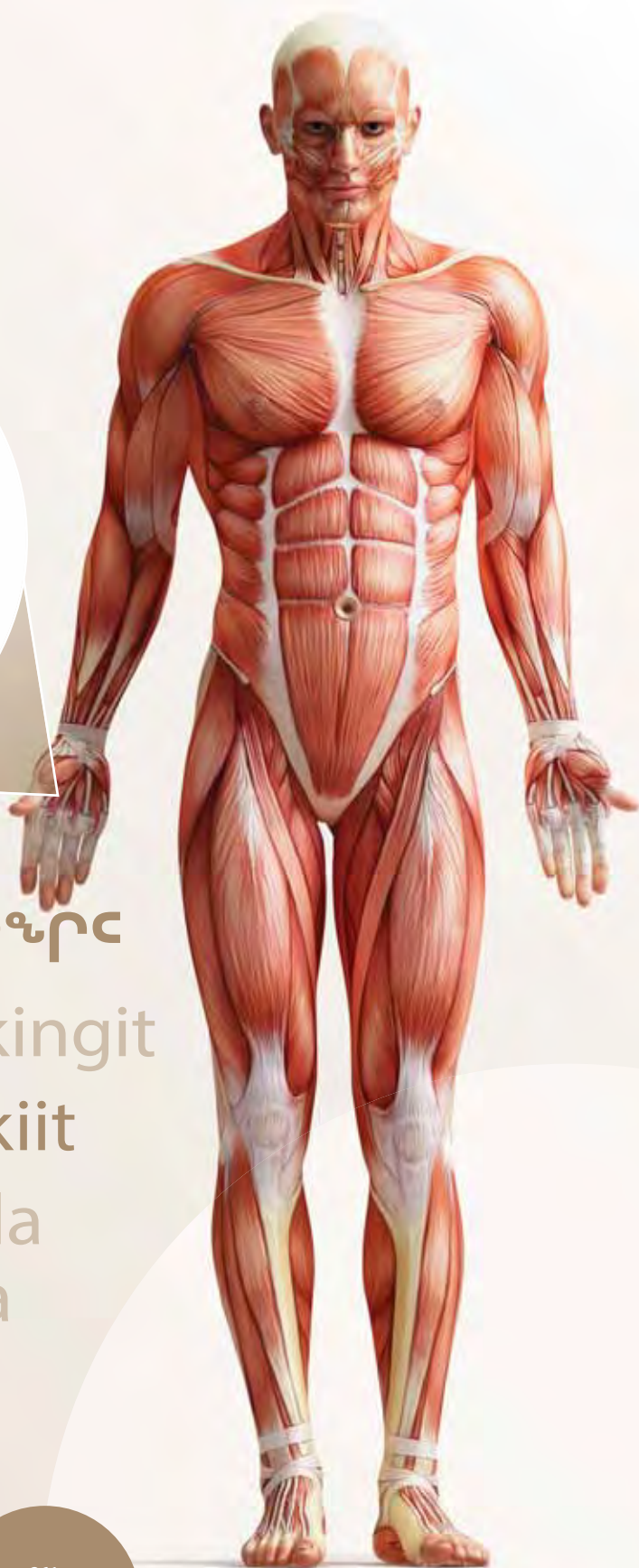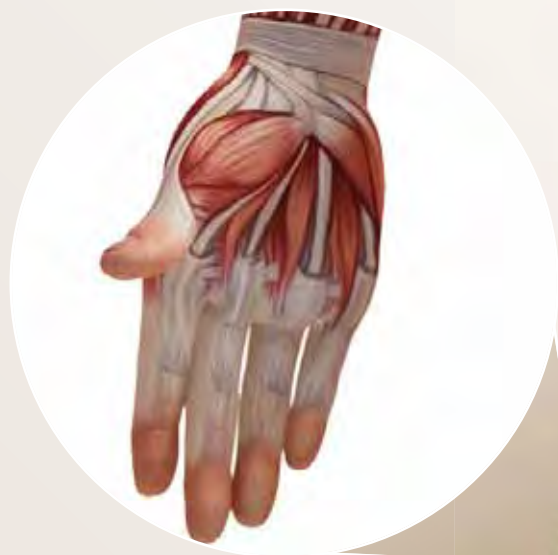Tunusuglugutit

Aarlugut

Muscles de  
la nuque



# Muscles of the Palm



ΔΟΛΔ< ρρ<ρ<

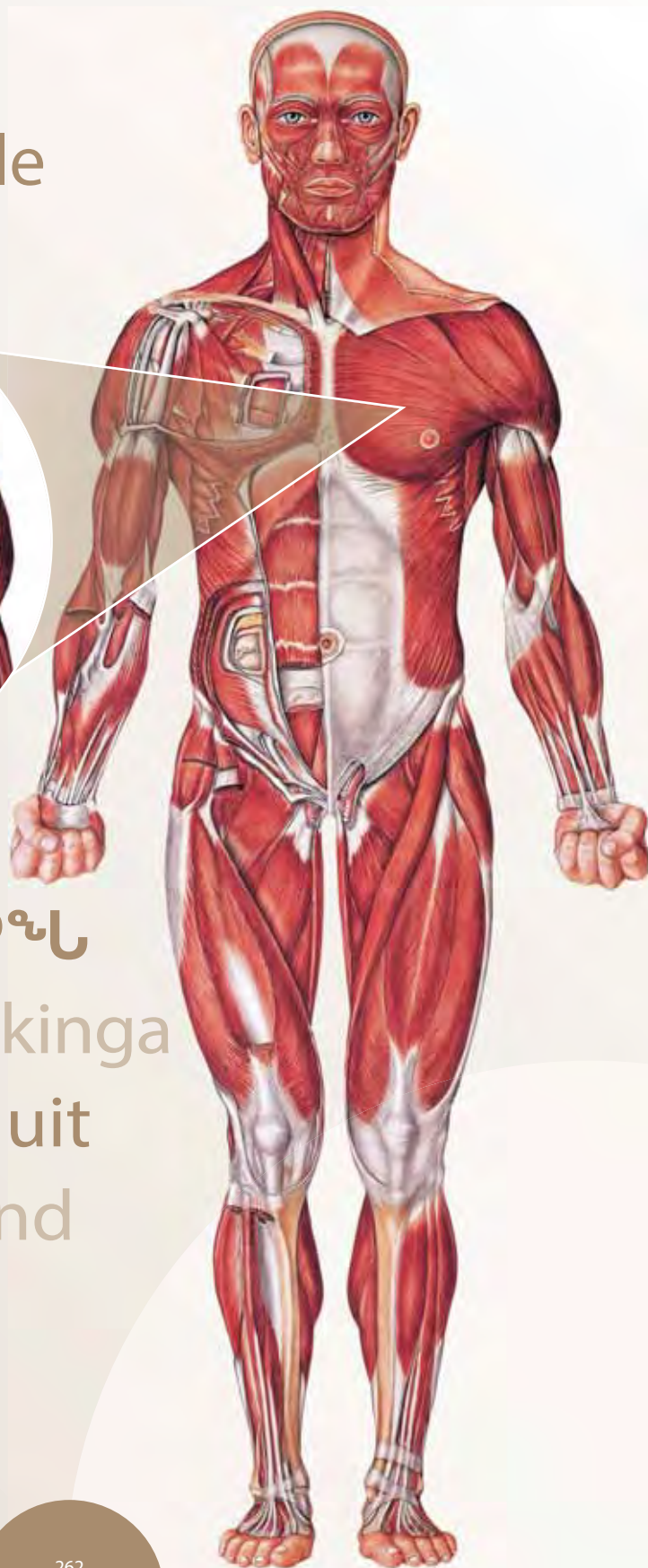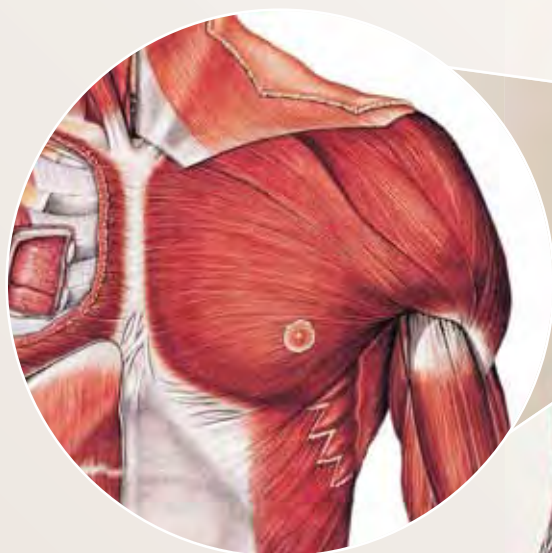Itimaup Nukingit

Itimaup Nukiit

Muscles de la  
paume de la  
main



# Pectoralis Major Muscle



ԿՆՆԱԾՅ՝ ԵՐՆՆ

Sagviup Nukinga

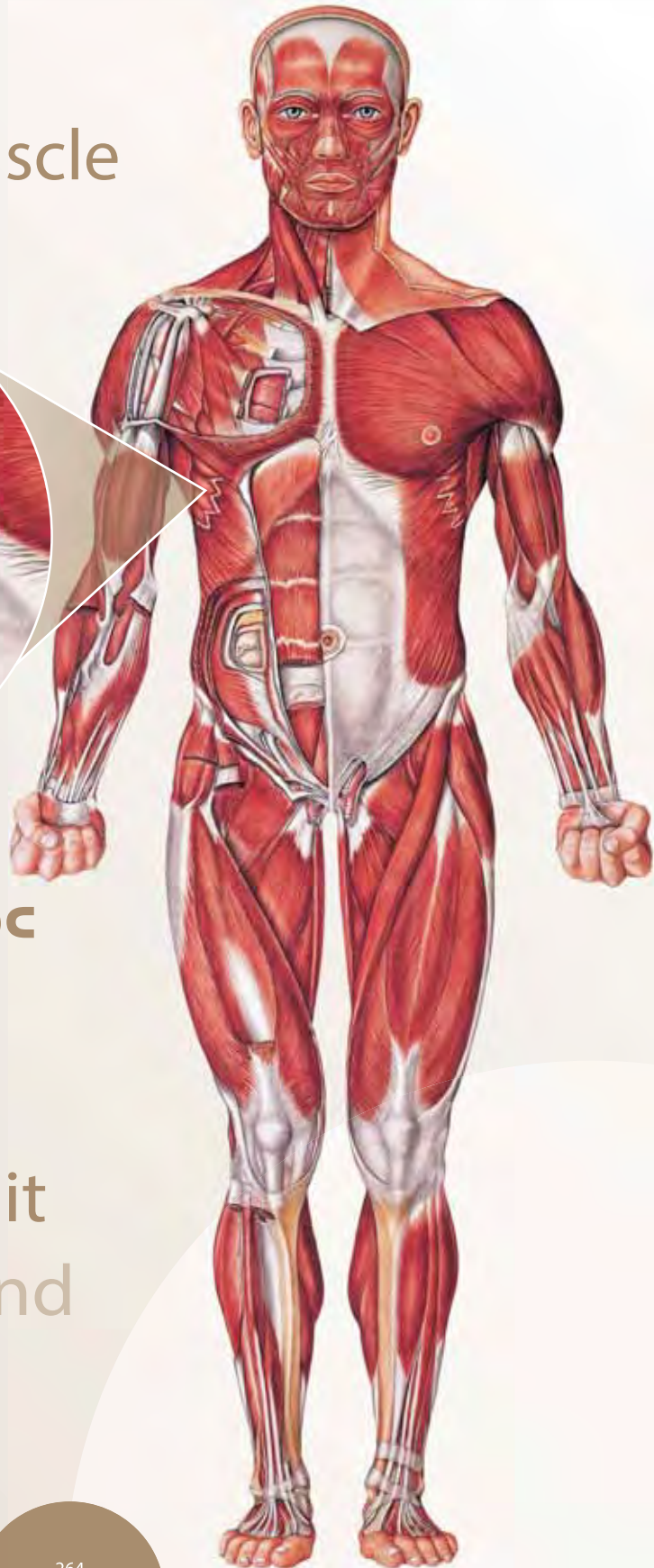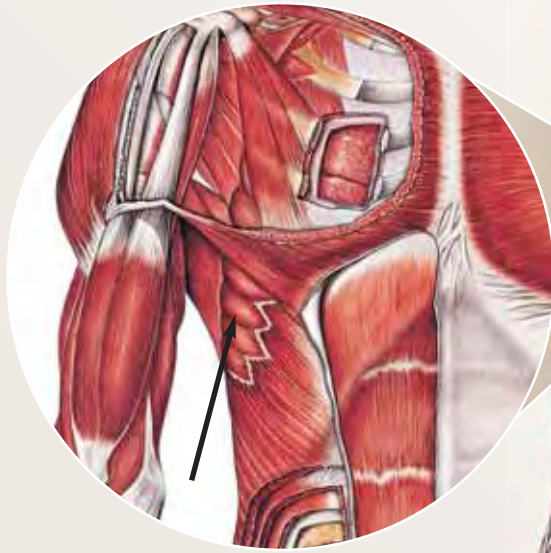Hatqap Ivaluit

Muscle grand  
pectoral





# Serratus Anterior Muscle



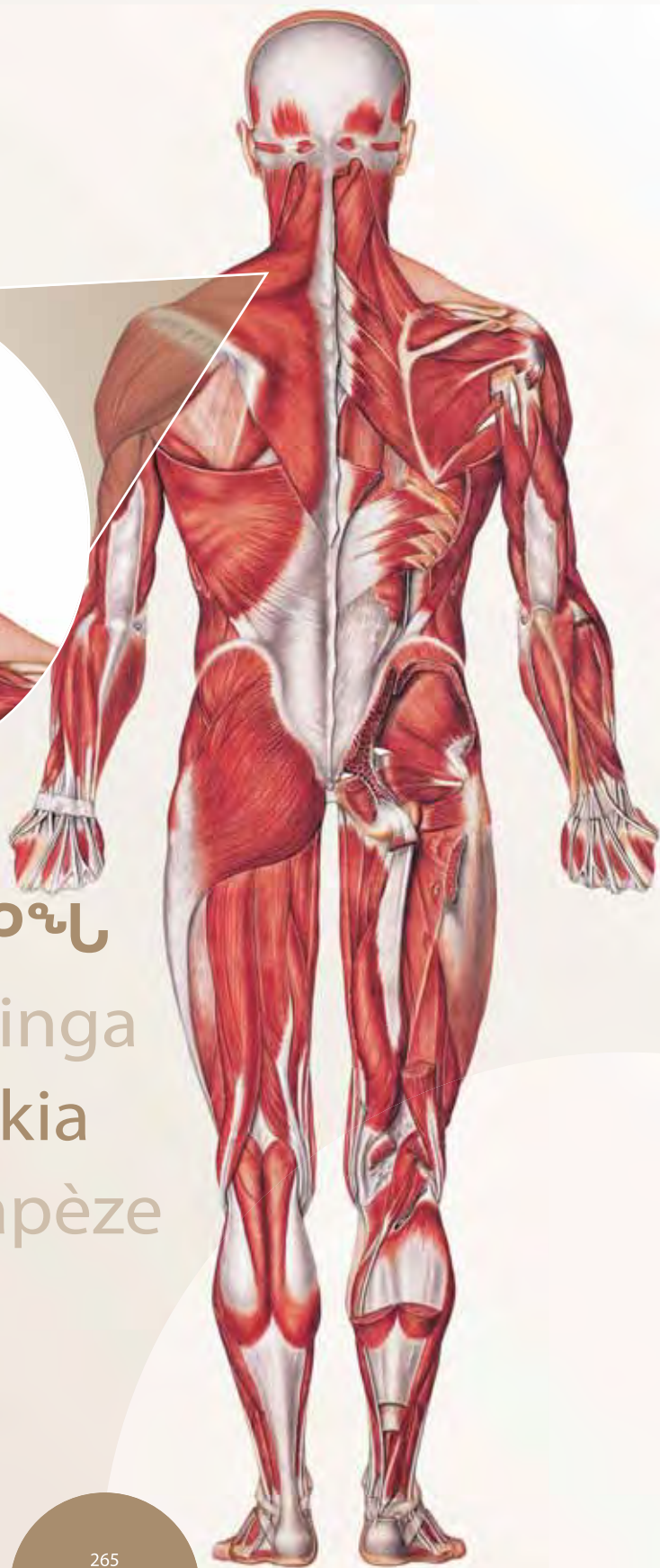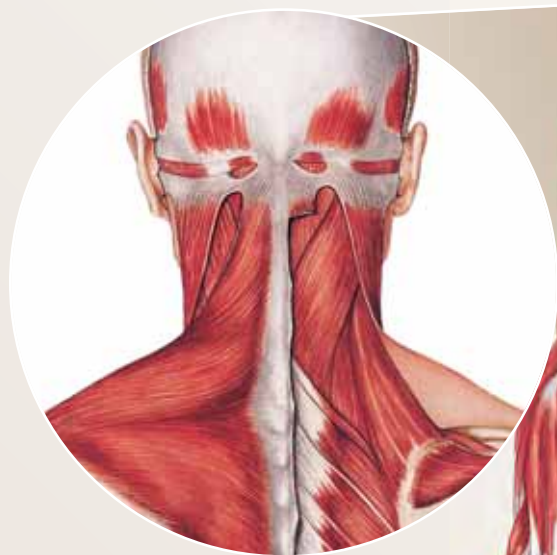ካሪፍፍፍ ስቦሮ

Sanirarmi  
Nukiit

Uniup Nukiit  
Muscle grand  
dentelé



# Trapezius Muscle



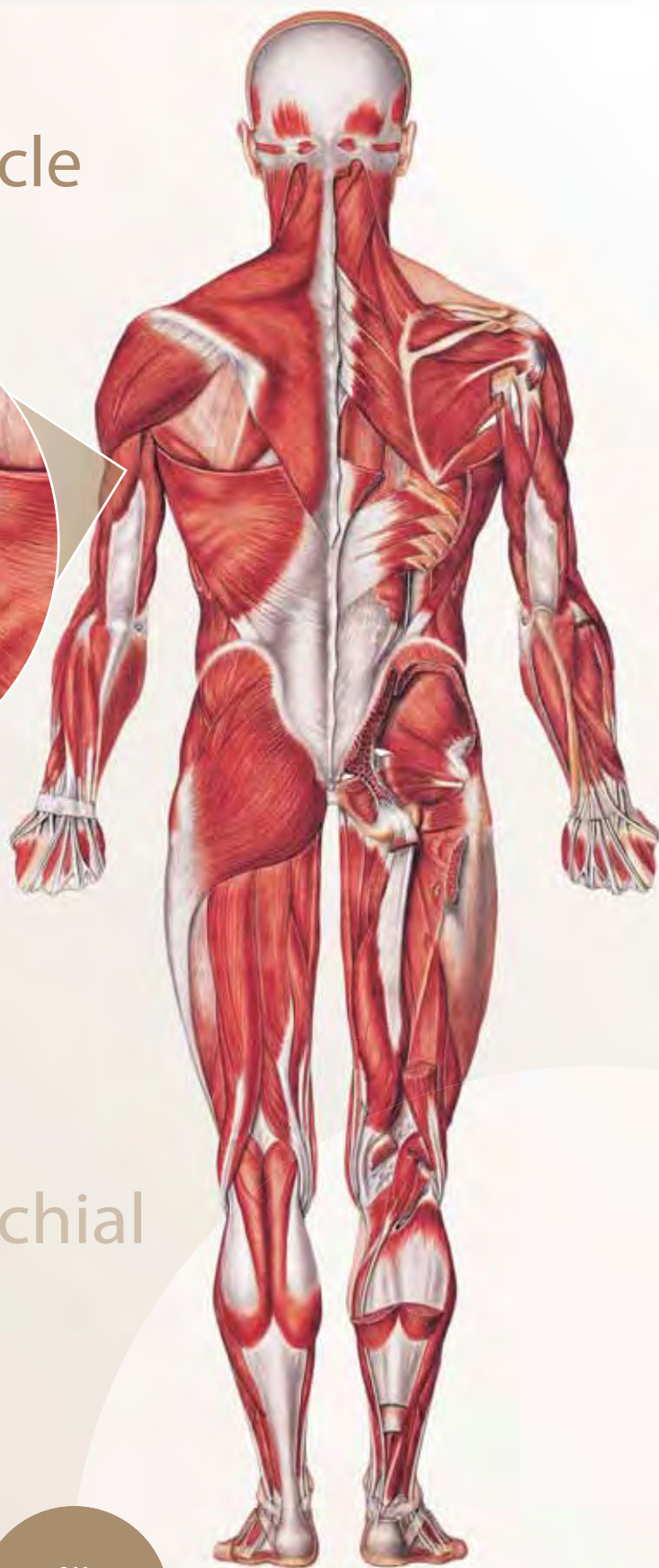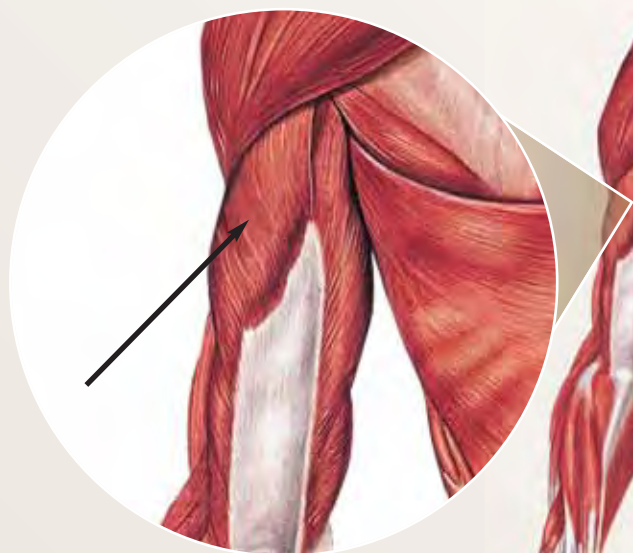
Արիափ Նուկինգա

Ariap Nukinga

Aariap Nukia

Muscle trapèze

# Triceps Brachii Muscle



ᠪᠴᠳᠠᠭᠪ

Kattuaq

Kattuaq

Triceps brachial



# Organs/Digestive/ Brain

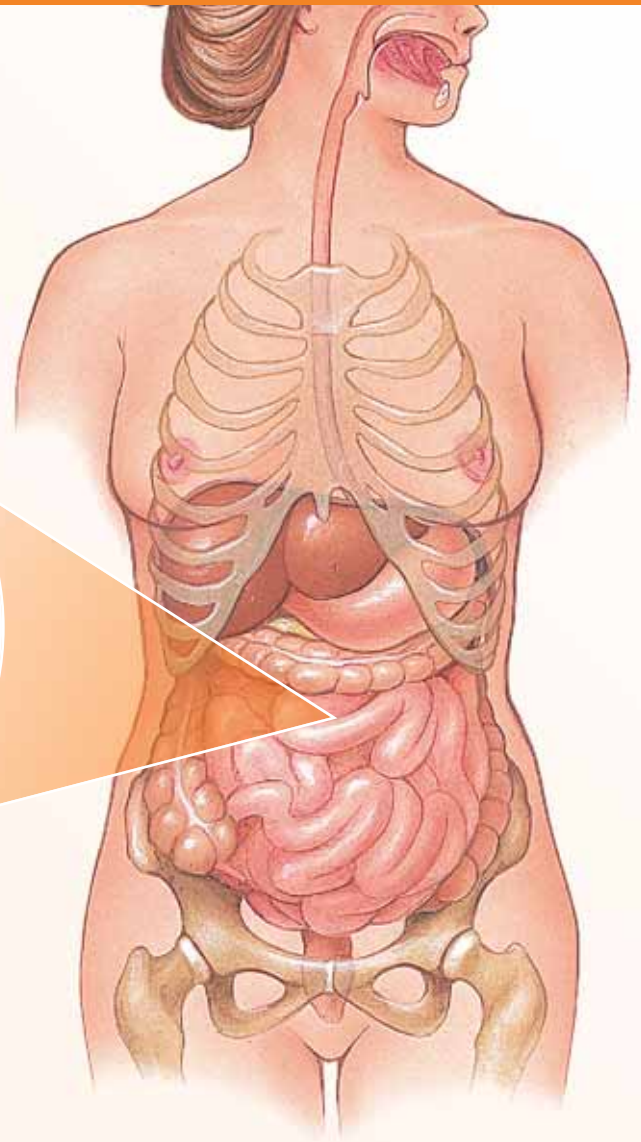
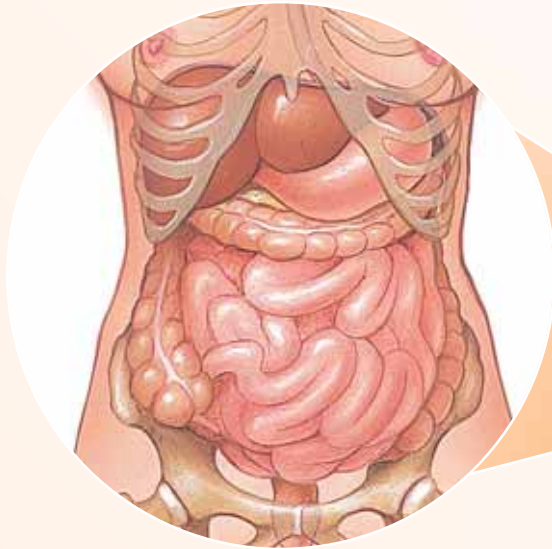
Δ<sup>ε</sup>ε<sup>δ</sup> / σ<sup>ρ</sup>λ<sup>ε</sup>π<sup>ο</sup>σ<sup>τ</sup>  
◄<sup>δ</sup>π<sup>ρ</sup>λ<sup>ε</sup>π<sup>ο</sup> / ε<sup>β</sup>ρ<sup>η</sup>ς<sup>ε</sup>

Irraviit/Nirijattinnik  
Aviktirijjuti/Qarisaq

Iluliit/Niqinik iihivia/Qaritaq

Organes / Appareil  
digestif / Cerveau

# Abdominal Cavity



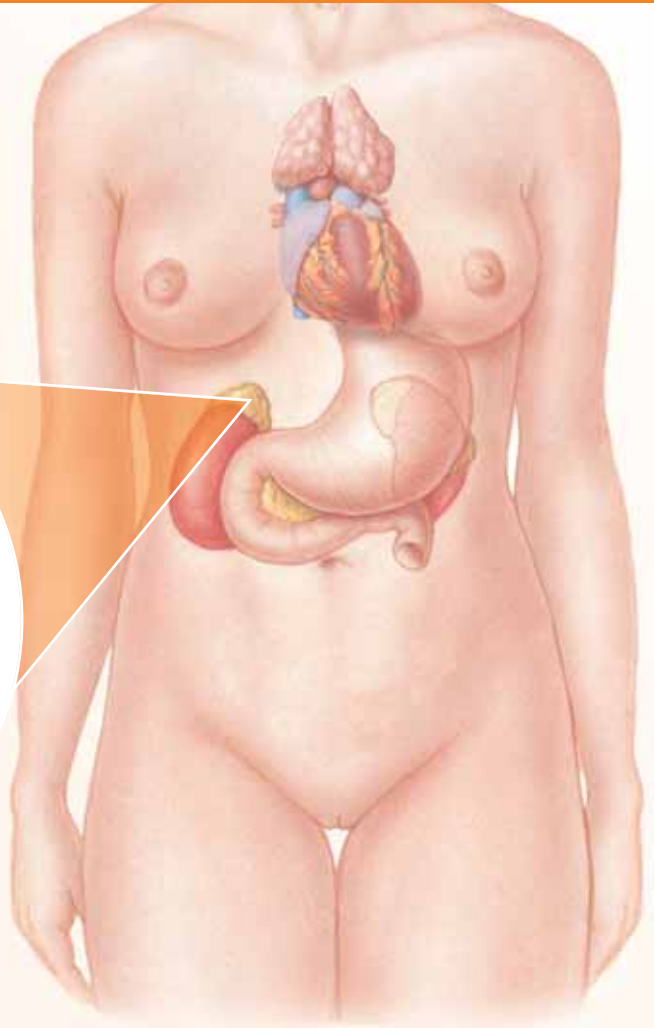
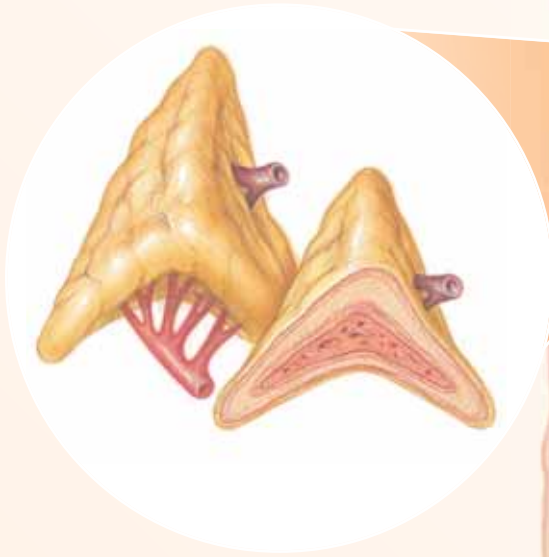ᐅᑦᑲ

Naaq

Kanivaut

Cavité abdominale

# Adrenal Gland



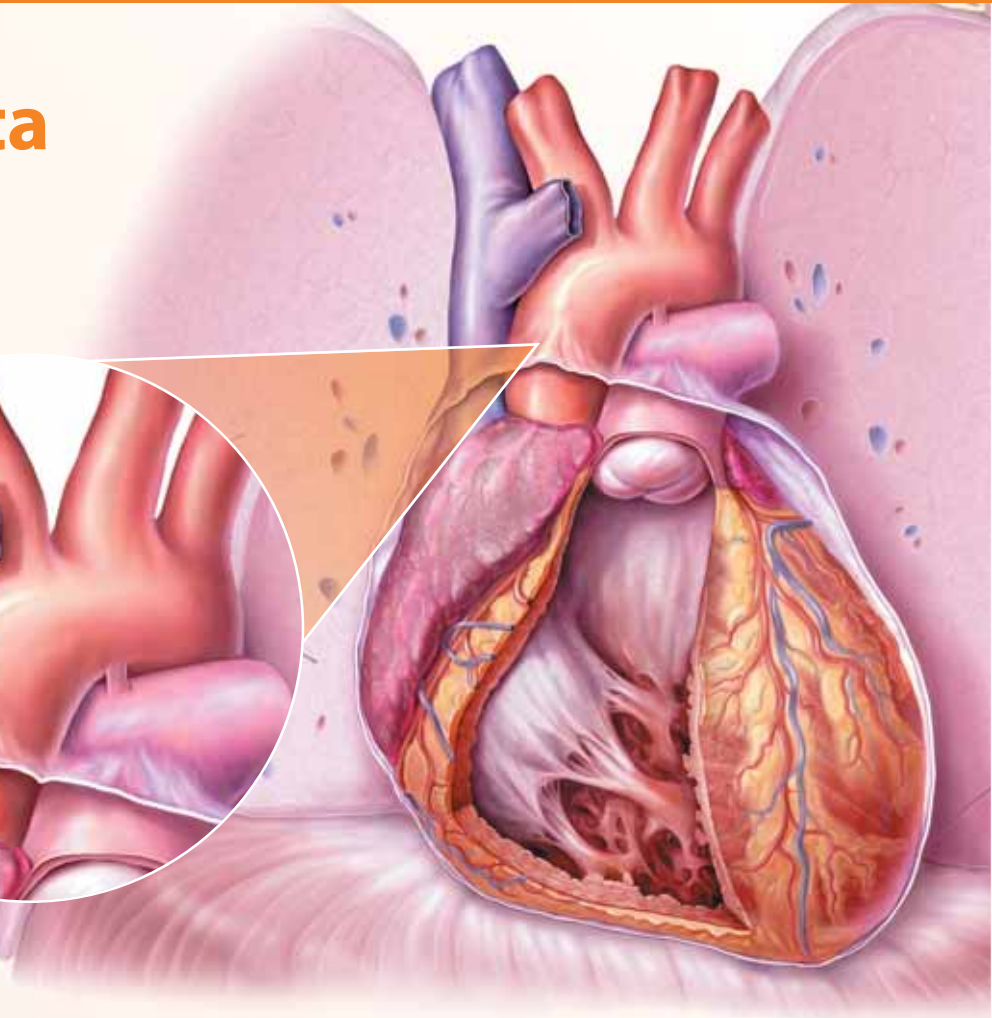
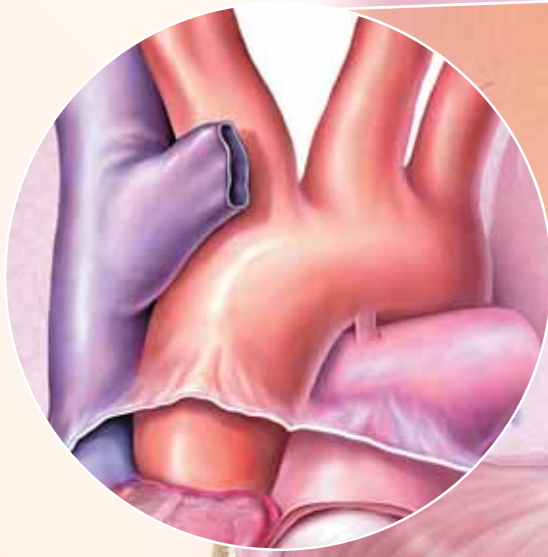
ᑕᑦᑲᑕᑭᑏᑦ

Taqturutiik

Taqtuuk Qulaaniittuk  
Qiniqhinaik

Glande surrénale

# Aorta



ᑭᑦᑲᑦ ᑭᑦᑲᑦ ᑭᑦᑲᑦ

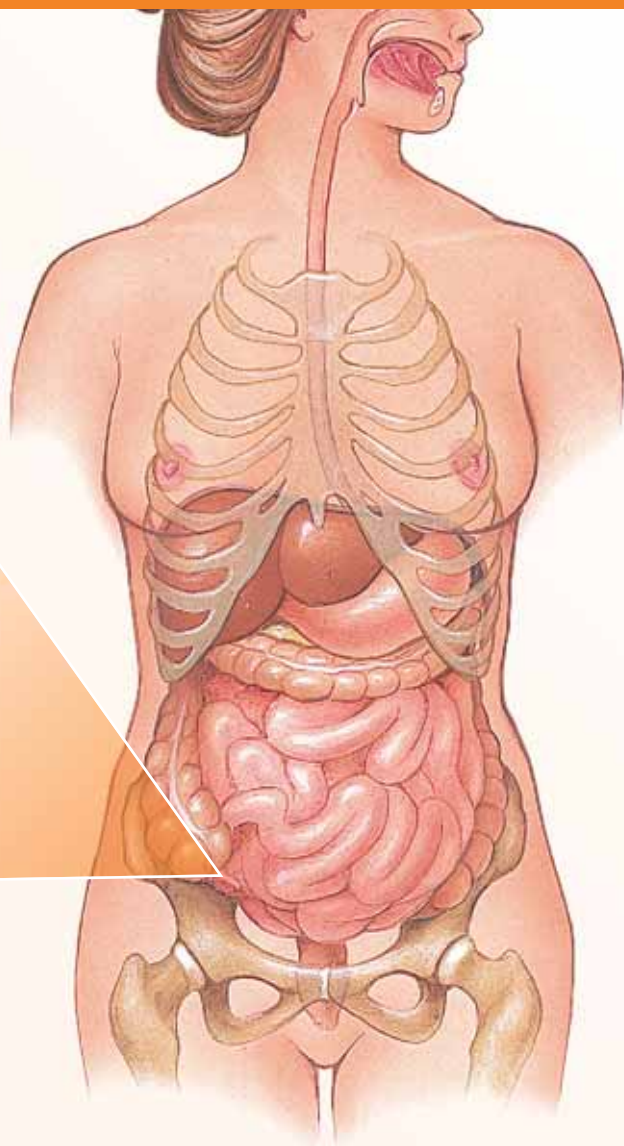
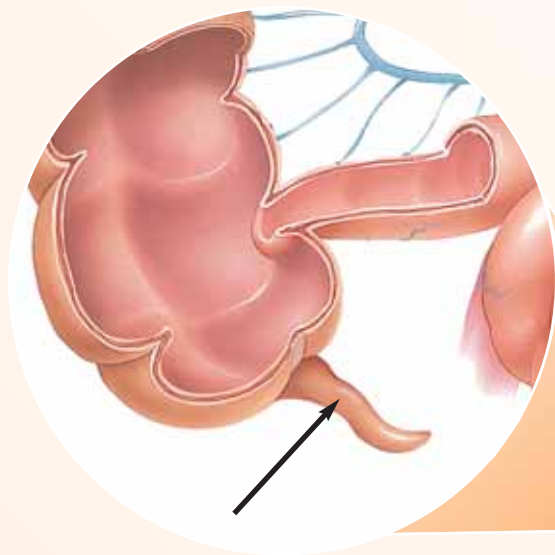
Qalluviaq

Qaalluviaq

Aorte



# Appendix



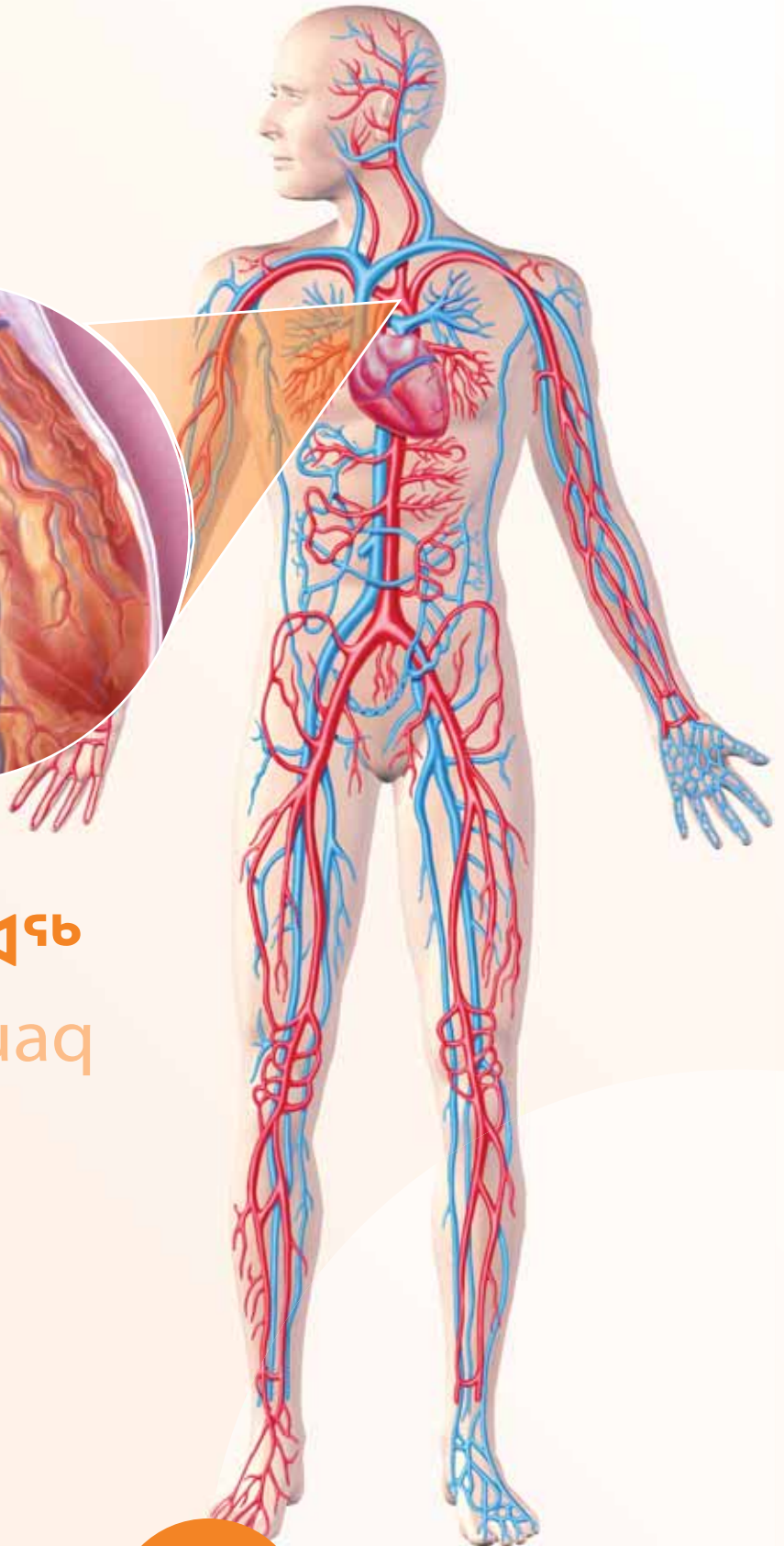
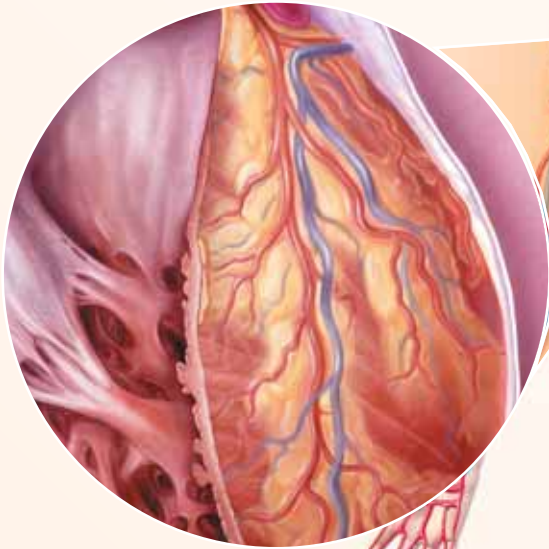
ᑭᕿᐱᕐᕐ

Qipingu

Ilulliut

Appendice

# Artery



ᑕᑦᑲᑦᑲᑦᑲᑦᑲᑦ

Taqarjuaq

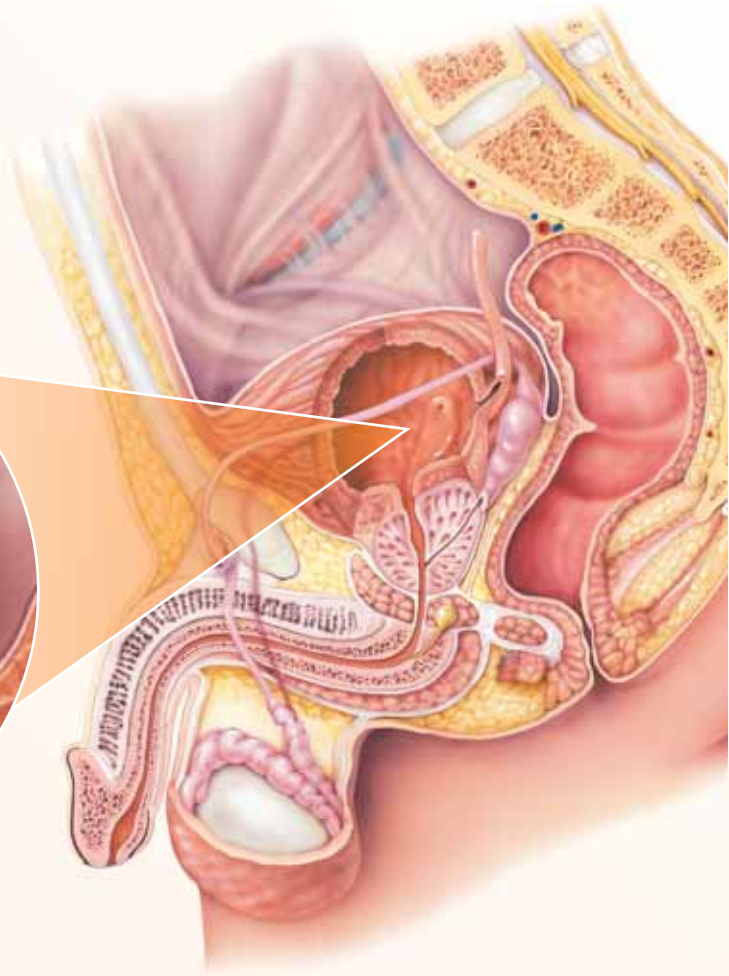
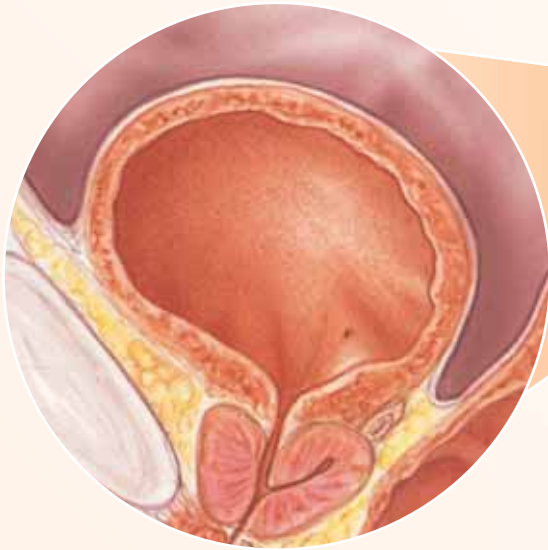
Taqait

Artère





# Bladder



ጫሮጫ

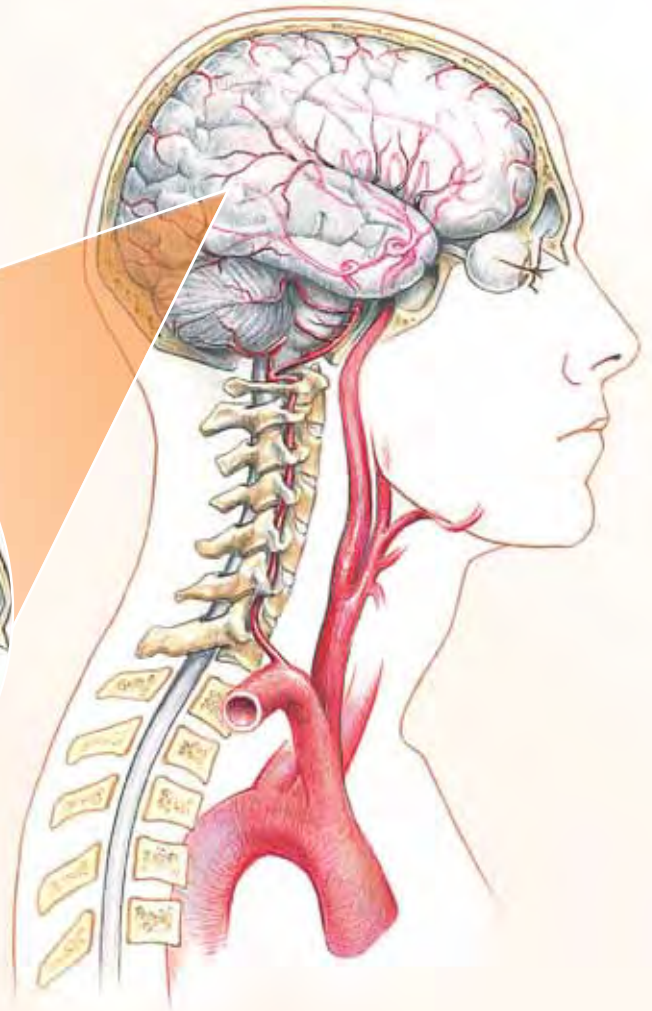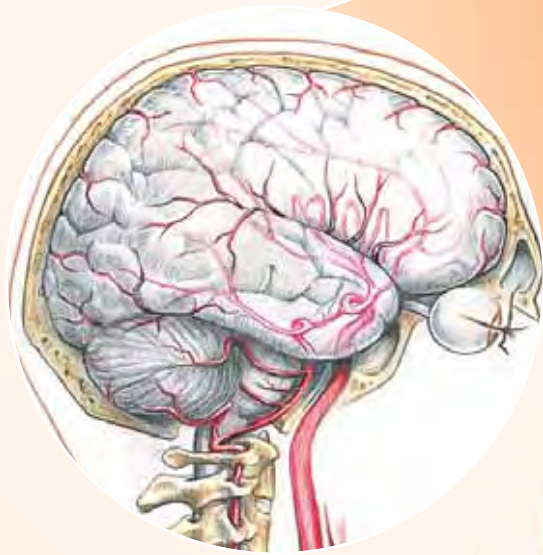Nakasuk

Nakahuk

Vessie



# Brain



ԳԵՂԻԳԵ

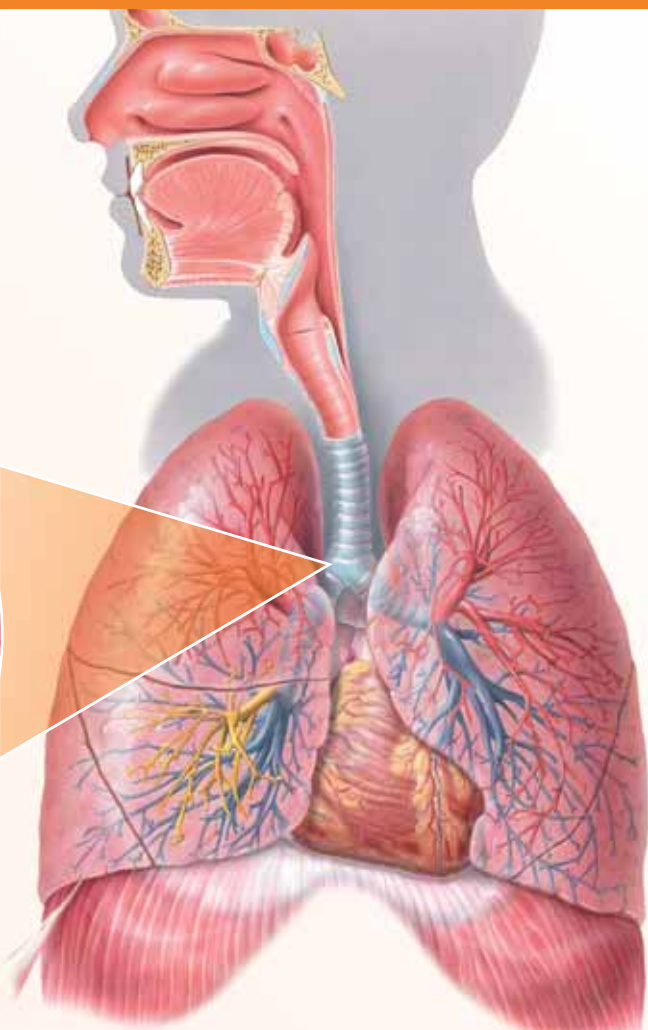
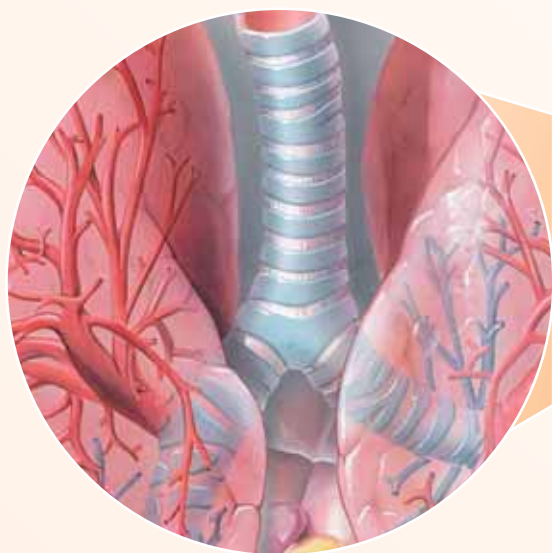Qarisaq

Qaritaq

Cerveau



# Bronchi



ᐅᑦᑲᑦᑭᑦ ᐅᑦᑲᑦᑭᑦ ᐅᑦᑲᑦᑭᑦ ᐅᑦᑲᑦᑭᑦ

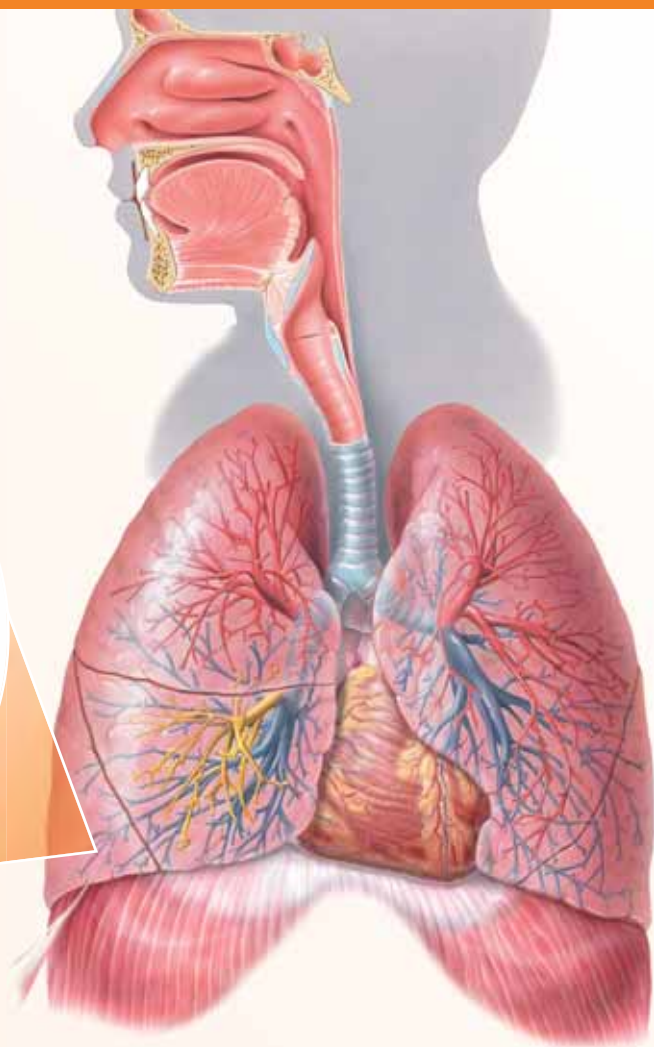
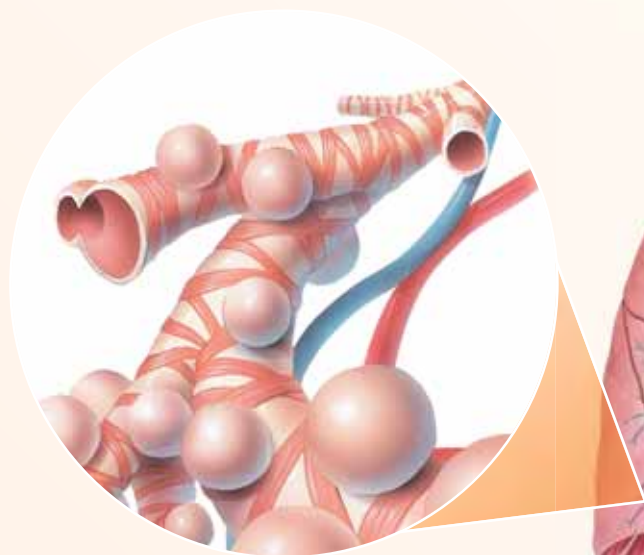
Tuqtuup

Puvangmuanganinga

Puvaup Huvyuit

Bronches

# Bronchioles



ᓄᓐᓂᓐ ᓂᓐᓂᓐ

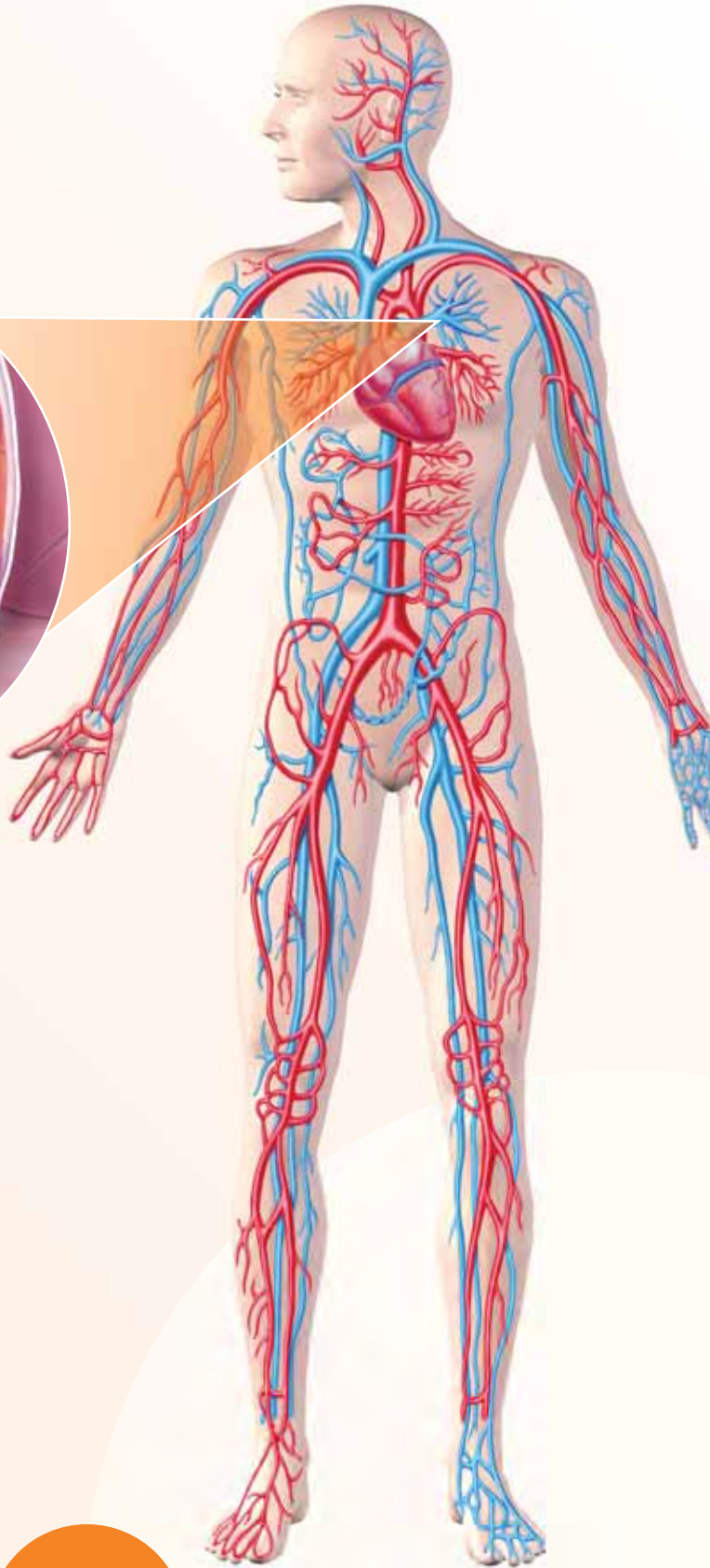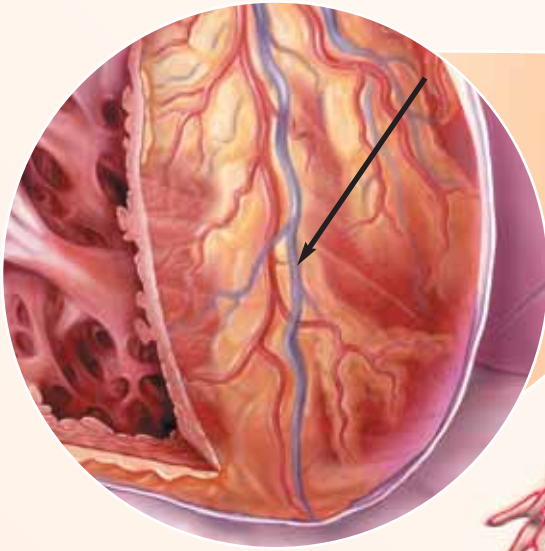
Nuviqłuit

Huvyuit

Bronchioles



# Capillary



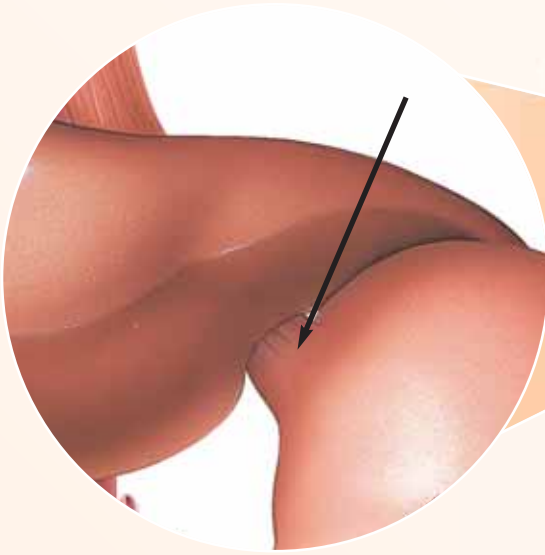
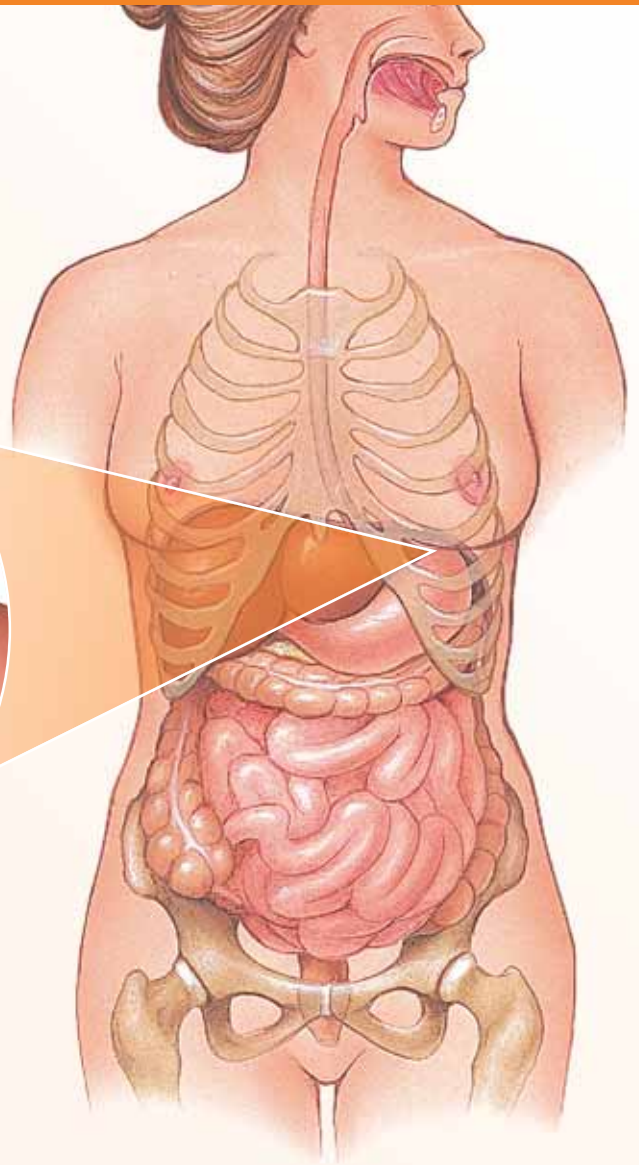
ᑕᑦᑲᑦᑭᑦᑲᑦ

Taqarusiq

Taqannuit

Capillaire

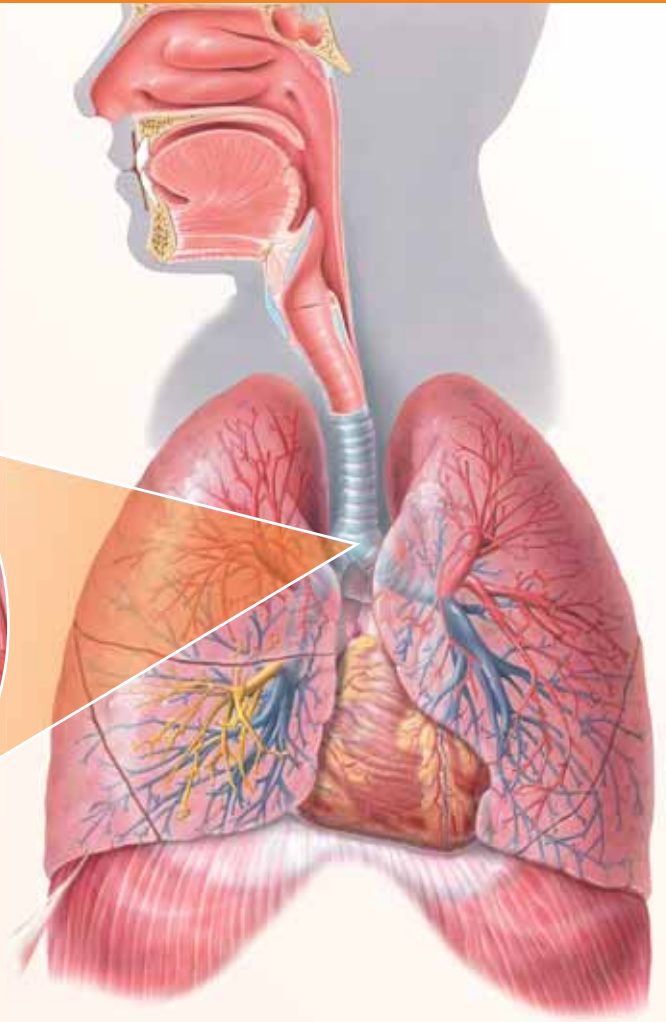
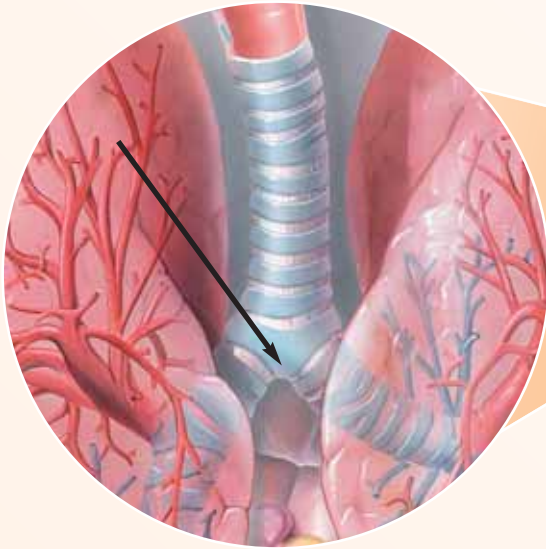
# Cardia Esophageal Junction



ᐱᑦᐱᑦᐱᑦᐱᑦ  
ᑦᐱᑦᐱᑦᐱᑦᐱᑦ

Aqiaruup Quuqqanga  
Aqiaruup Pivviuyaa  
Cardia

# Carina / Bifurcation of Trachea



ܕܩܒܐ ܕܩܒܐ

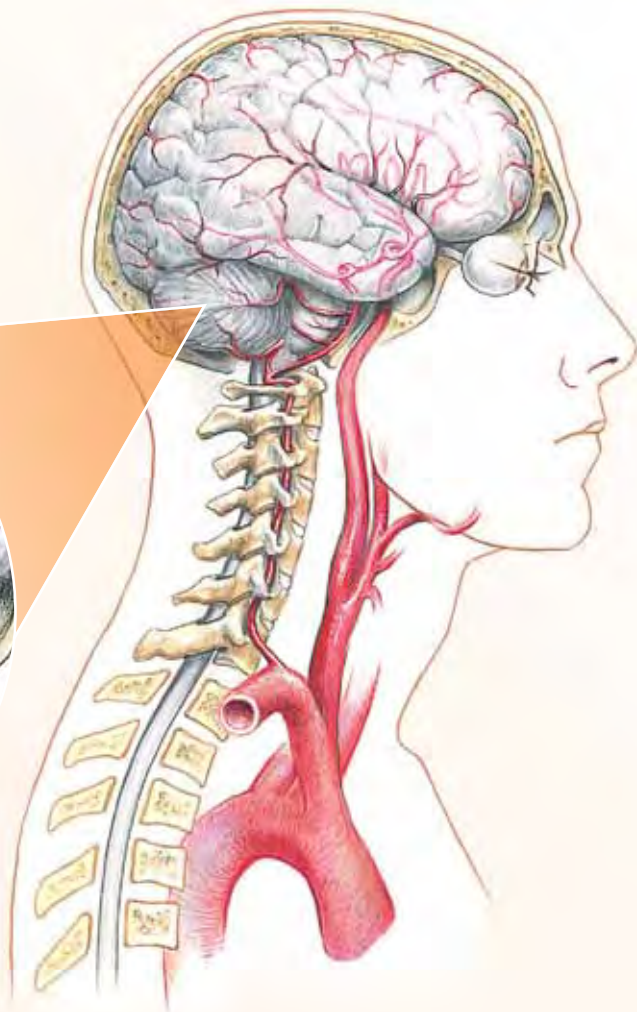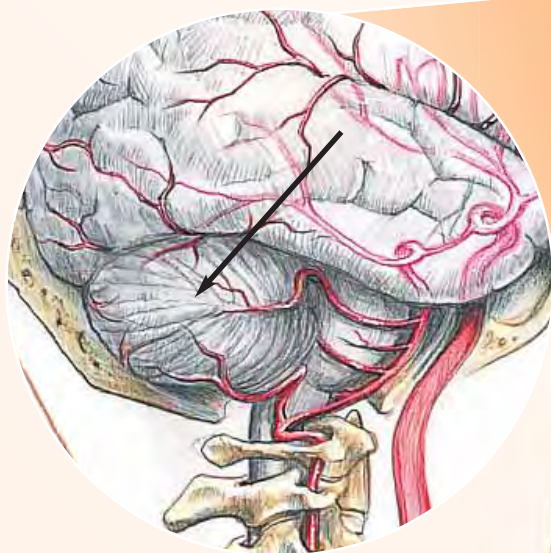
Tuqłuk

Tuqhuk

Éperon trachéal



# Cerebellum

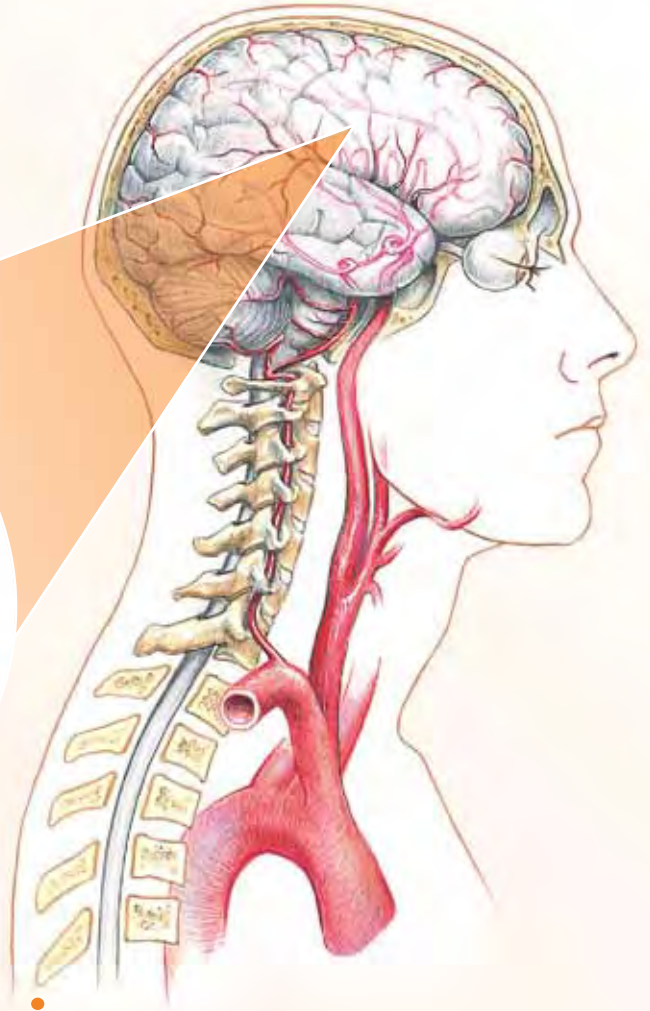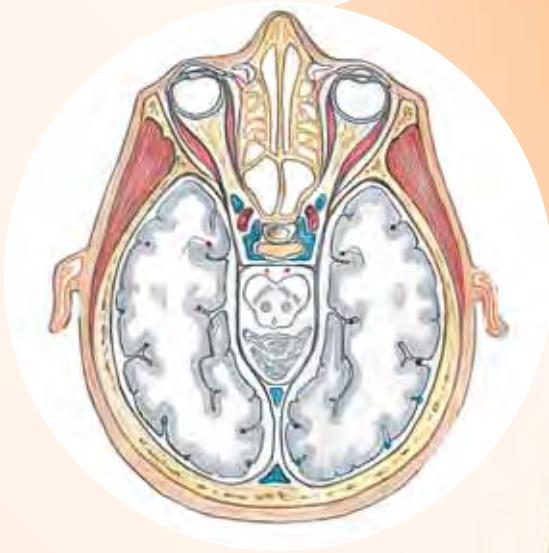


▷◁↳°∩Δ↵▷◁

Upalungaijaut  
Ihumaliurvik  
Cervelet



# Cerebral Hemispheres



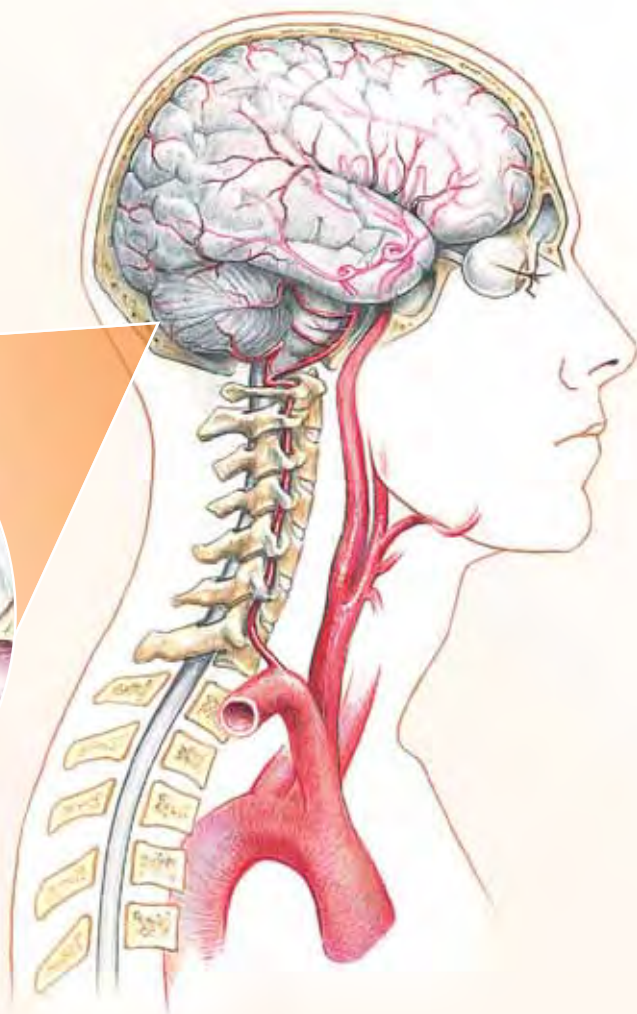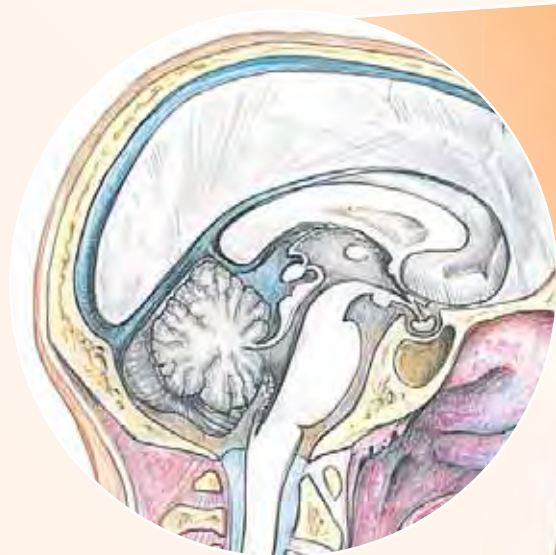ԳԵՂԻՆ ԴՆՉՐԻՆ

Qarisaak iglugiik

Qarittak Iglugiik

Hémisphères cérébraux

# Cerebral Meninges



ፍኑሲካጋፍ ጎጃሪ

Qarisaup Puunga

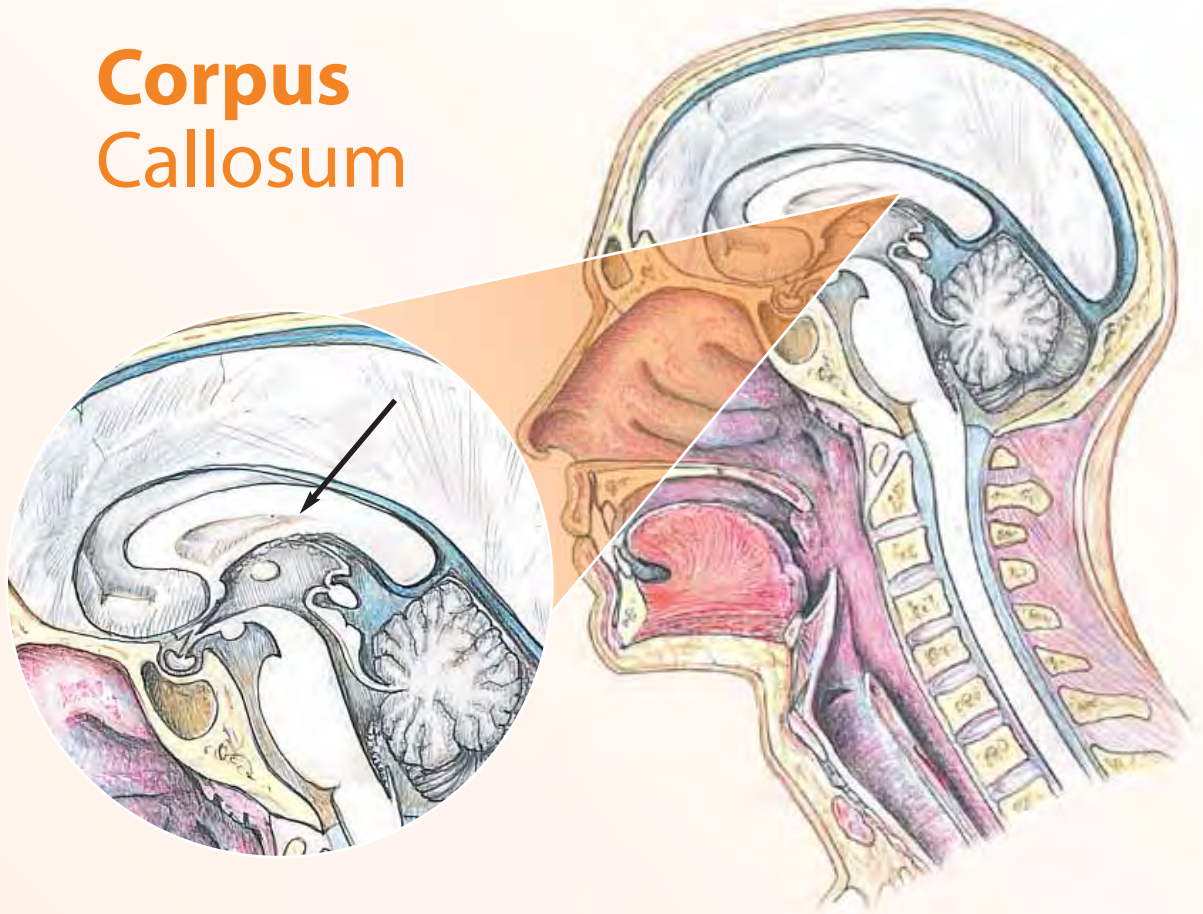
Qarittap Kapihianga

Méninges cérébrales





# Corpus Callosum



ԳԵՂԿՂԸ ԵՈՐՏԻՅ

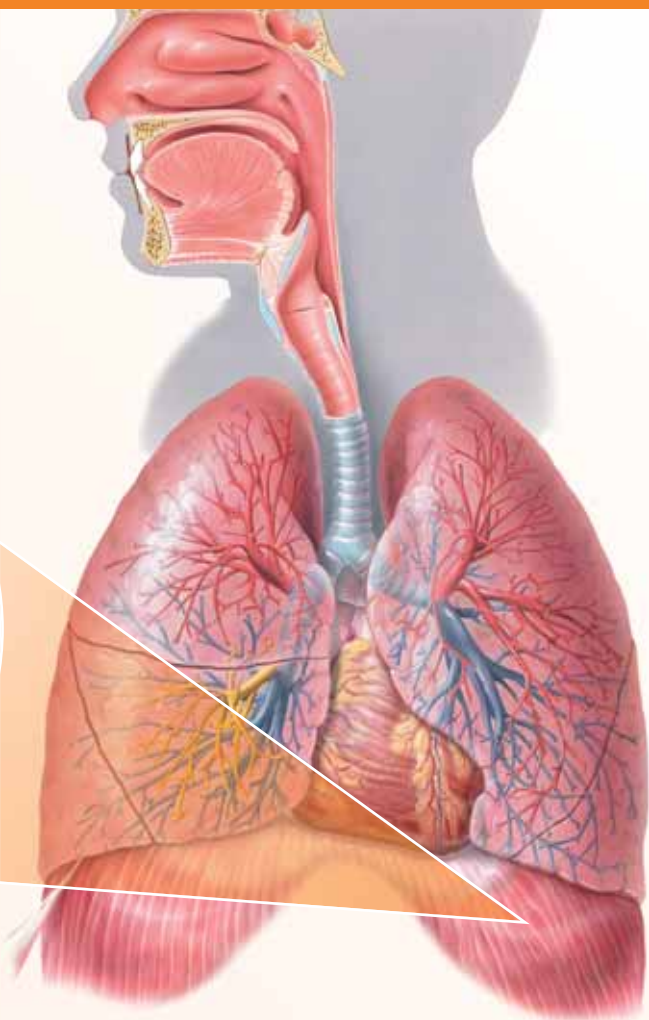
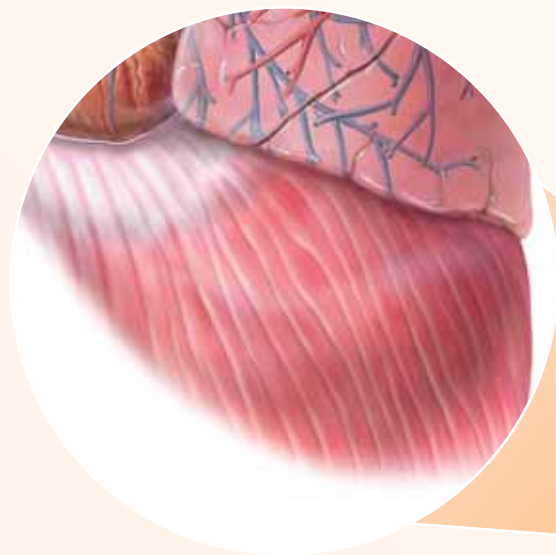
Qarisarmut Katinniq

Qarittap Akilvirutaa

Corps calleux



# Diaphragm



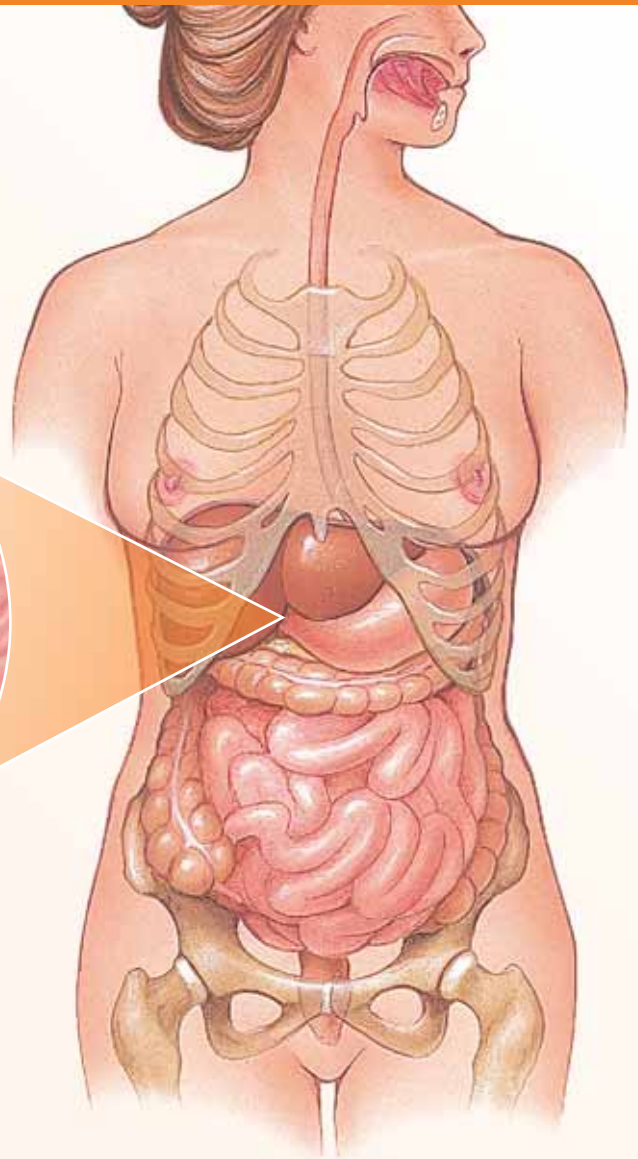
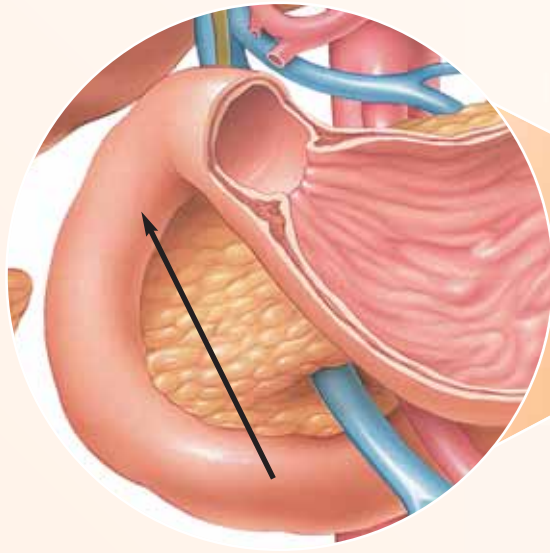
बसुदेव

Kanivaut

Kanivaut

Diaphragme

# Duodenum



ᑦᑭᑭᑦᑭᑦᑭᑦ

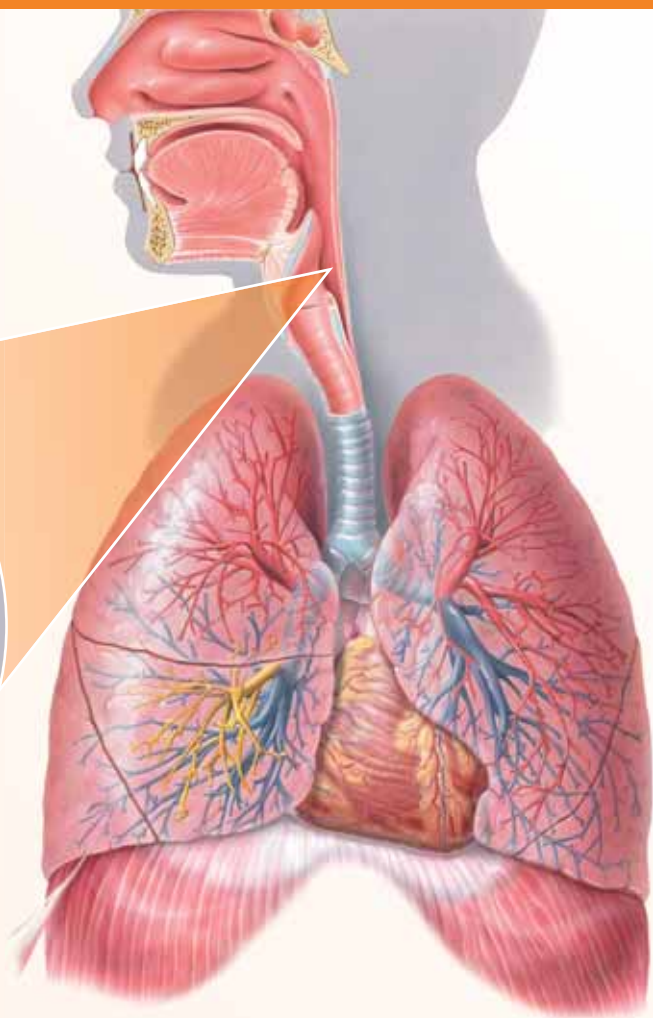
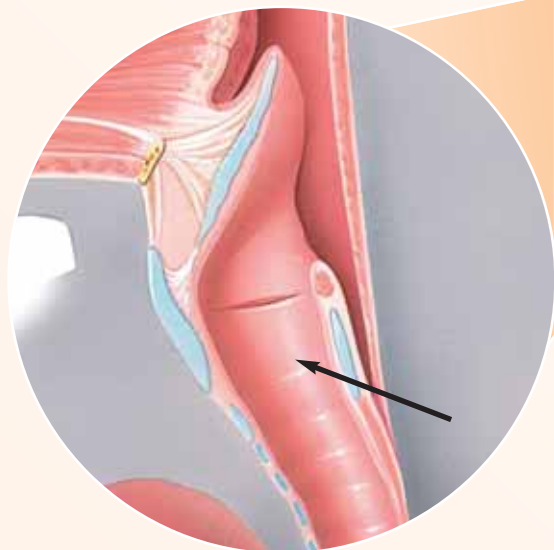
Quukinniq

Quukilruq

Duodénium



# Esophagus



ᐃᓴᓯᐃᑦᑲ

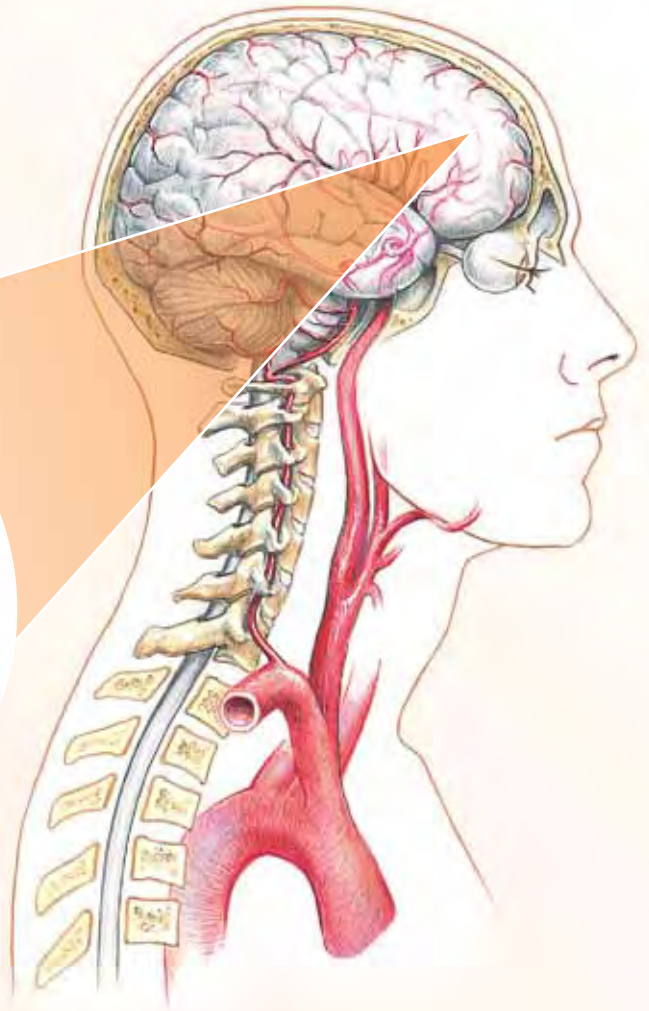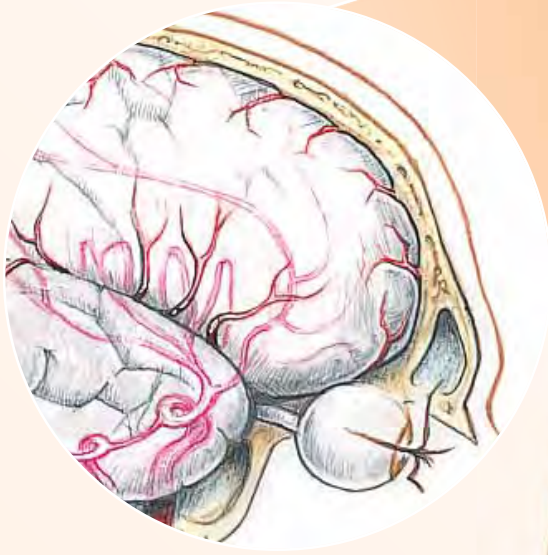
Iggiaq

Tuqhuk

Esophage



# Frontal Lobe



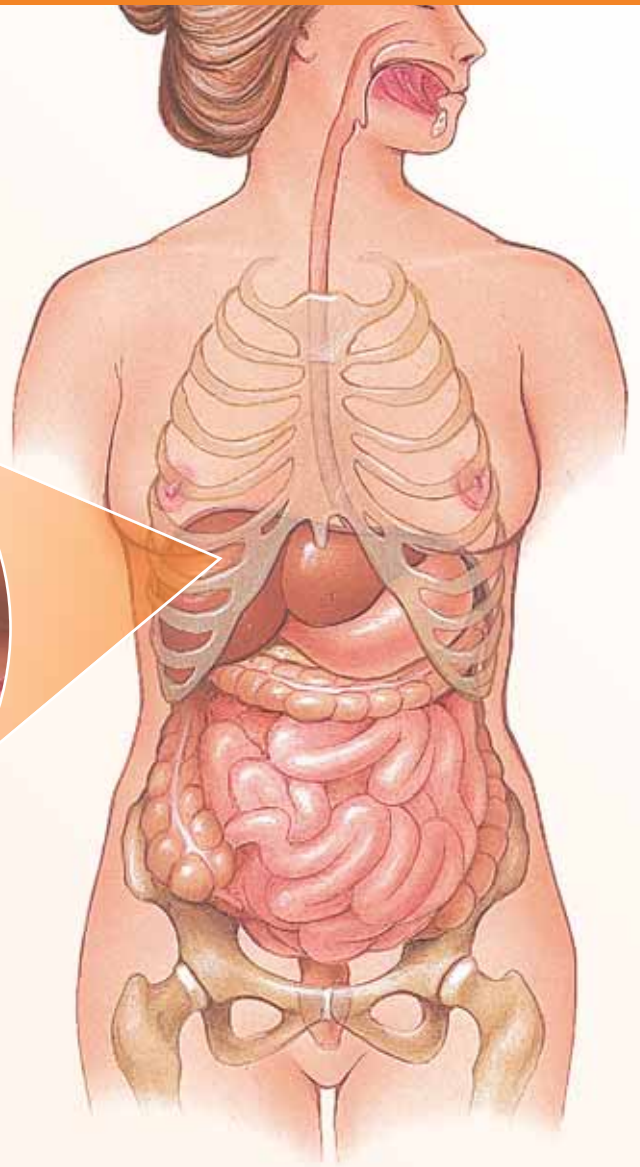
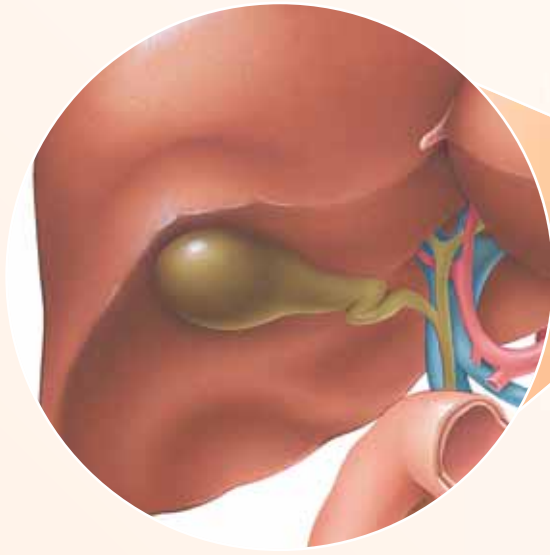
Δῖῖ ḄḄ ḄḄ ḄḄ ḄḄ ḄḄ ḄḄ

Isumaksaqsuurvik

Hivun'nga Qaritaup

Lobe frontal

# Gall Bladder



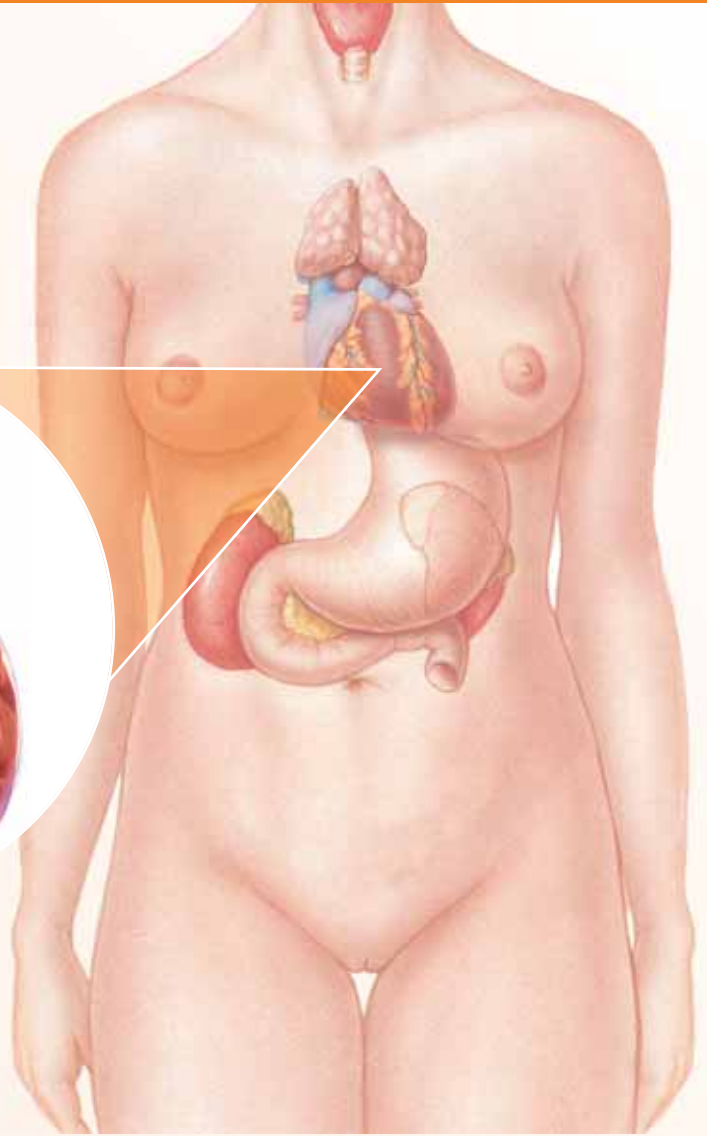
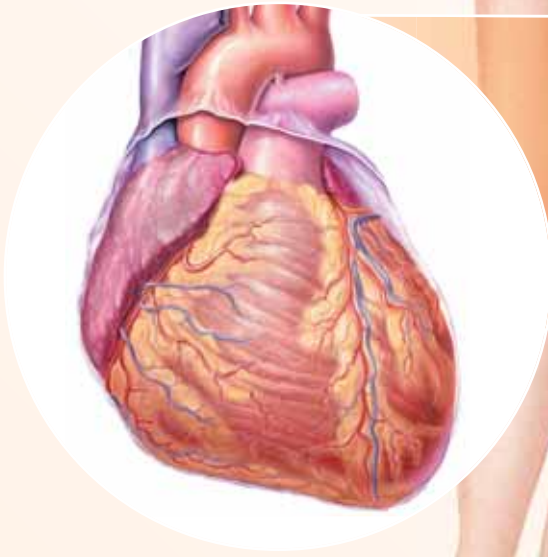
سۇنغاق

Sungaq

Hungaqarvik

Vésicule biliaire

# Heart



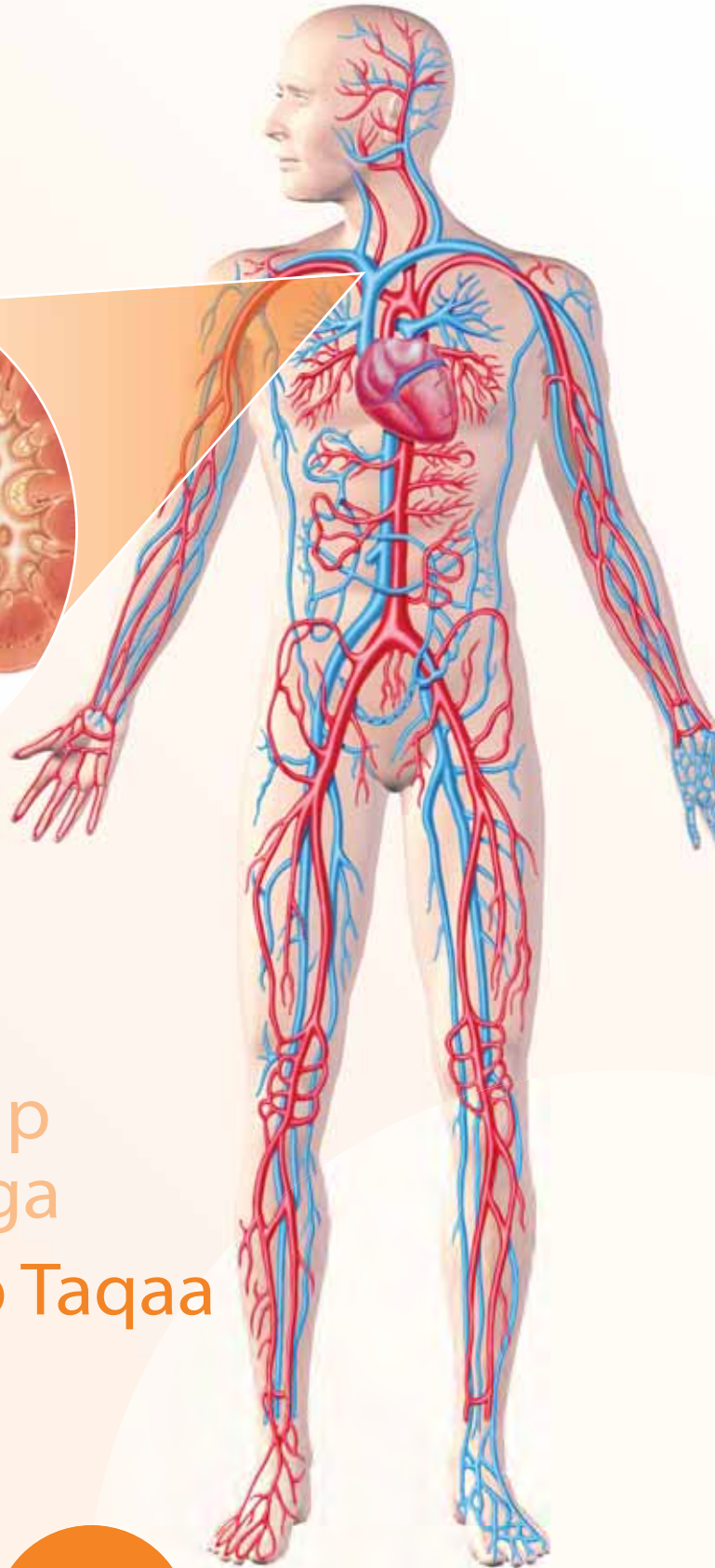
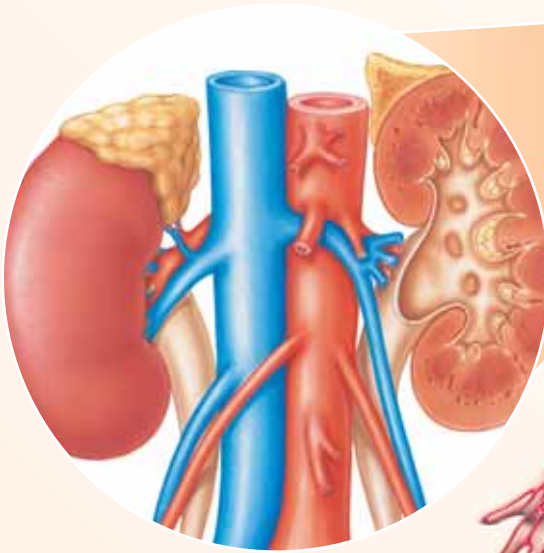
ᐃᐸᐸᐸ

Uummati

Uummat

Cœur

# Inferior Vena Cava



ᐃᐸᐸᐸᐸᐸ  
ᐸᐸᐸᐸᐸᐸᐸᐸ

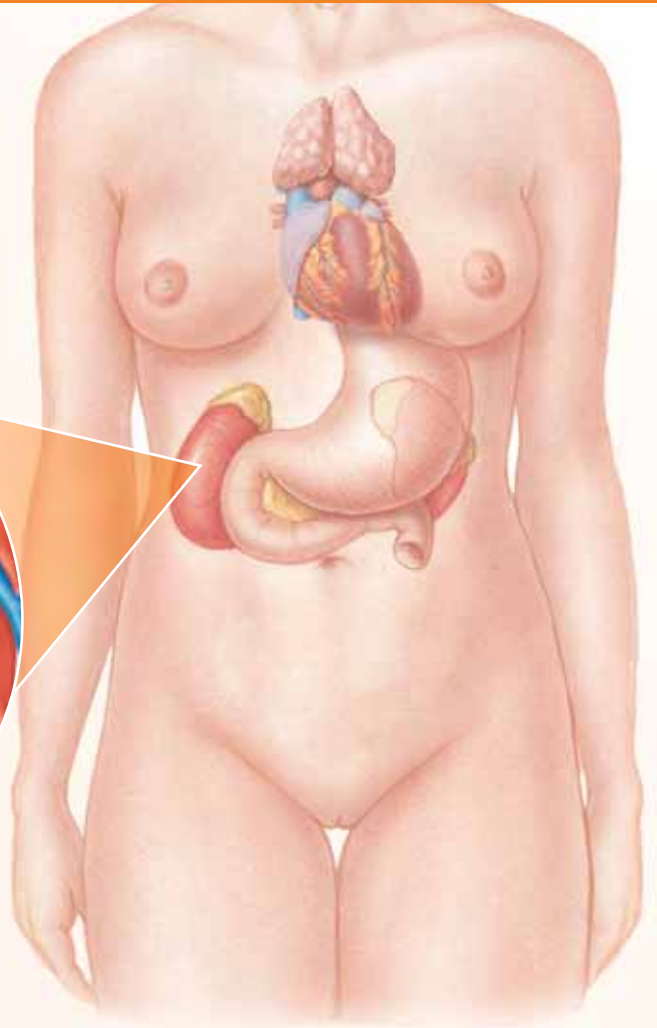
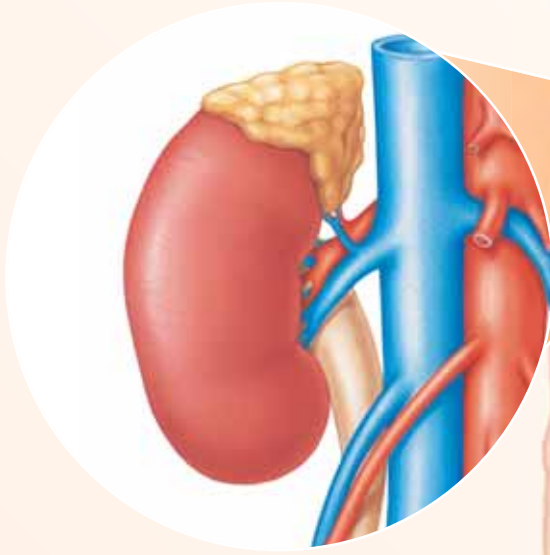
Uummatiup  
Taqarjuanga

Uummatip Taqaa

Veine cave  
inférieure



# Kidney



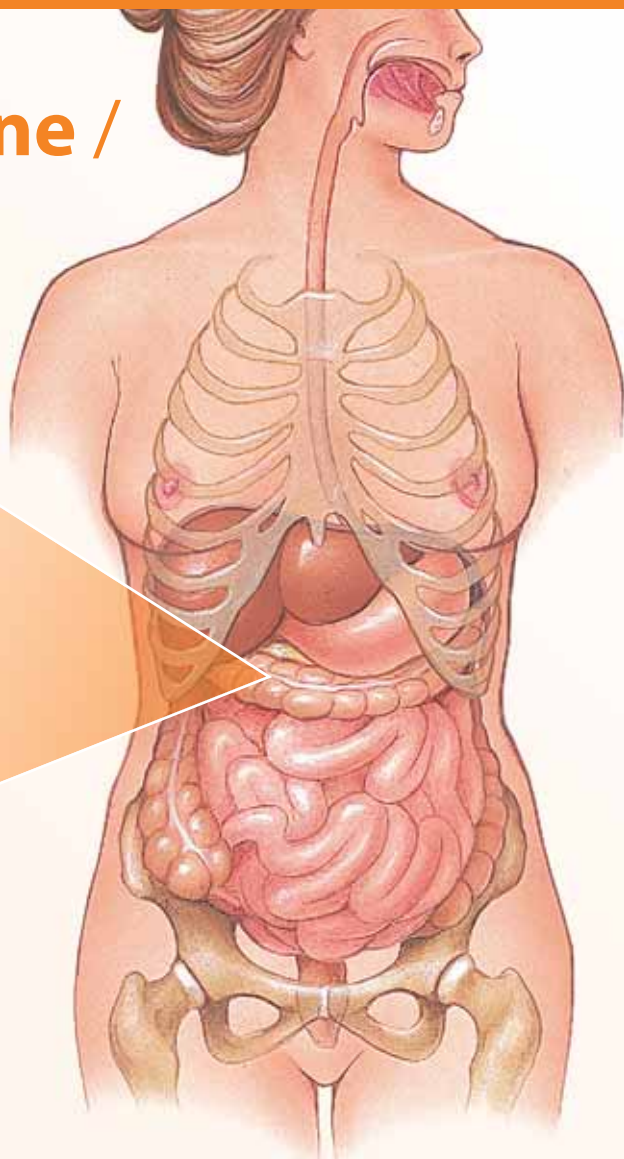
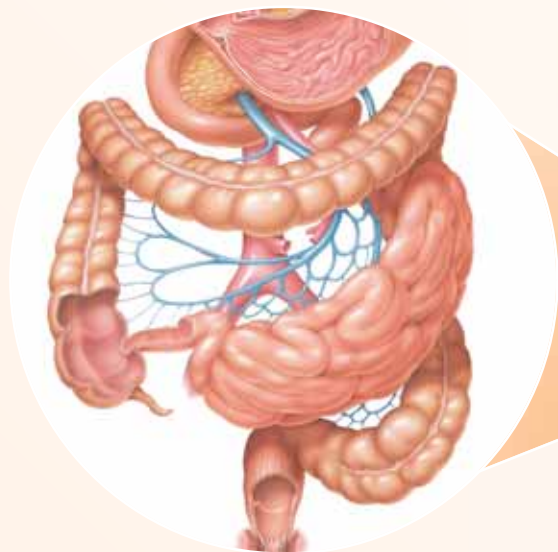
﴿ ٩٦ ﴾

Taqtu

Taqtu

Rein

# Large Intestine / Colon



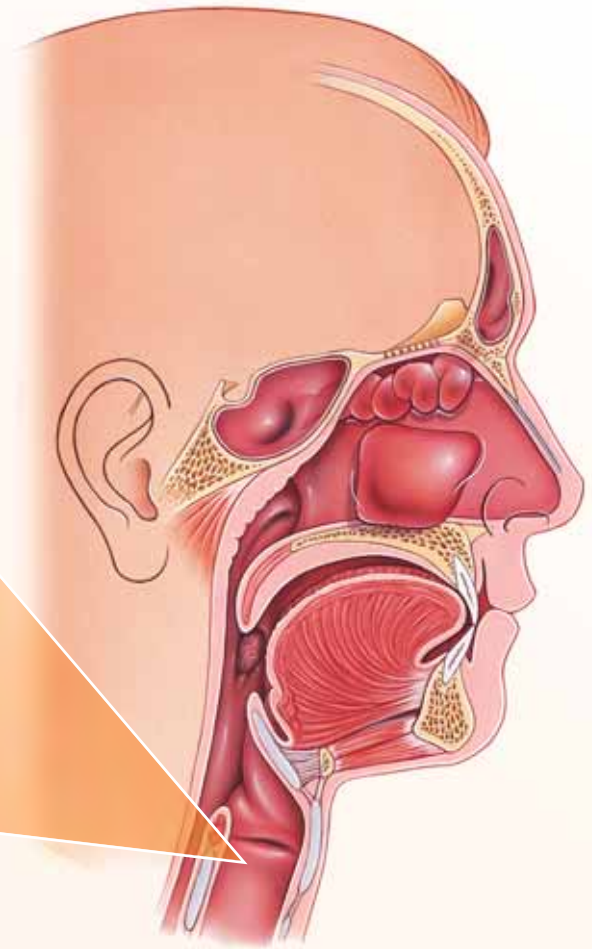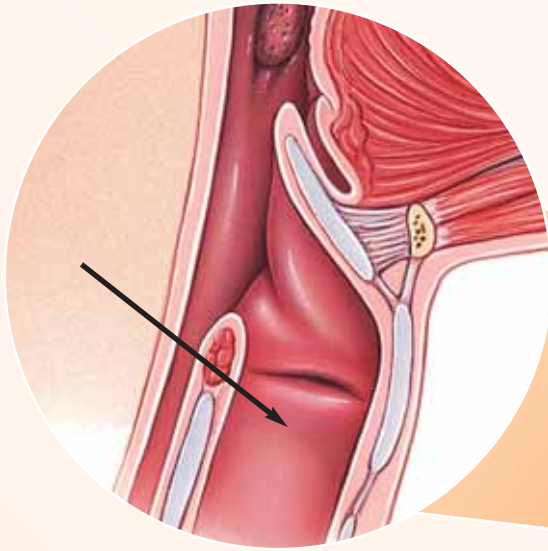
ᐱᐱᐱᐱᐱ

Anavauti

Ingaluat/Iqhuq

Gros intestin, colon

# Larynx / Voice Box



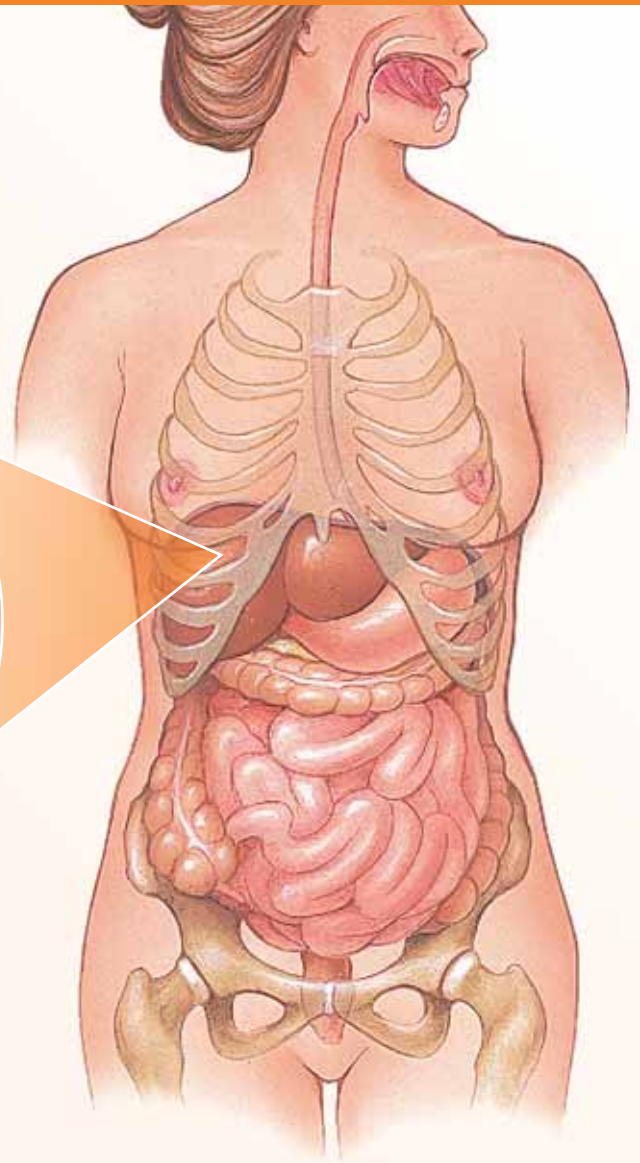
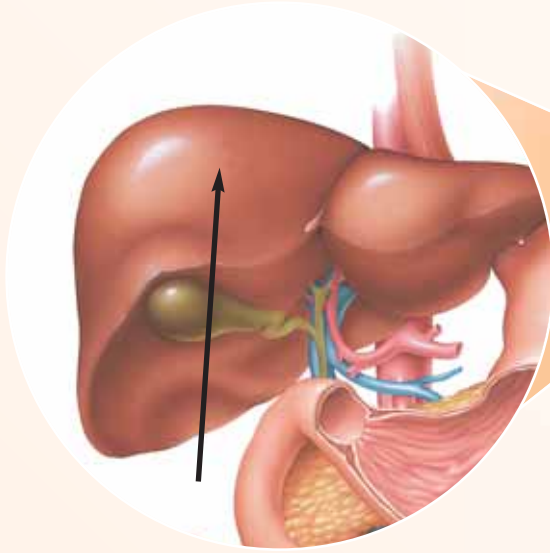
ᐅᑦᑲᑦᑲᑦ

Tuqqujaak

Nivyaarvik

Larynx

# Liver



Ո՛ՅԽ

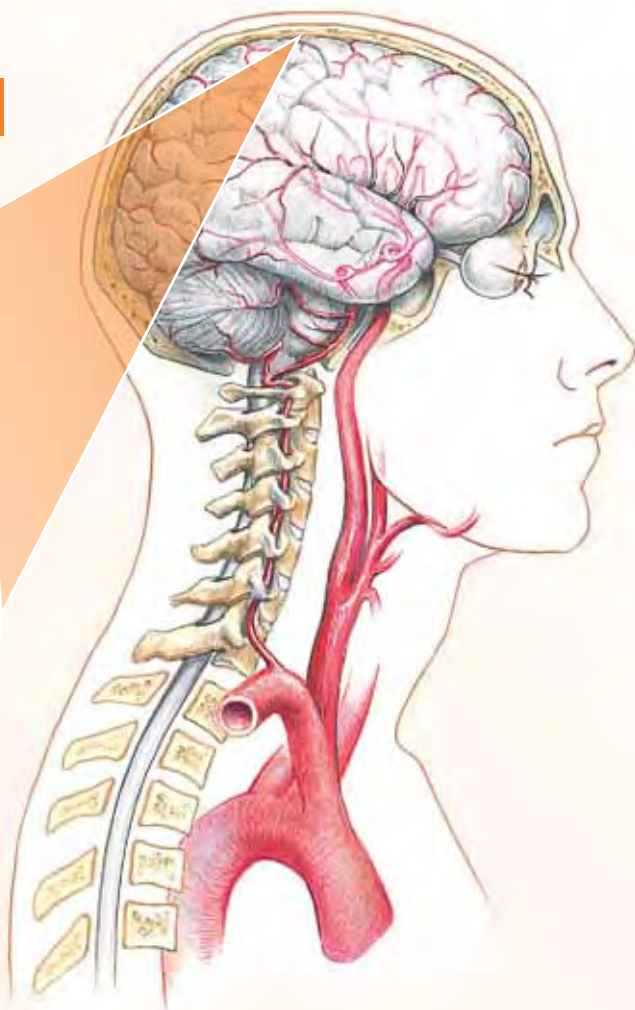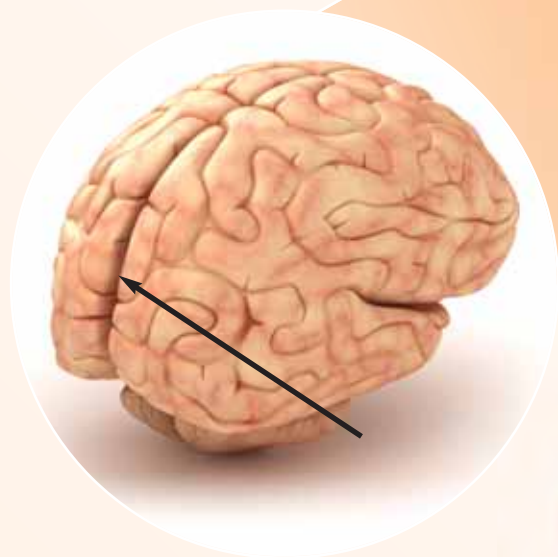Tinguk

Tinguk

Foie



# Longitudinal Cerebral Fissure



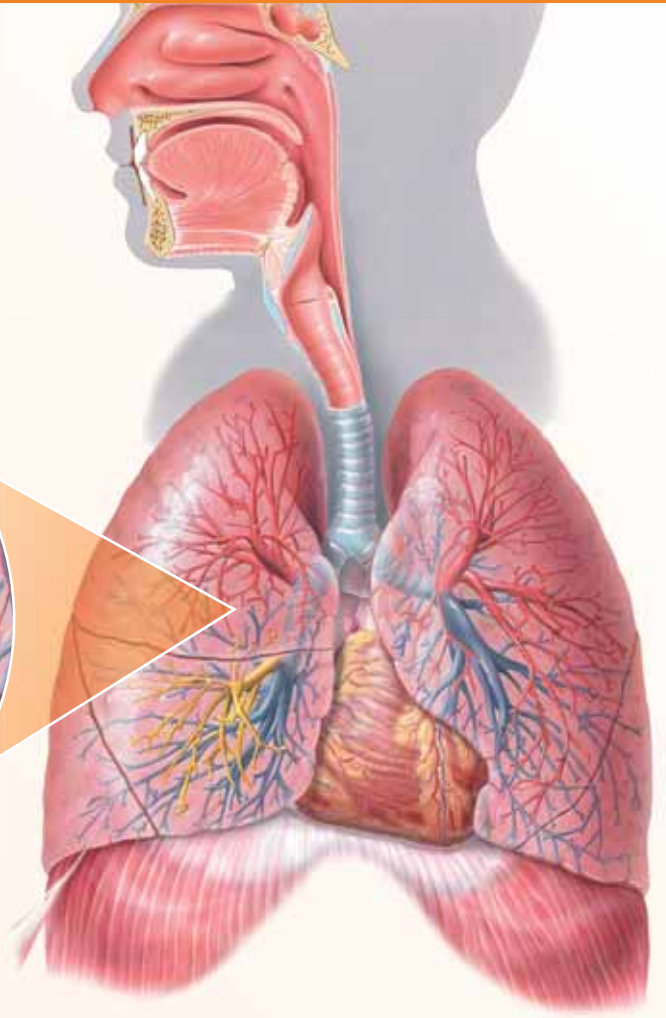
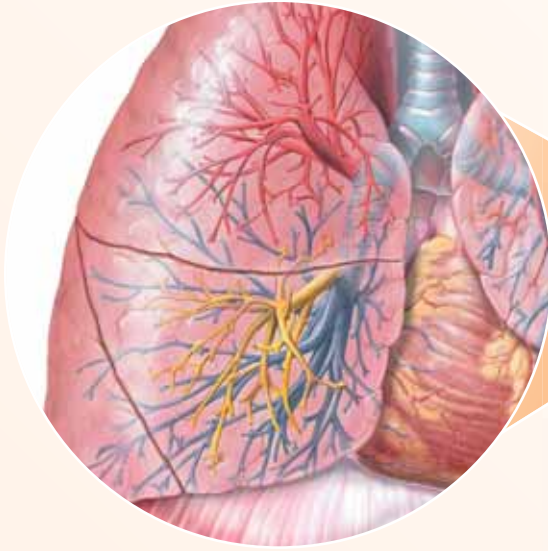
Λ ς σ ς β

Pirniq

Akulvirutaa

Scissure inter-hémisphérique

# Lung



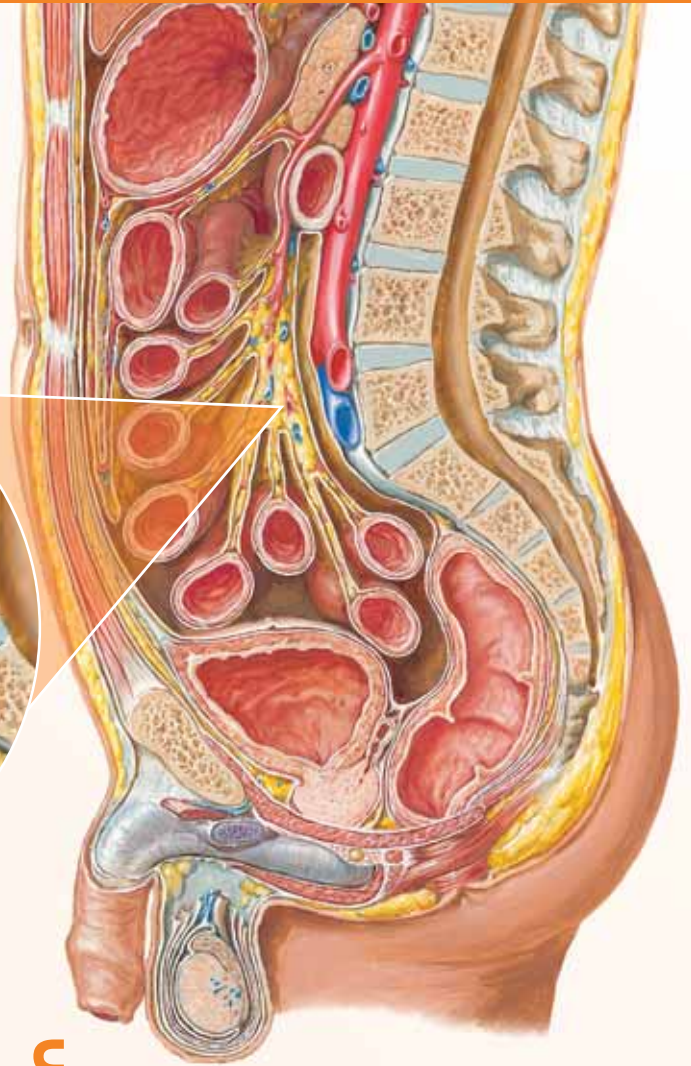
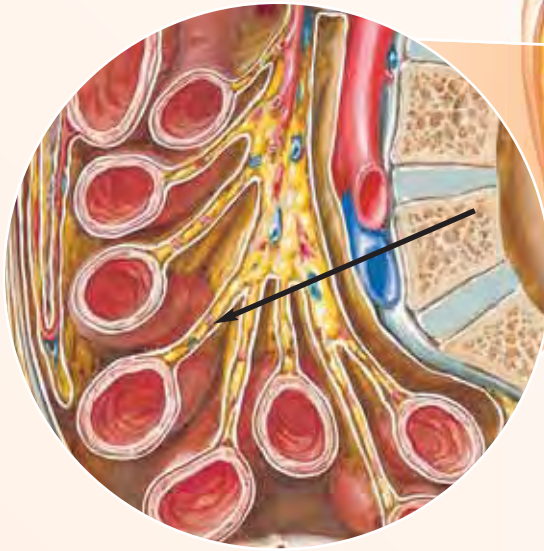> ୧୦୬

Puvak

Puvak

Poumon

# Mesentery



Δῆσάϙ ἰῆϙ

Irraviit Puungat

Kikhaut

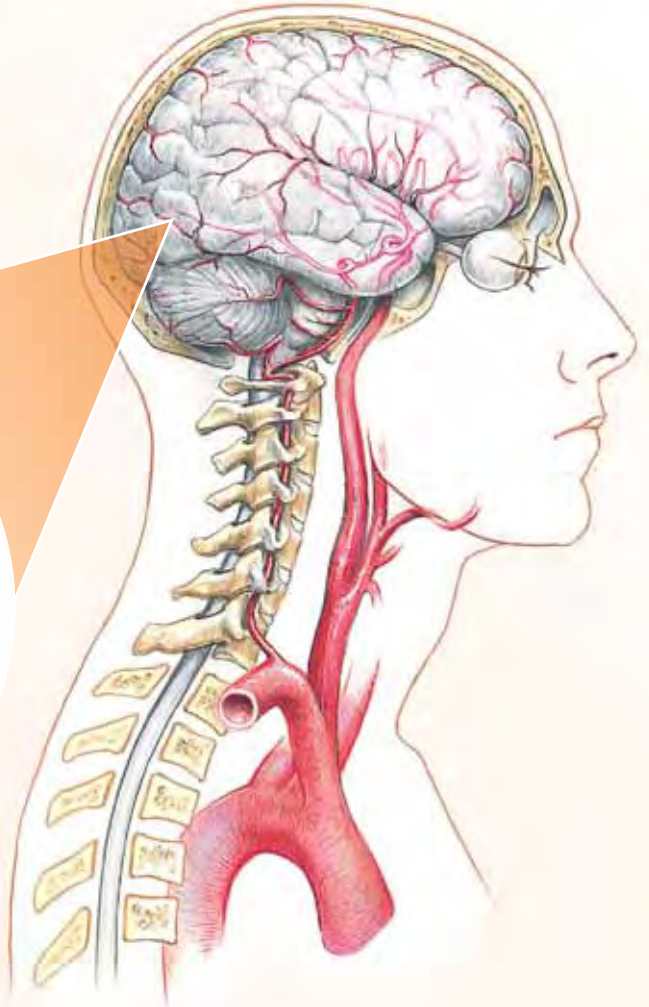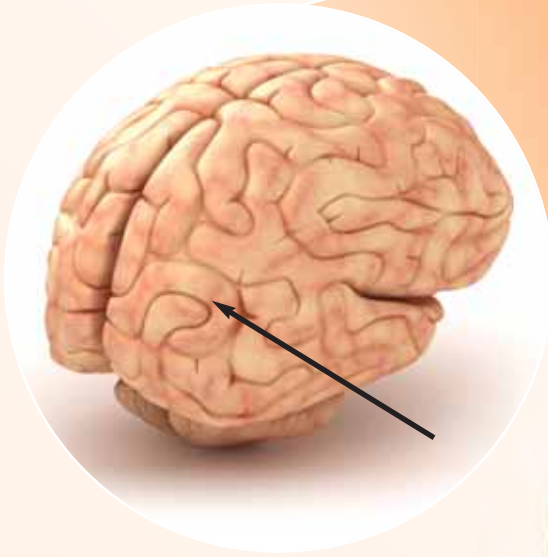Mésentère







# Parietal Lobe



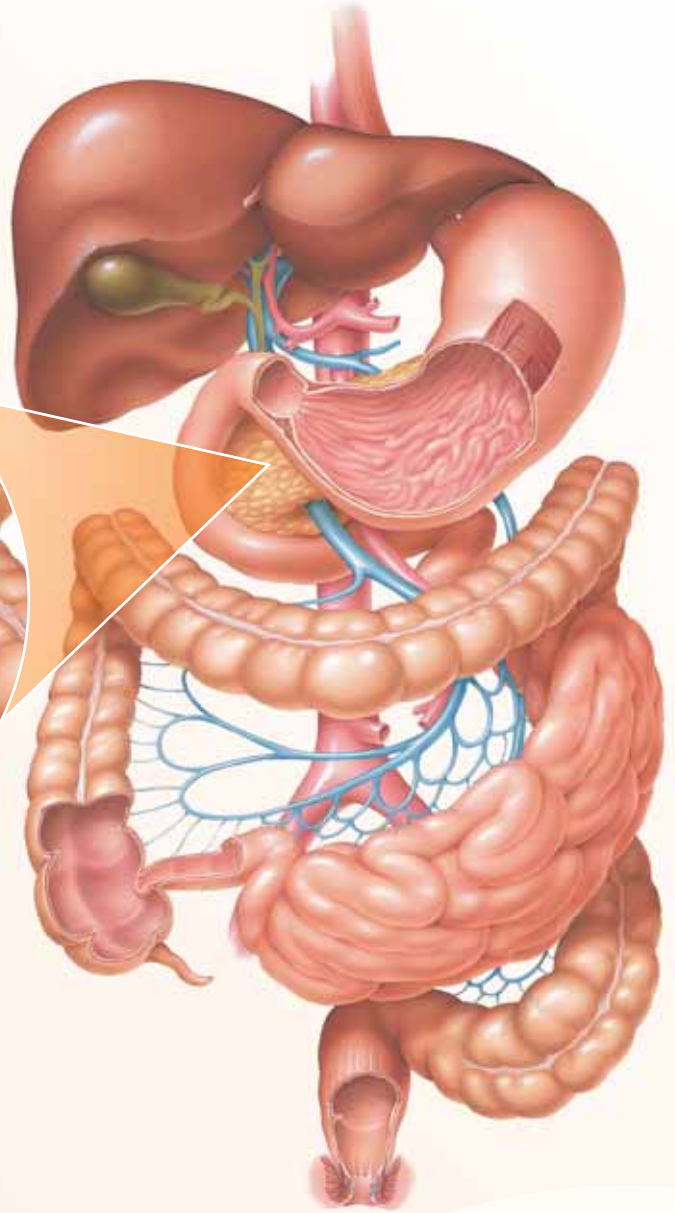
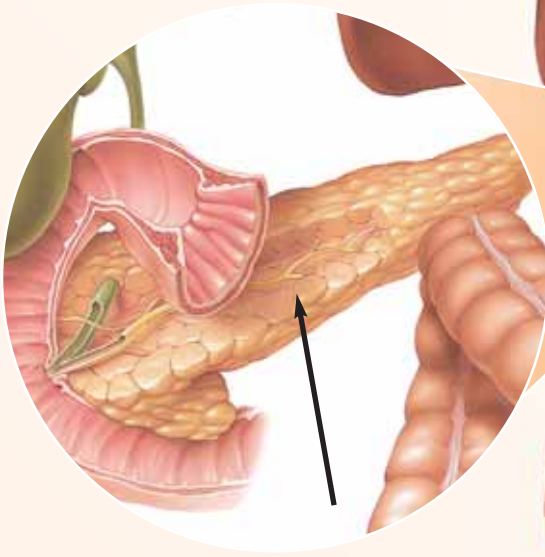>ΔJñ<sup>b</sup>d<sup>c</sup> Δ<sup>9</sup>b<sup>b</sup>▷L<sup>3</sup>↵<sup>c</sup>

Puiguriikkut Iqqaumajjut

Qitqa Qaritaup

Lobe pariétal

# Pancreas



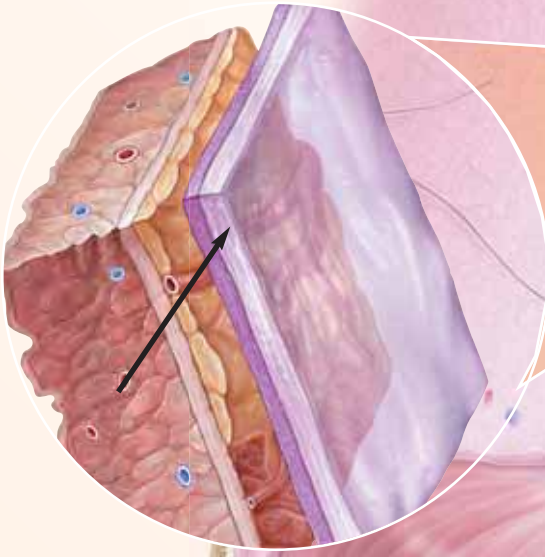
ᐅᐃᐅᐅᐅᐅᐅ

Qiksalikaaq

Nigvik

Pancreás

# Pericardium



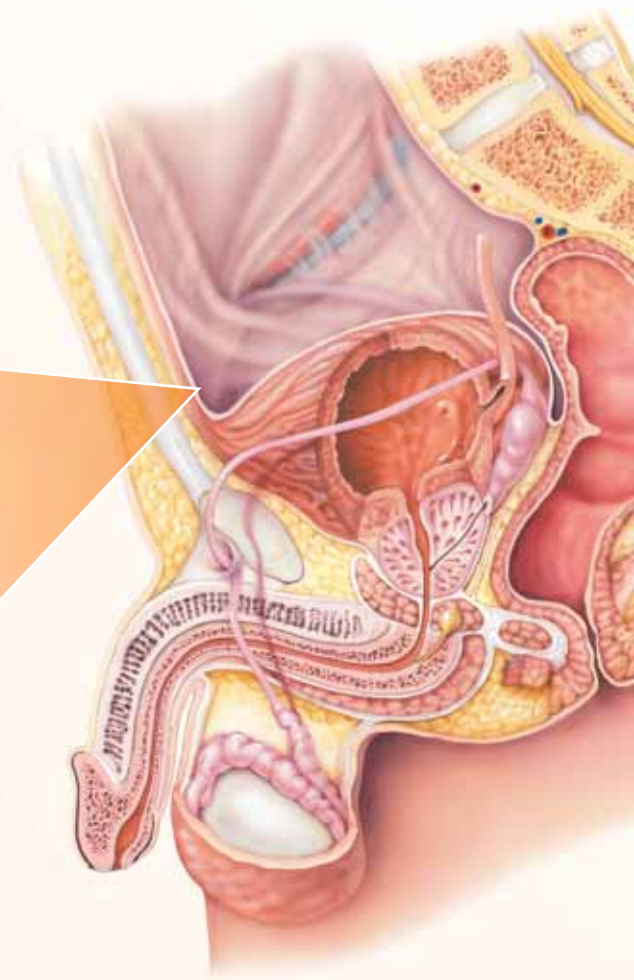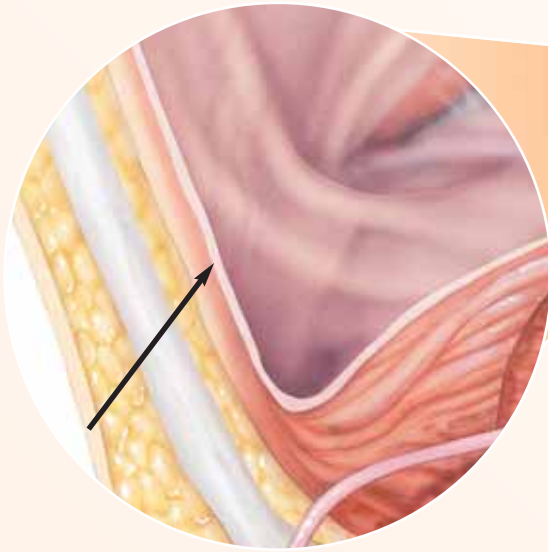
б6АPԳԵ

Kavisiq

Kapihiaq

Péricarde

# Peritoneum



Δ⁹⁹ΔcĬ< >⁹ᵁ

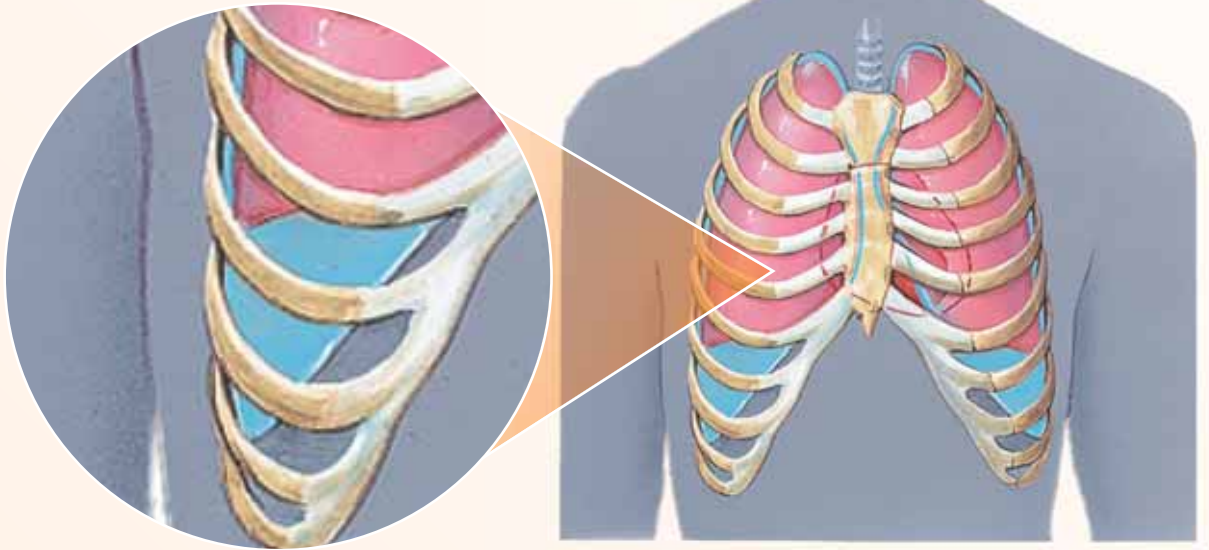
Irravilimaap Puunga

Ilraviit

Péritoine



# Pleura



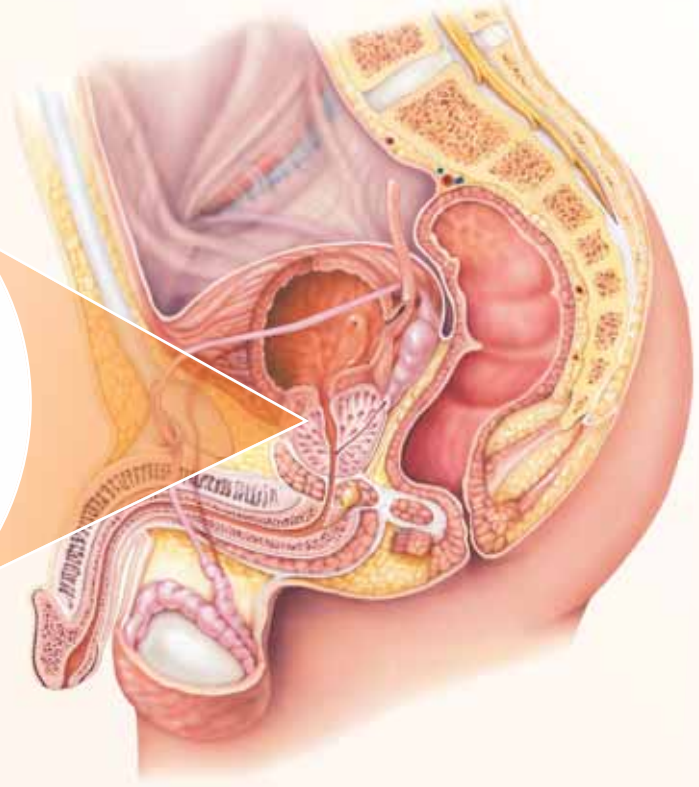
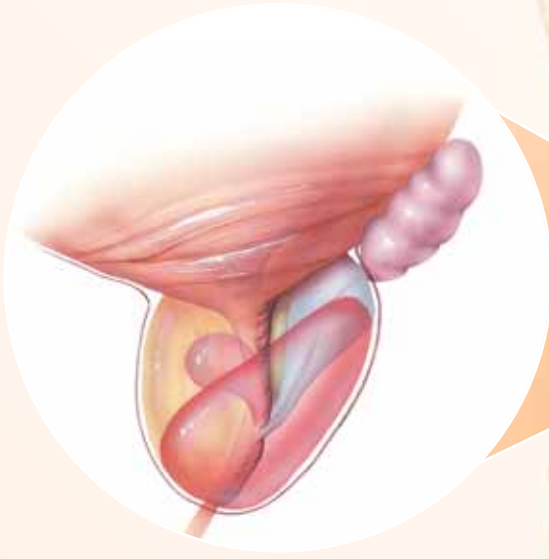
ᐱᐅᐅᐅᐅ ᐅᐅᐅᐅᐅᐅ

Puvaup Qaapaanga

Maminguyaq

Plèvre

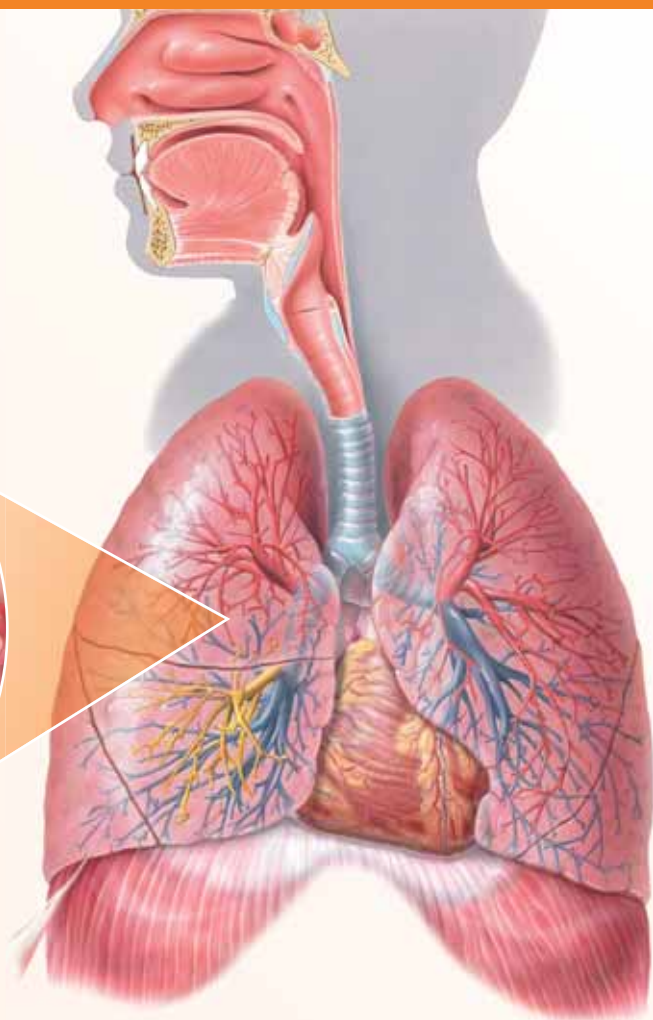
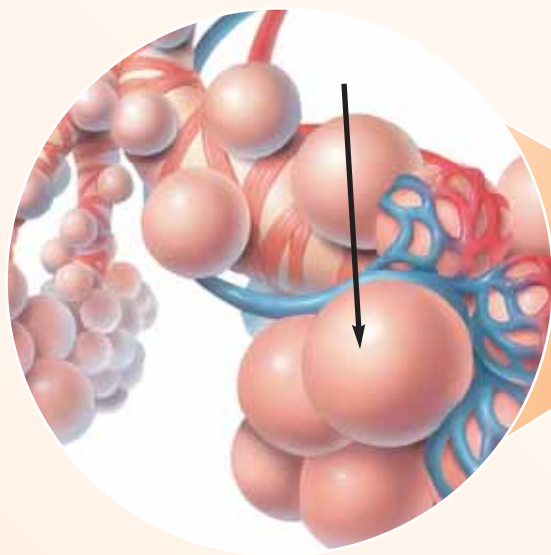
# Prostate



ᐱᓄᓄᓄᓄᓄᓄᓄᓄ

Sungiliq  
Nunudjut  
Prostate

# Pulmonary Alveolus



ᓄᓐᓂᓐ ᓂᓐᓂᓐ

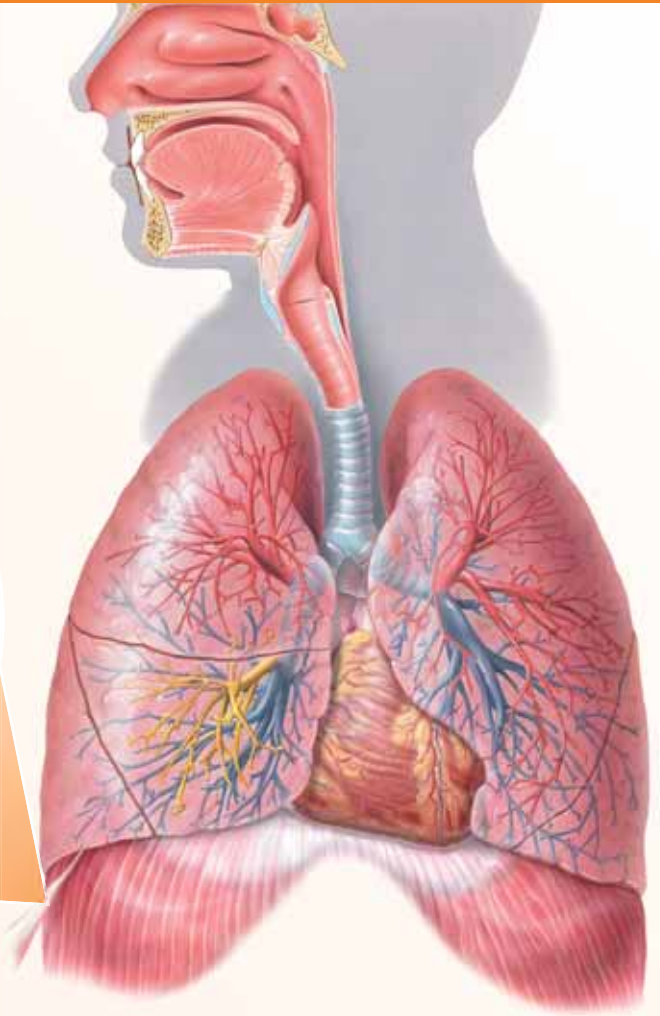
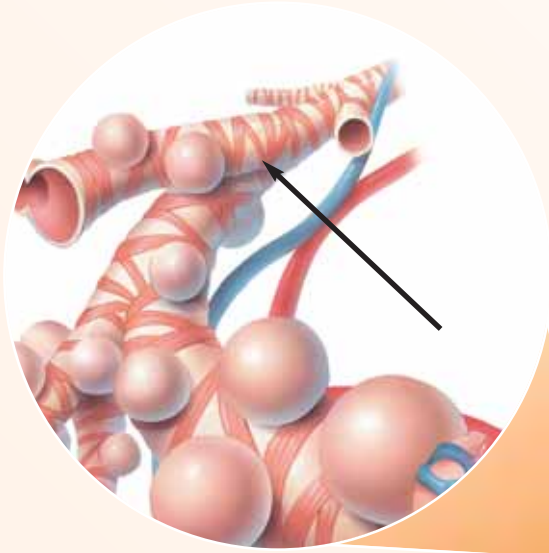
Nuviqłuit

Anniqhaaktarniup

Halummaqhitait

Alvéole pulmonaire

# Pulmonary Artery



ᐅᐅᐅᐅ ᐅᐅᐅᐅᐅᐅᐅᐅ

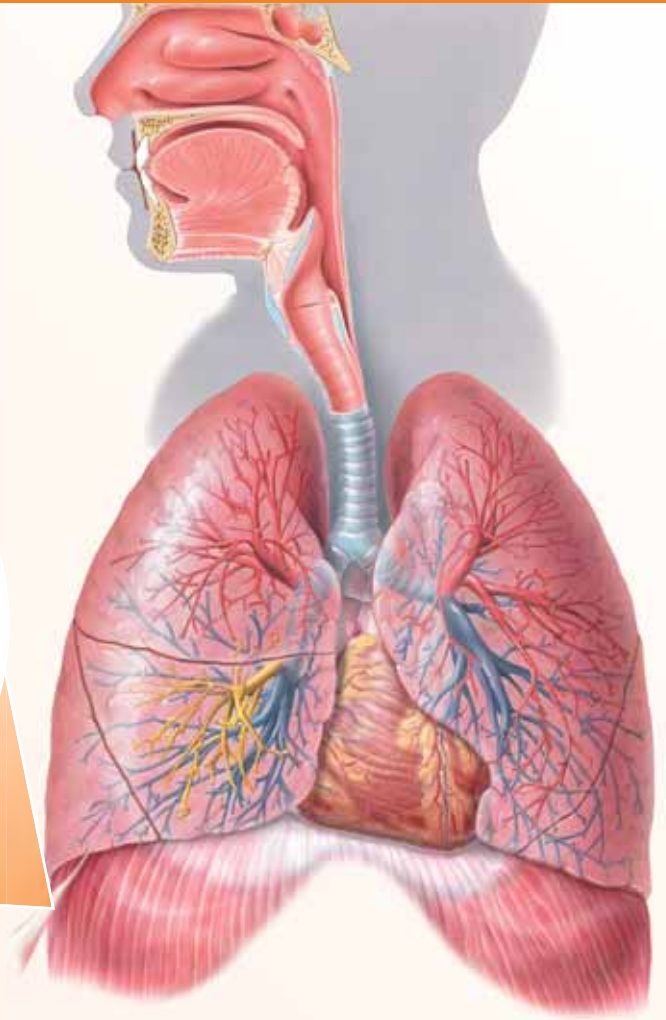
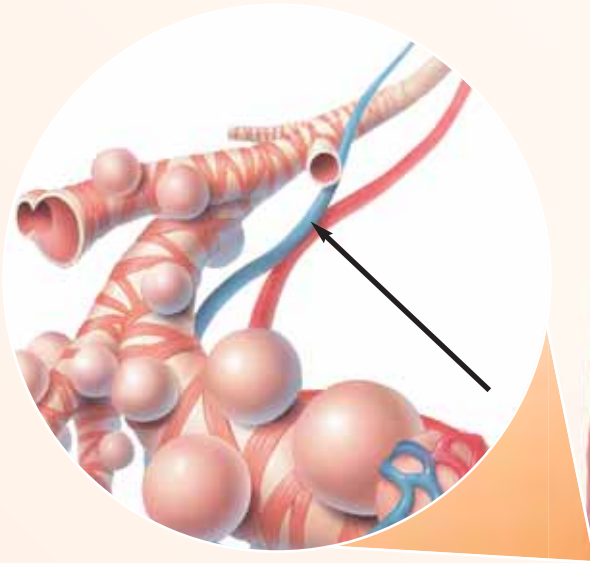
Puvaup Taqarjuanga

Puvaup Taqakpagyuanga

Artère pulmonaire



# Pulmonary Vein



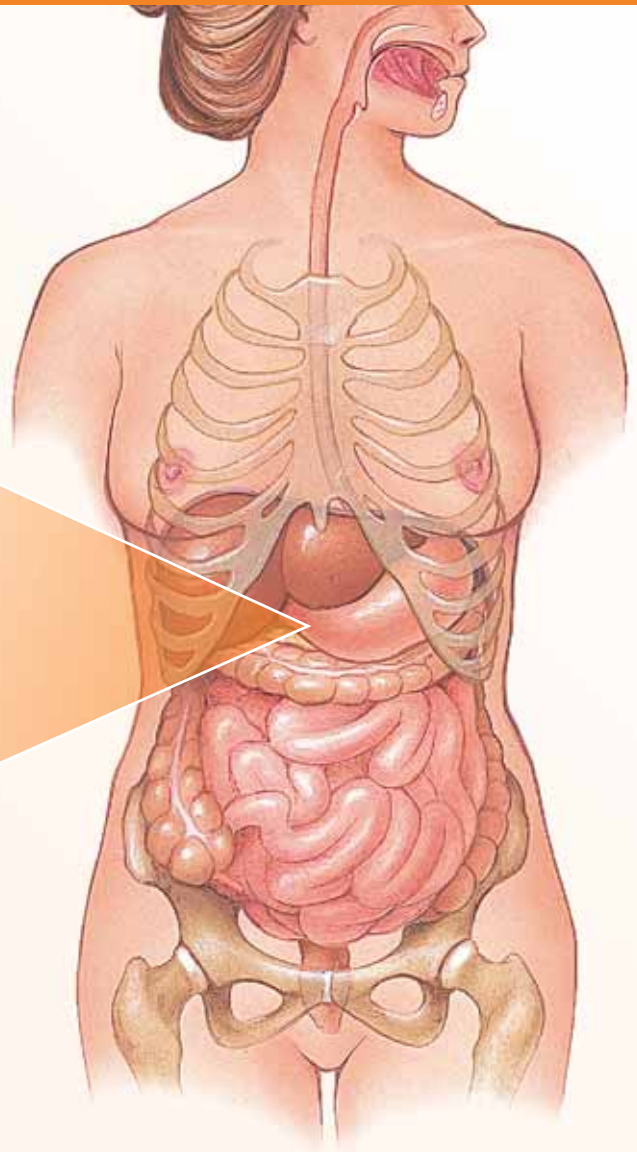
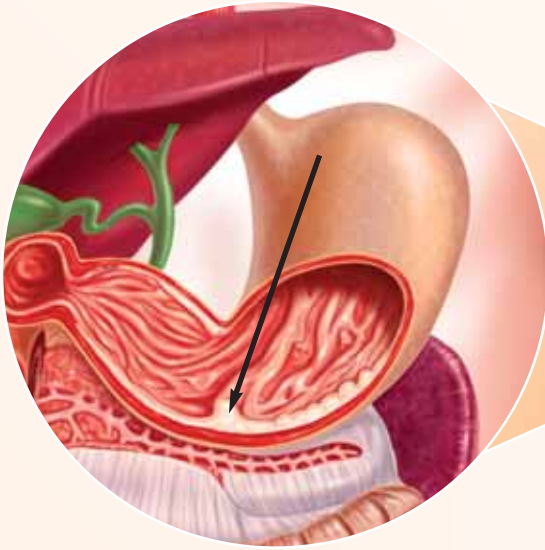ጎጂጎጎጎ ርፍጌጌ

Puvaup Taqanga

Puvaup Taqaa

Veine pulmonaire

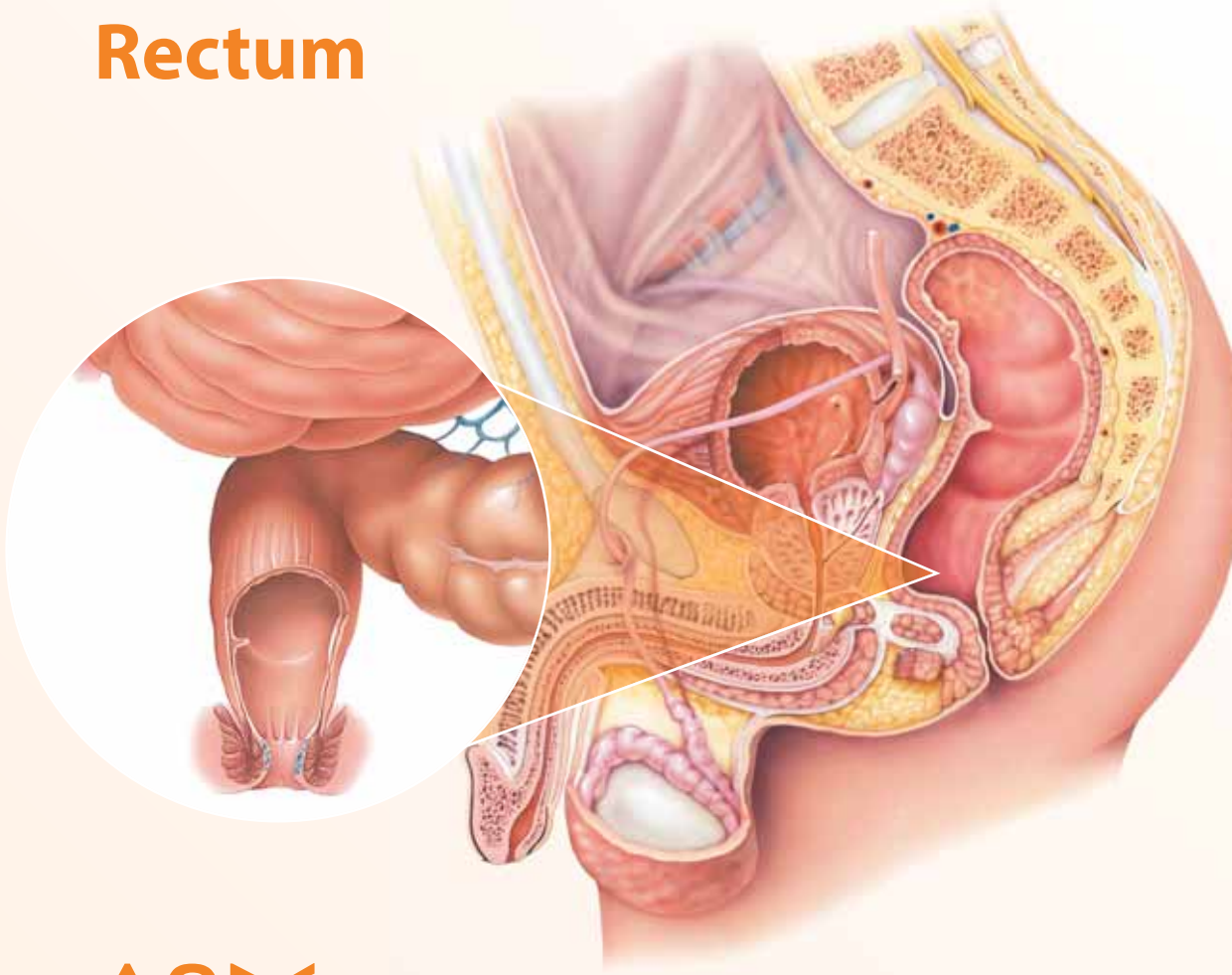
# Pylorus



ᐃᑦᓱᐃᓱᑦᓴᑦ  
ᐃᑦᓱᑦᑦᑦᑦᑦᑦ

Aqiarurmiit Aqiglisarvia  
Natiqhinak  
Pylore

# Rectum

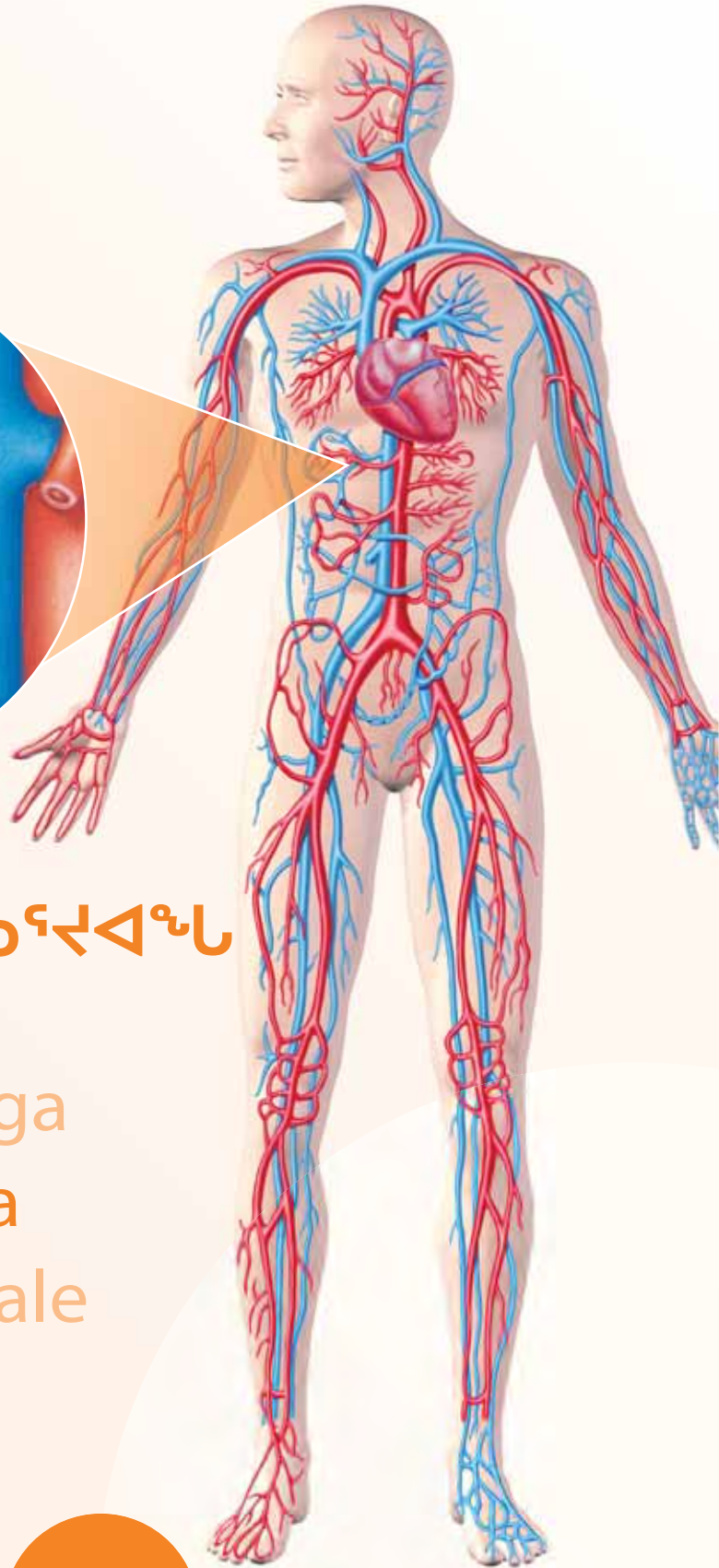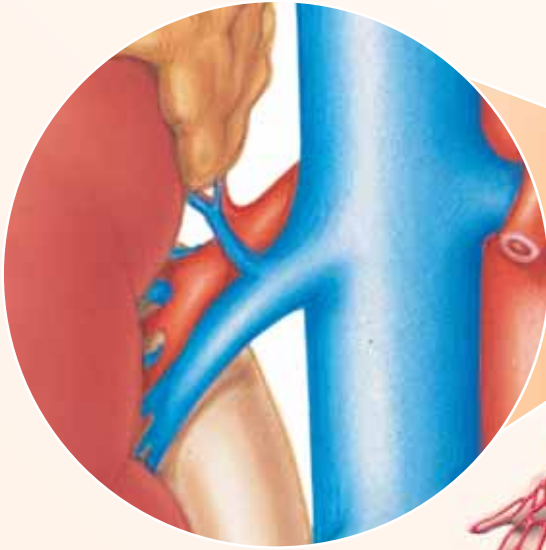


ΔΝΔ<  
Δ&ΓΔÇ

Itiup Ungiutaa  
Iqhuup Kiglinga  
Rectum



# Renal Artery



ᑕᑦᑲᑕᑦ ᑕᑦᑲᑦᑲᑦᑲᑦᑲᑦ

Taqtuup

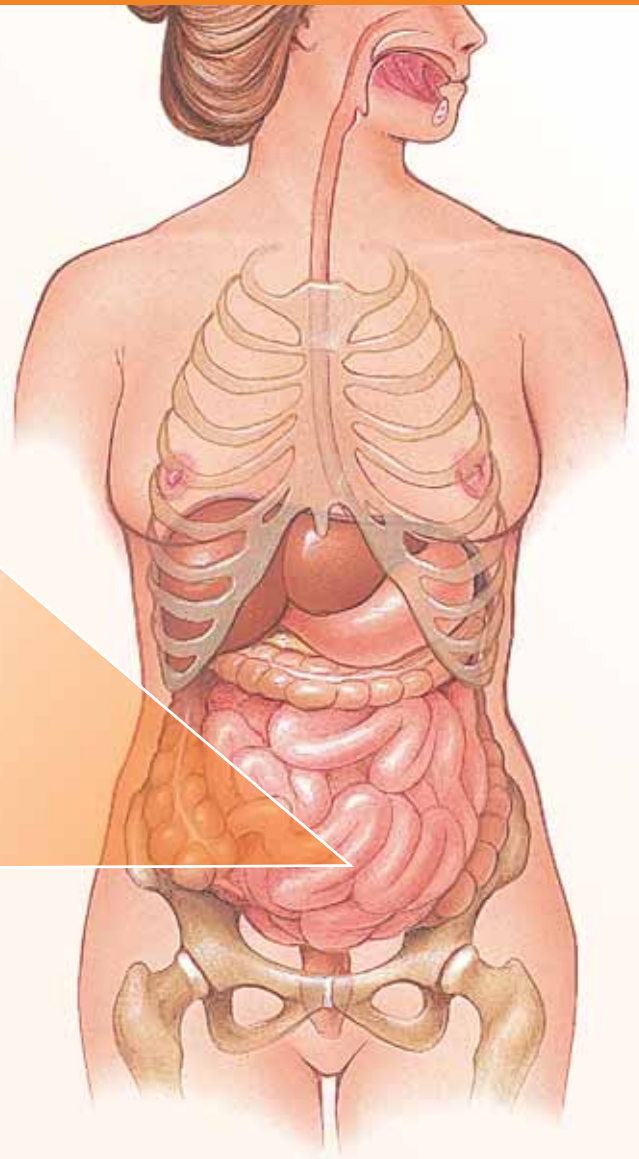
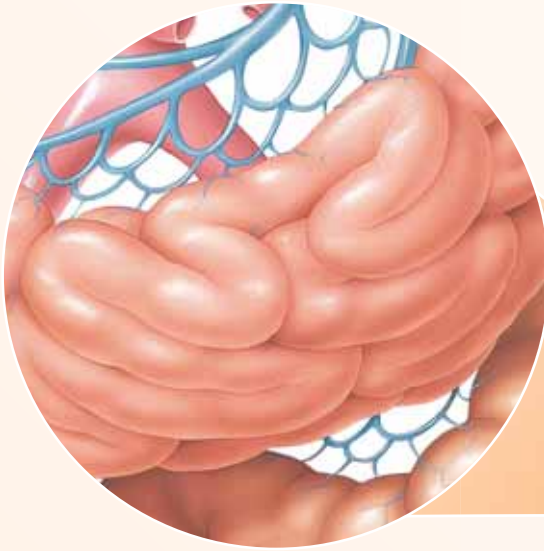
Taqarjuanga

Taqaqarvia

Artère rénale



# Small Intestine



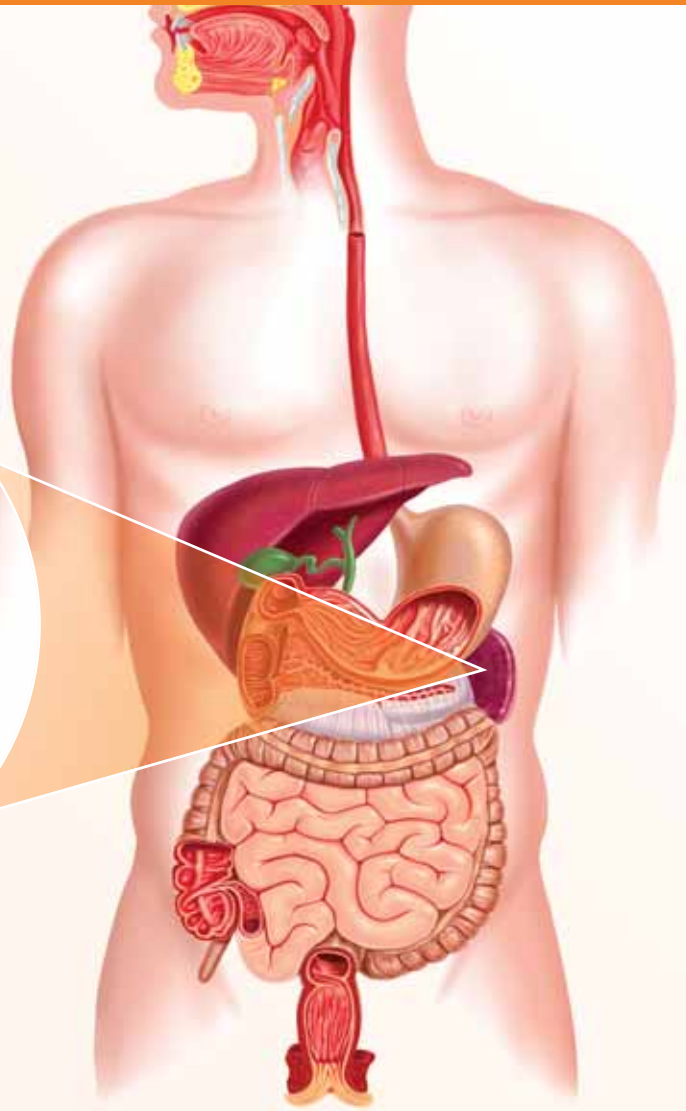
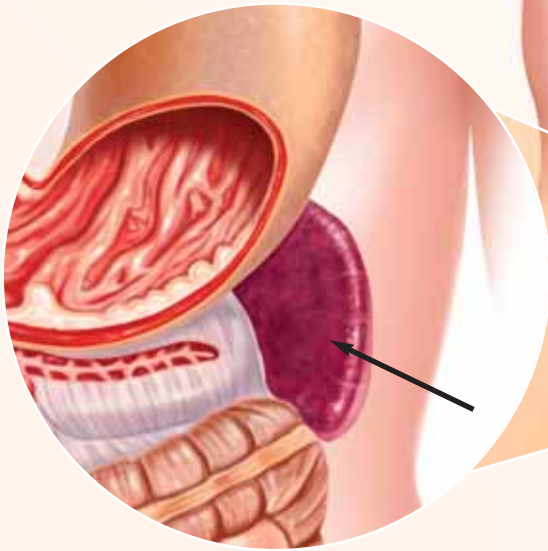
ᐃᓄᓂᐱᓂ

Inaluat

Ingaluaq

Intestin grêle

# Spleen



LC५

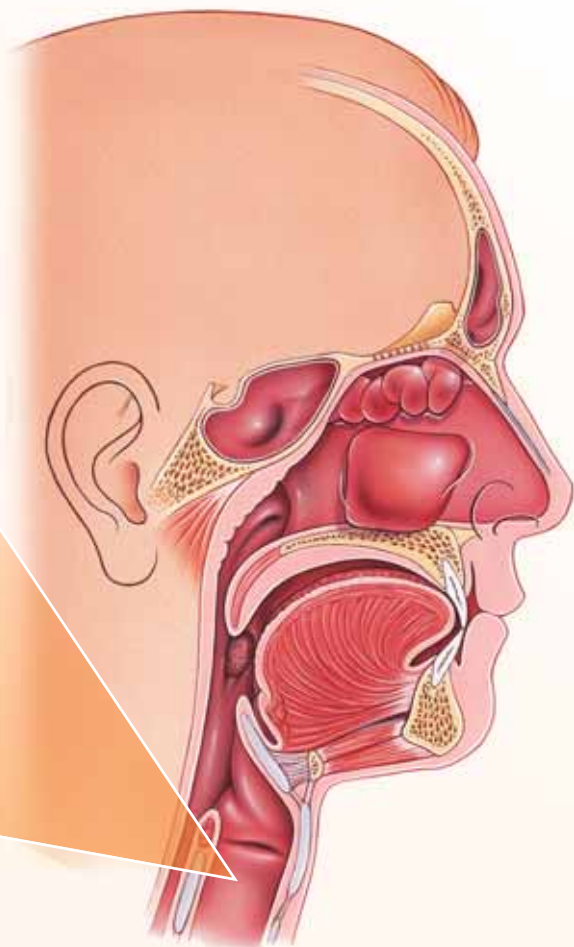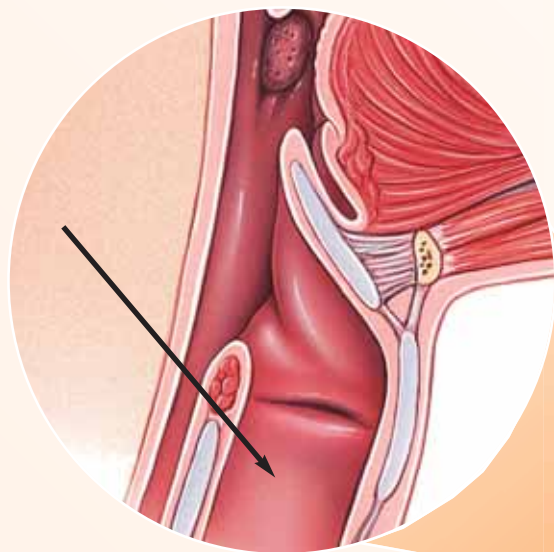
Matsa

Maffa

Rate



# Throat, Esophagus



ᐃᐅᐅᐅᐅᐅᐅ

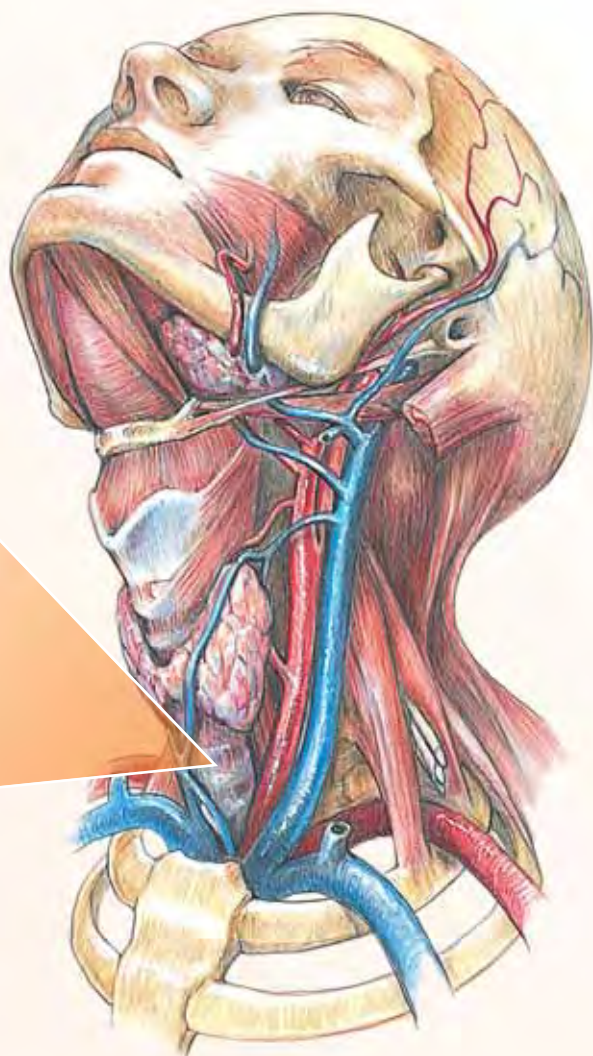
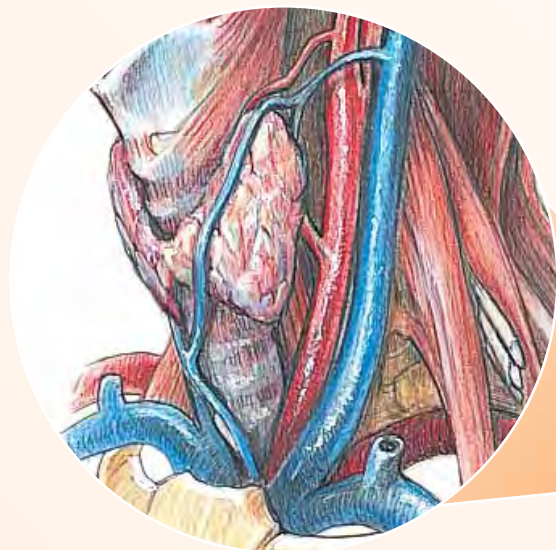Iggiaq

Tuqhuk

Gorge, œsophage



# Trachea / Windpipe



ᑕᑦᑲ ᑲᑦ

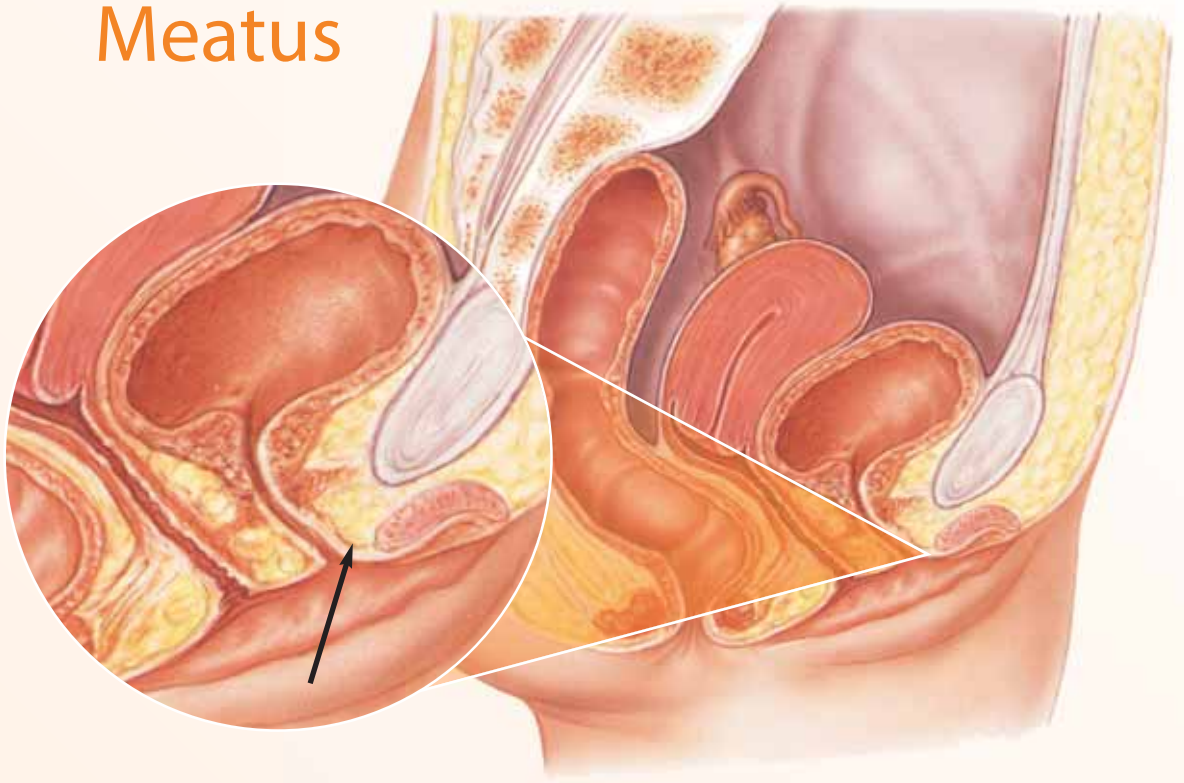
Tuqłuk

Iggiapquq

Trachée



# Urinary Meatus



ᑭᑦᑕᑦᑎᑦᑕᑦᑕᑦᑕᑦ

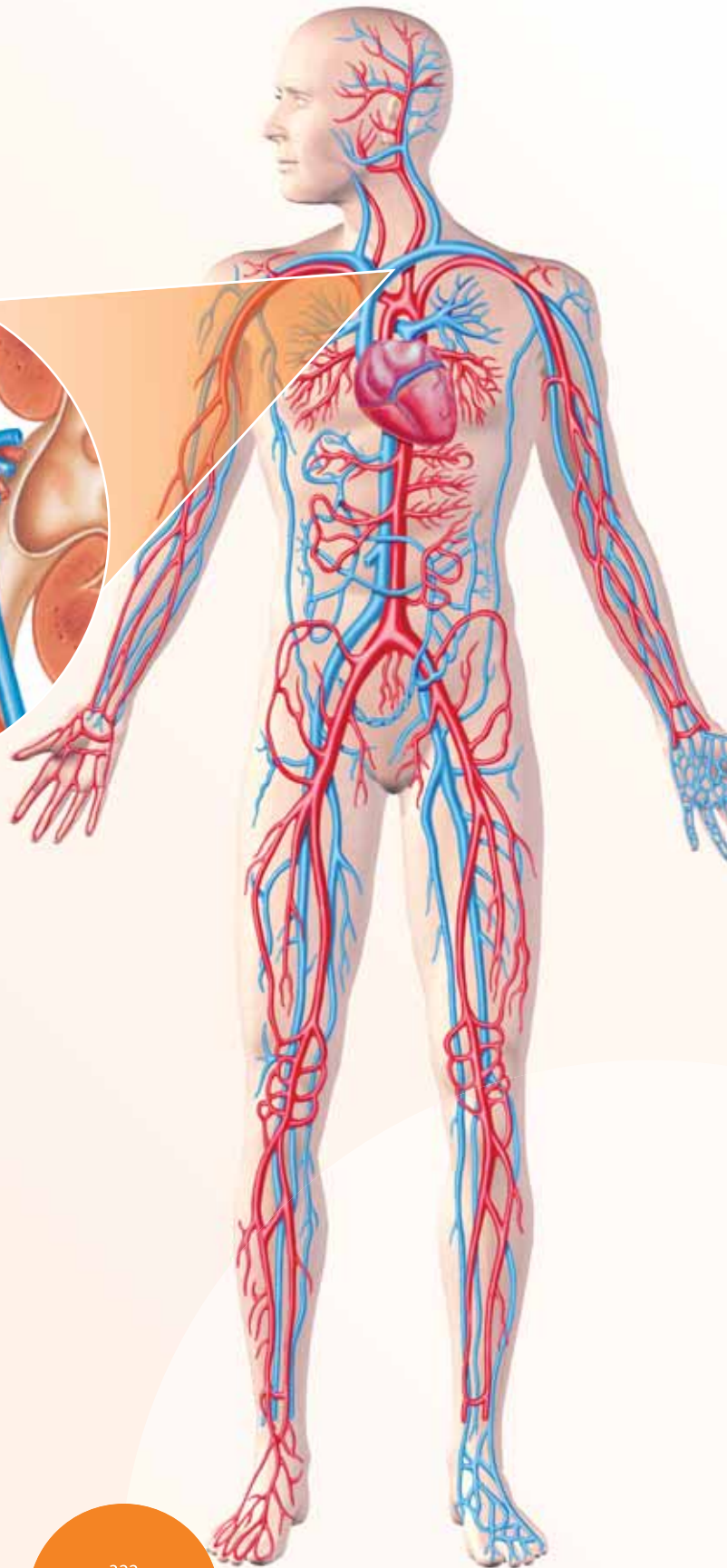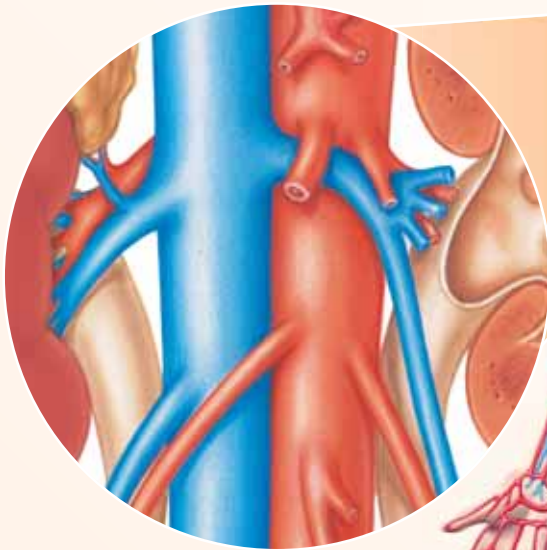
Qurrivik

Nakahuup Nuvua

Méat urinaire



# Vein



Сʻбʻ

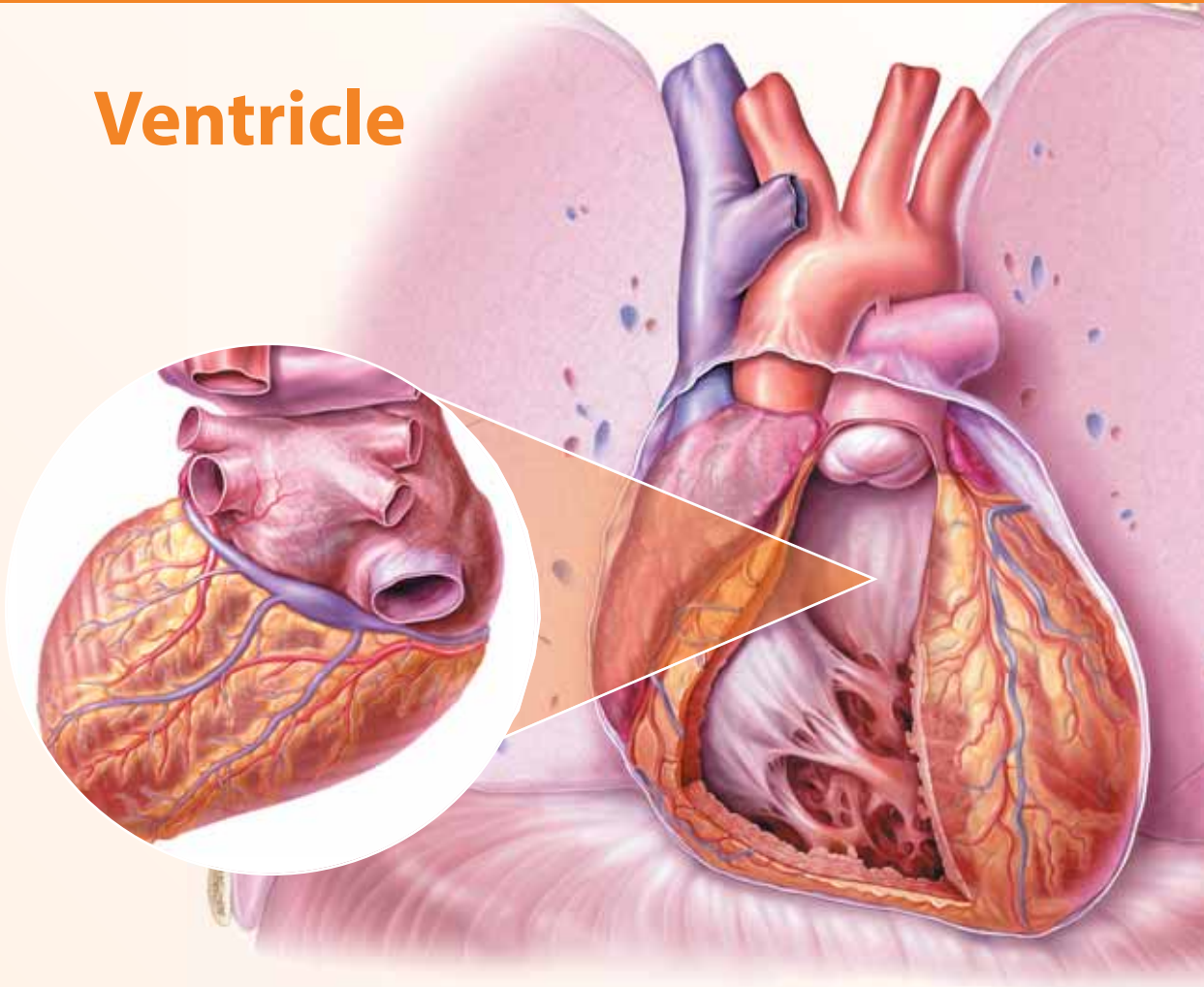
Taqak

Taqak

Veine



# Ventricle



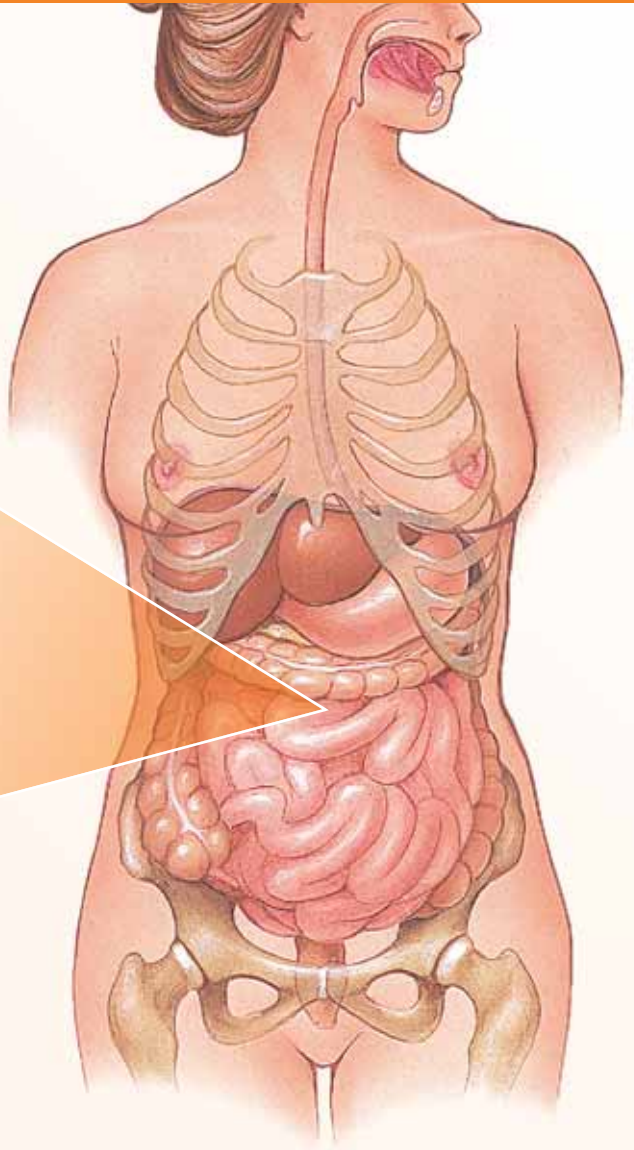
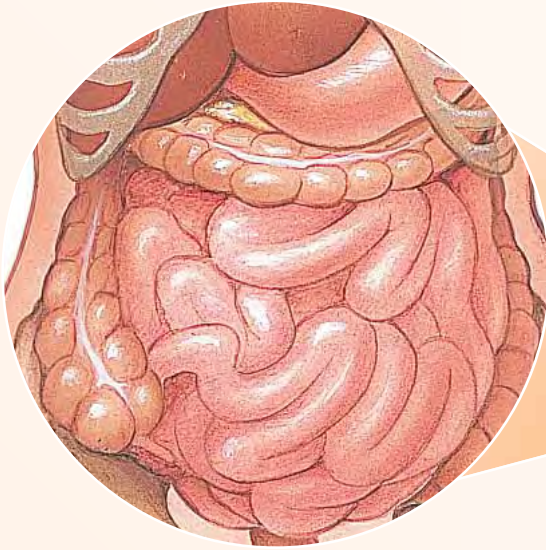
ᐃᓕᓕᐢᐢᐱᓂᓂᐱᐱᐱᐱᐱᐱᐱᐱᐱᐱ

Uummatimiittuq Auqauti

Uummatip Auqarvia

Ventricule

# Viscera



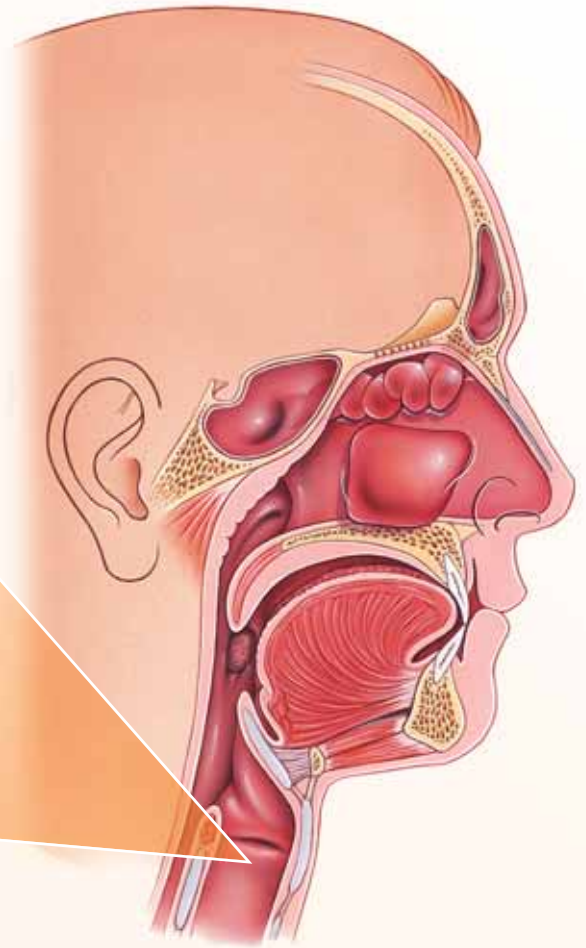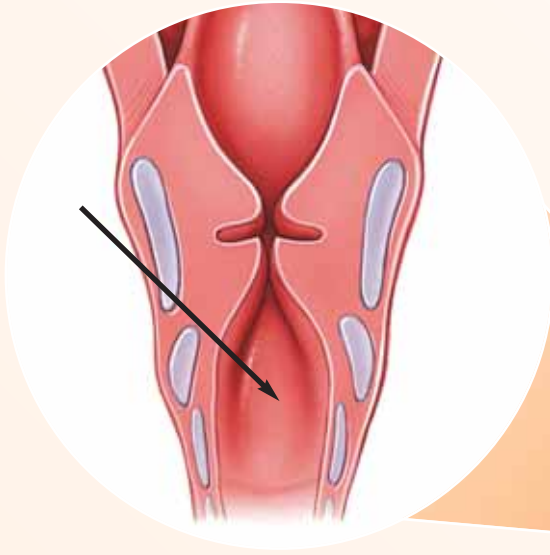
ᐃᑦᑦᐃᑦ

Irraviit

Ilraviqarvik

Viscères

# Vocal Cords



σΛ⁹b▷ᶜ

Nipiqaut

Nipiqarvik

Cordes vocales





# Skeletal System

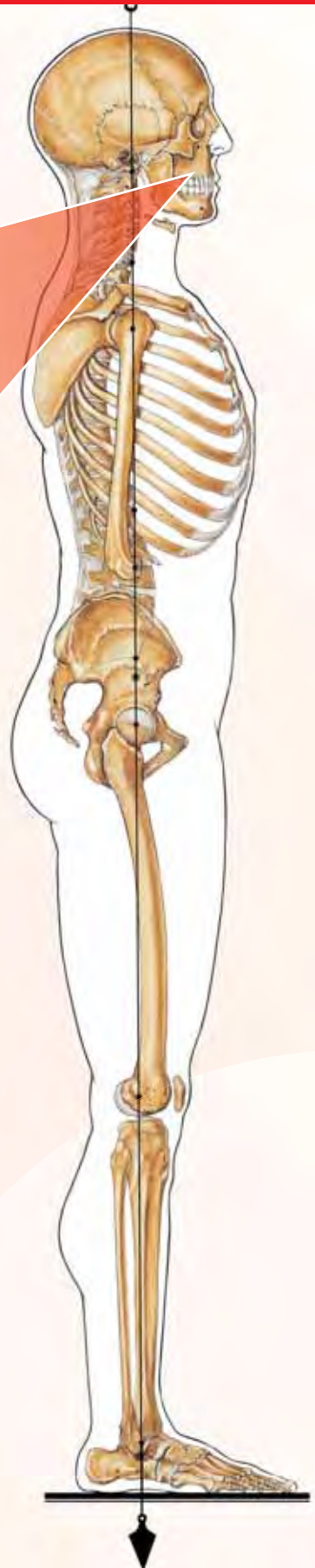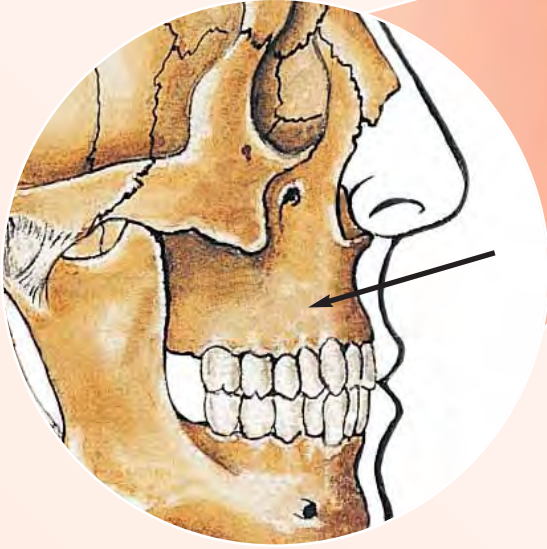
ህጋዕር

Sauniit

Timip Hauniit

Squelette

# Alveolar Bone



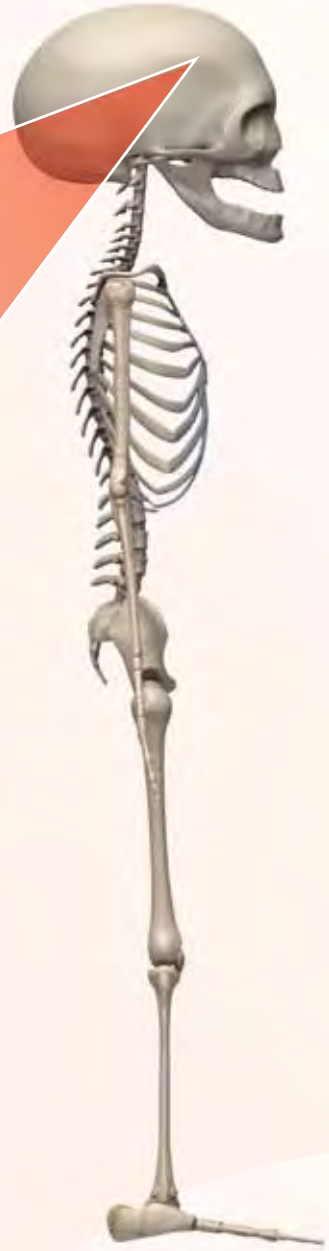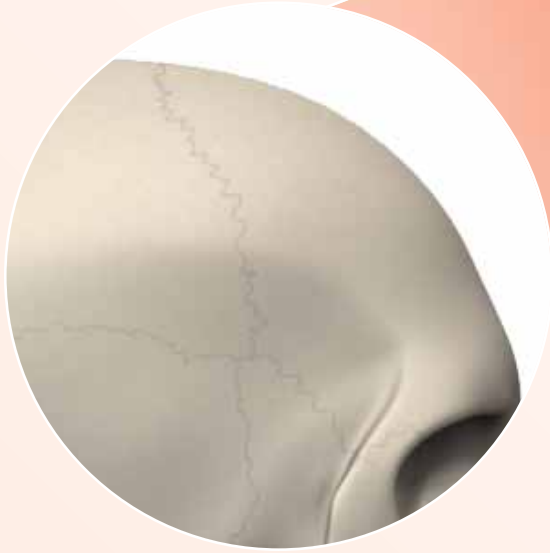ᐱᑭᑭᑦᐱᑦᐱᑦ

Kigusirvik

Kigutiqarviik

Os alvéolaire,  
arcade dentaire

# Anterior Fontanelle



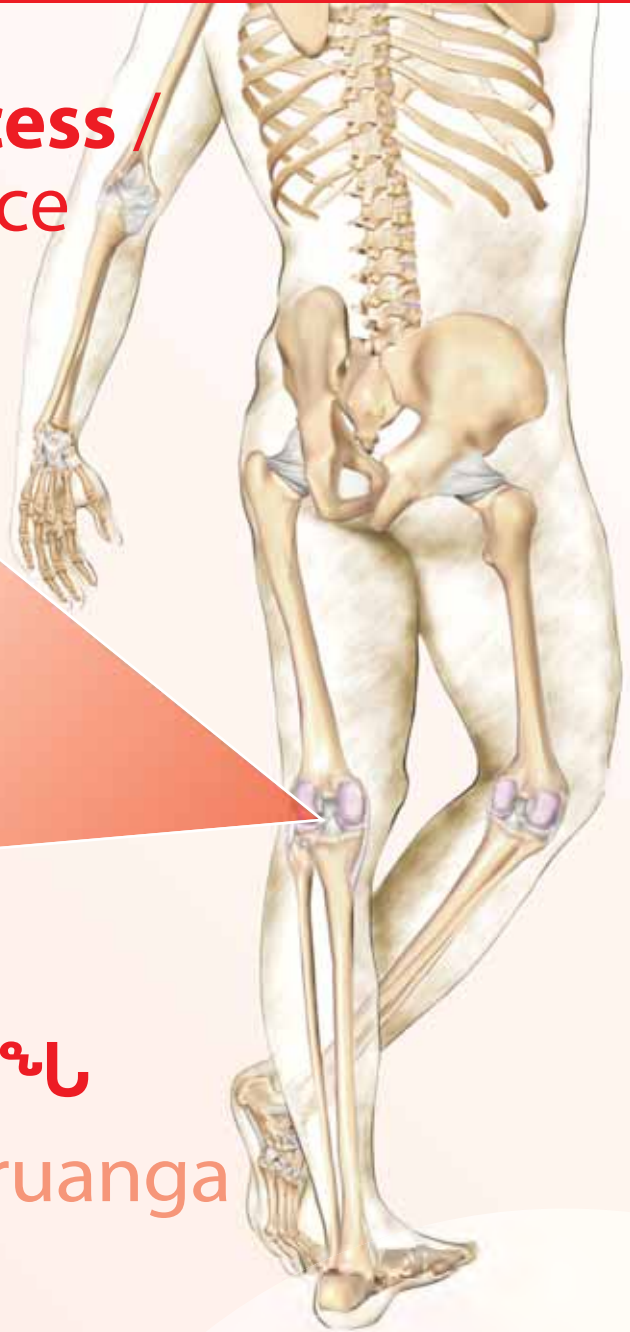
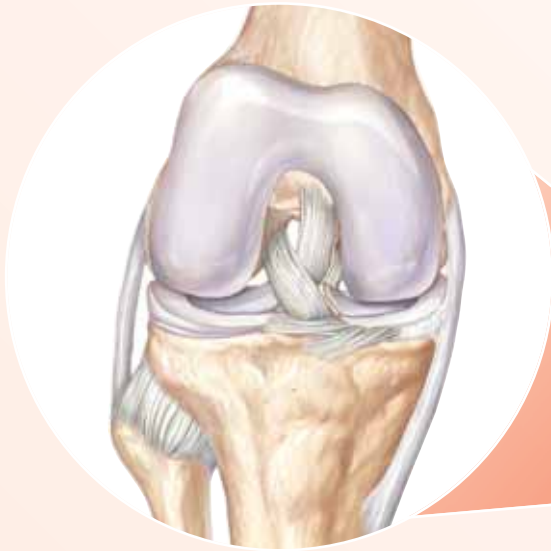Δ<sup>9</sup>β<sup>4</sup>▷<sup>6</sup> ◁<sup>4</sup> ▷<sup>6</sup>σ<sup>9</sup>ε<sup>6</sup>λ

Iqsaup Sauninga

Tiglingniq

Fontanelle  
antérieure

# Articular Process / Articular Surface



ᐃᓴᓴᐅᐅᐅ ᐃᓴᓴᐅᐅᐅ

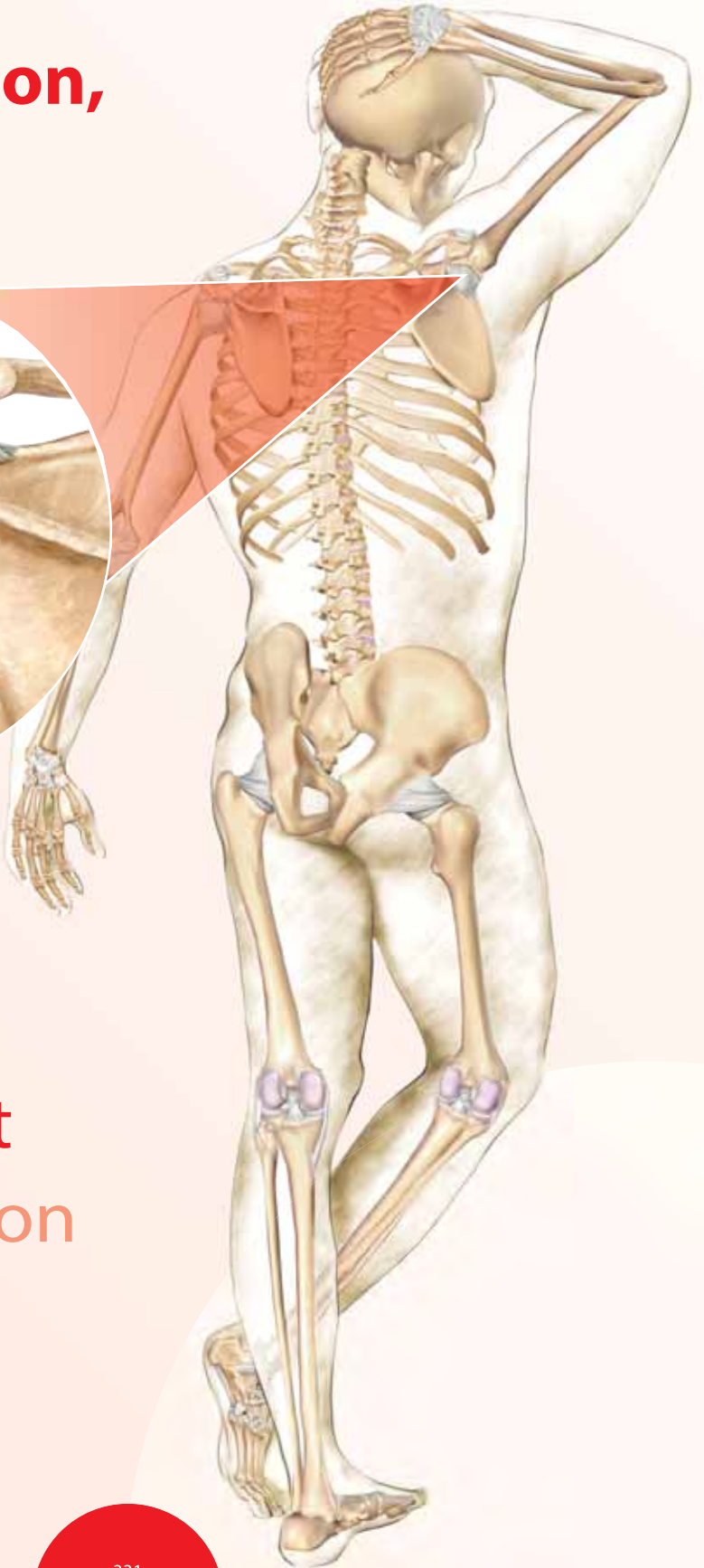
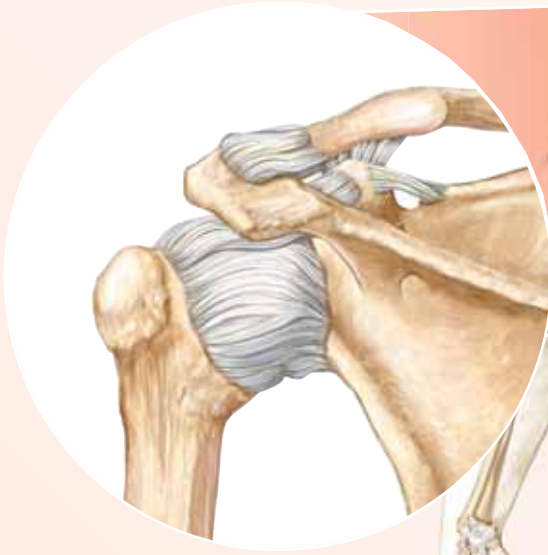
Nagguap Imaruanga

Ipiringniq

Processus  
articulaire, surface  
articulaire



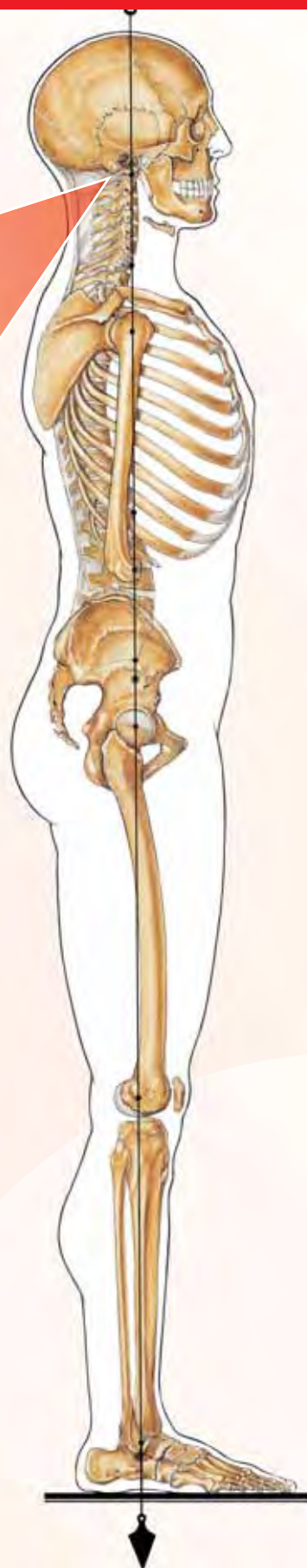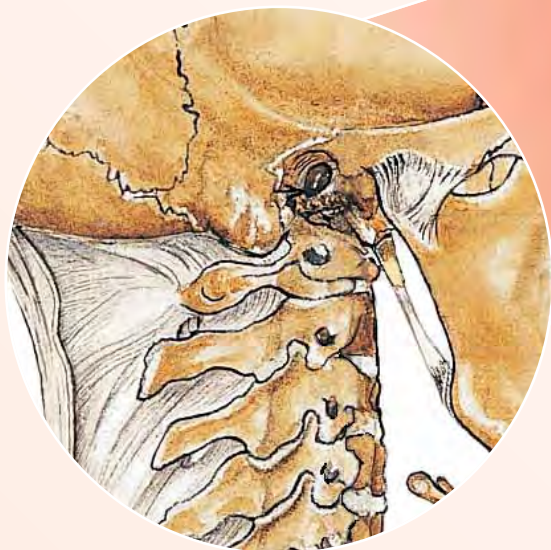# Articulation, Joints



ᐅᓴᓂᐱᐅᐅ

Nagguat  
Ipiringniit  
Articulation

# Atlas / 1st Cervical Vertebra



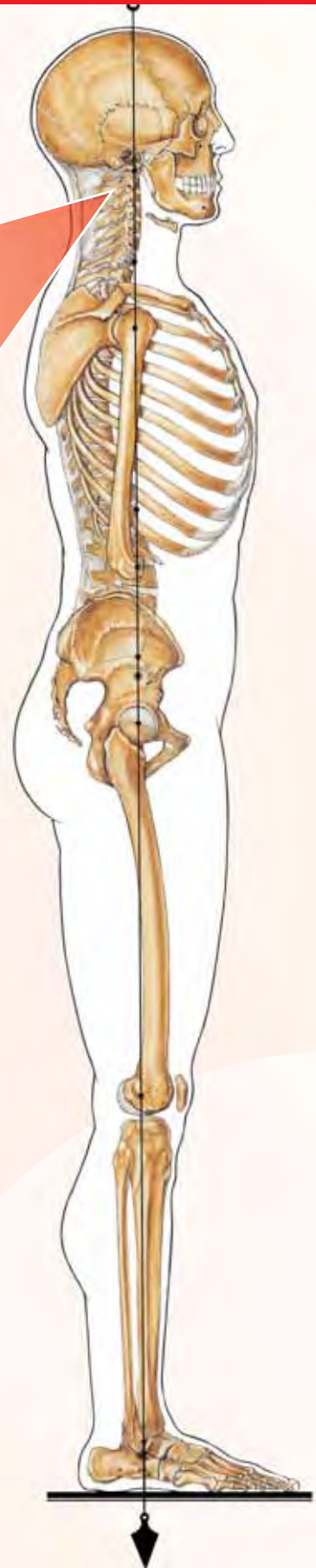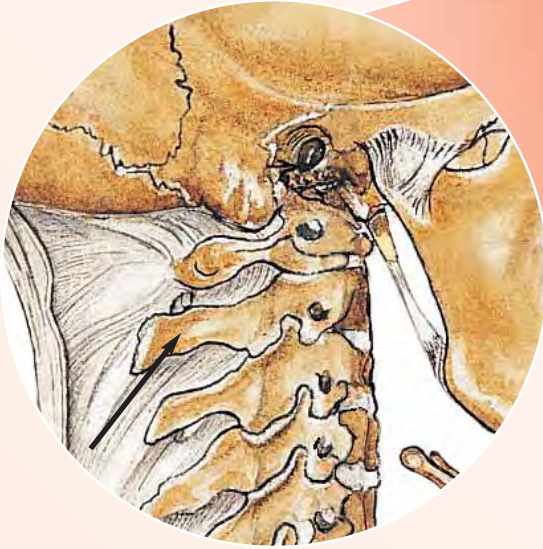σ▷C<sup>1b</sup>

Niuliq

Niuliq

Atlas (1<sup>re</sup> vertèbre  
cervicale)

# Axis



ᠲᠦᠨᠭᠠᠰᠢᠴᠢ

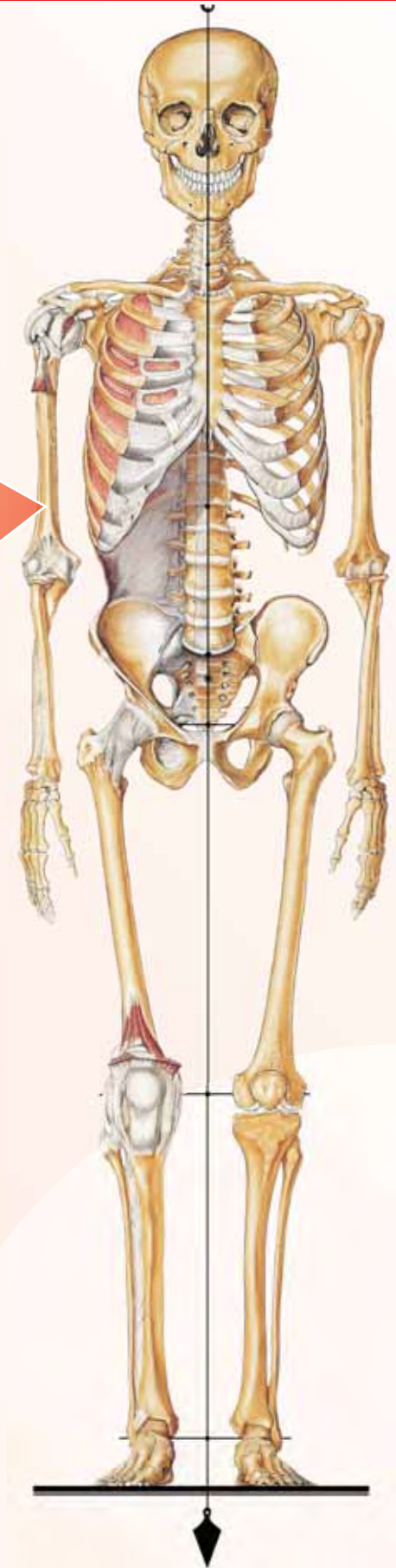
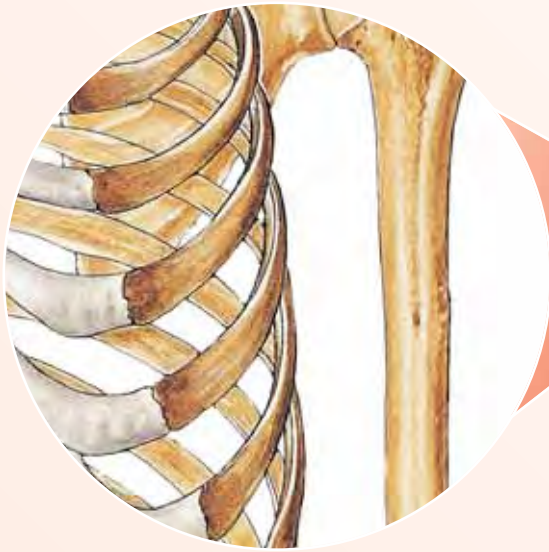
Qungasiq

Niuliq

Axis



# Bone



ᄎᄎᄎᄎᄎ

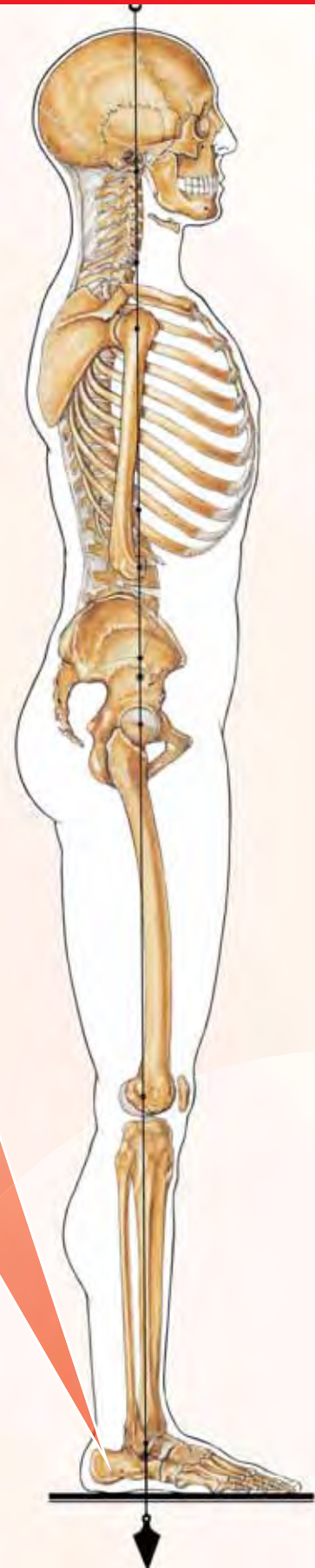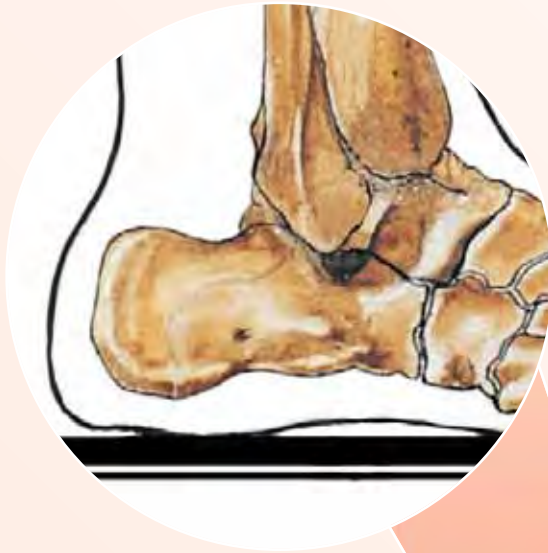Sauniq

Hauniq

Os



# Calcaneus



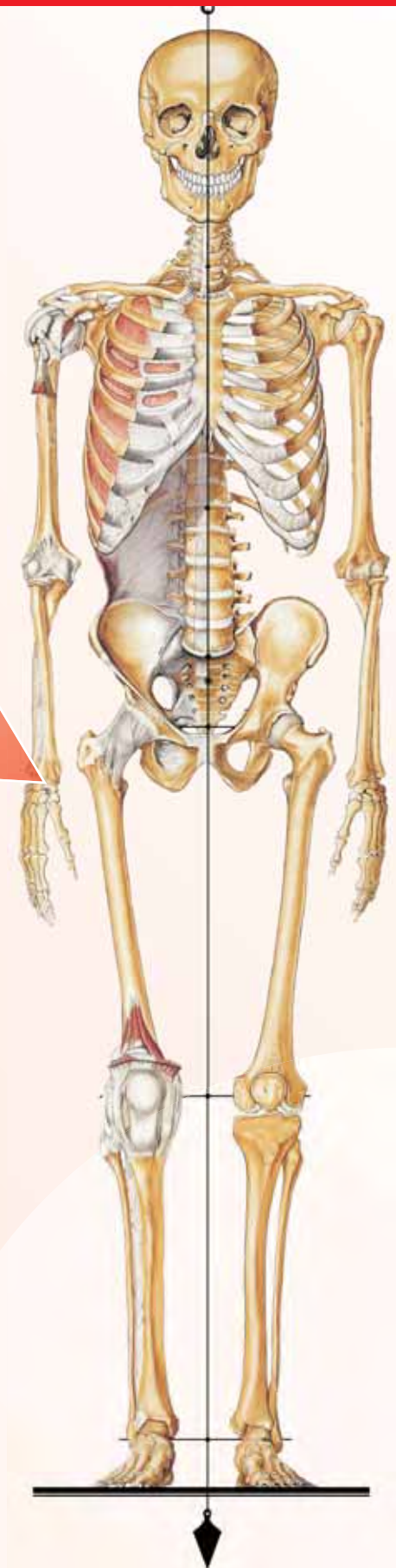
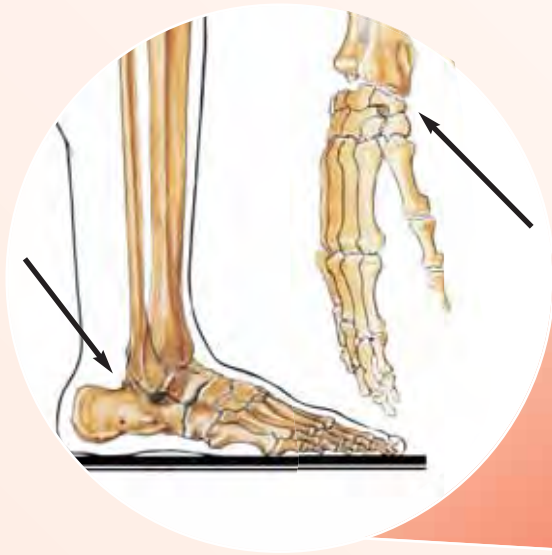ԲՆԴՆ

Kingmik

Kingmitquq

Calcaneus

# Carpus / Tarsus



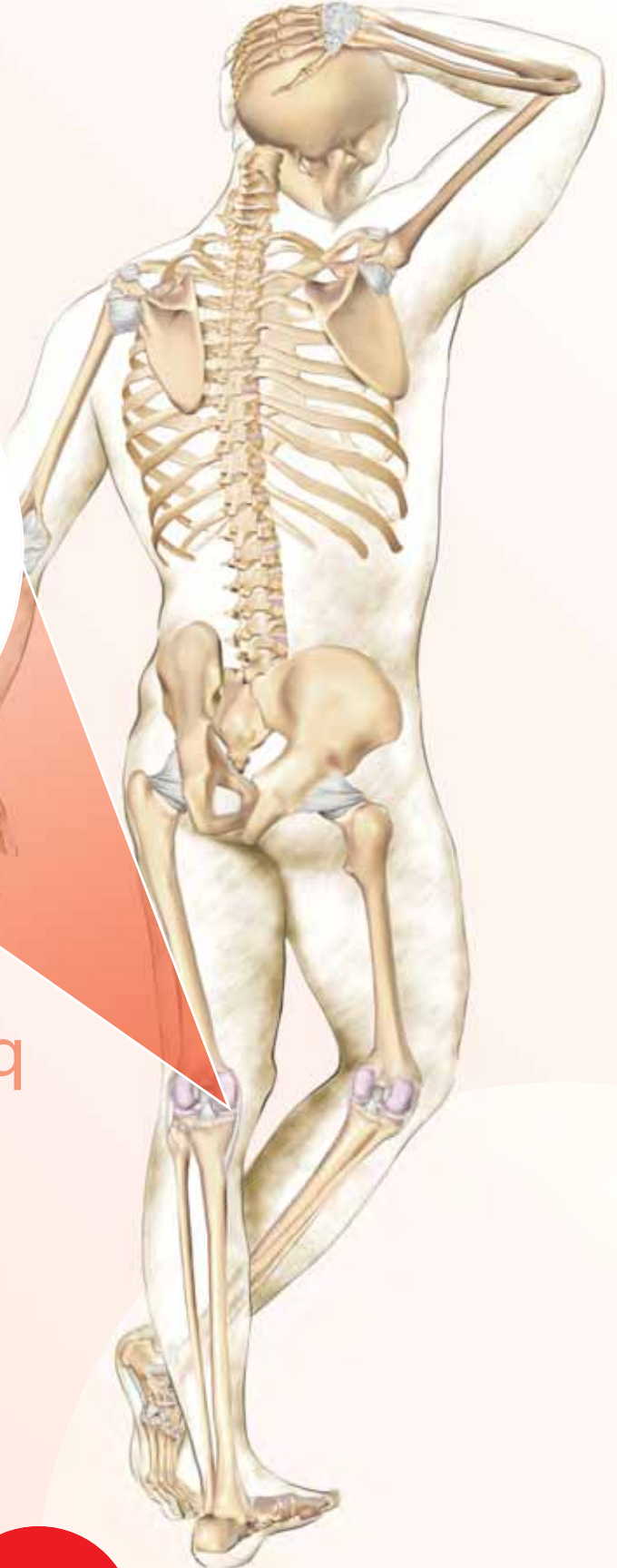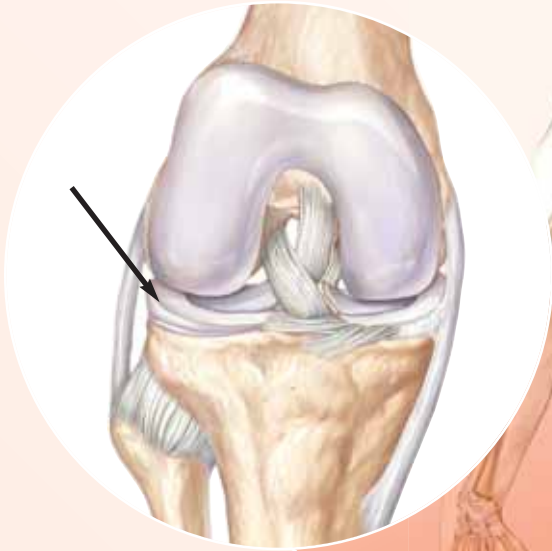
< 6 b

Pagvik

Palviit / Ihugluk

Carpe / tarse

# Cartilage



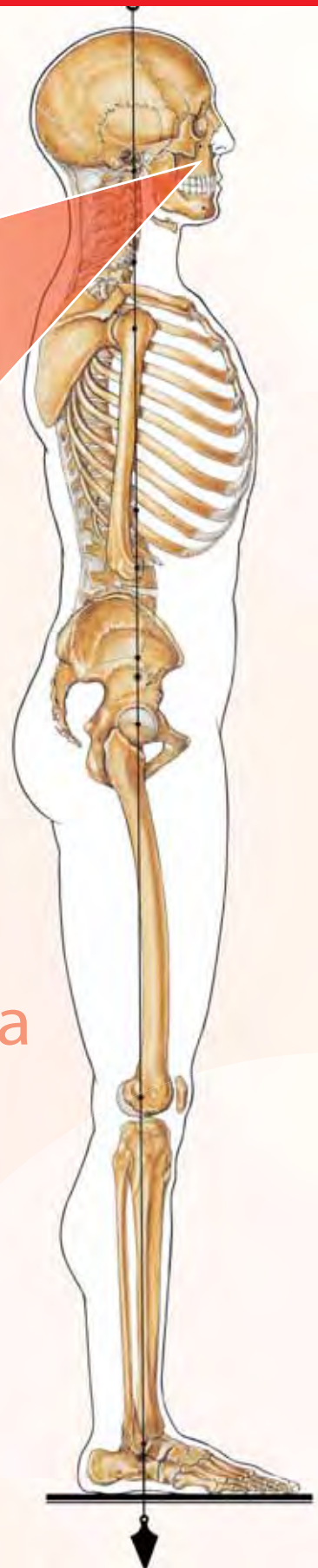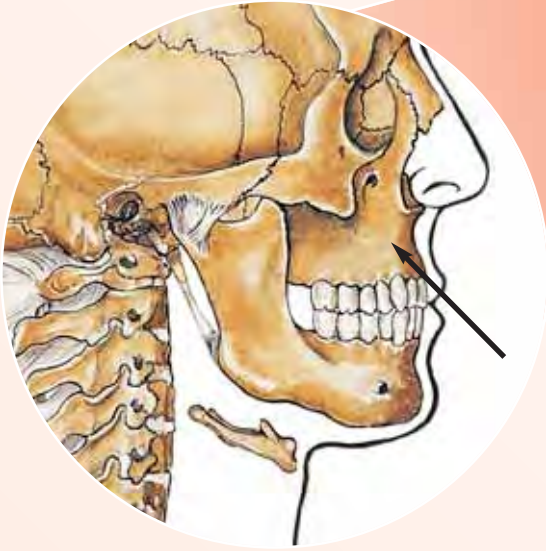ᐅᑕᖃᑦᑦᑕᖃᑦ

Nataqqulaaq

Qaqqulaaq

Cartilage

# Centre of Upper Jaw



ᑭᑭᑭᑭᑭᑭ ᑭᑭᑭᑭᑭᑭ

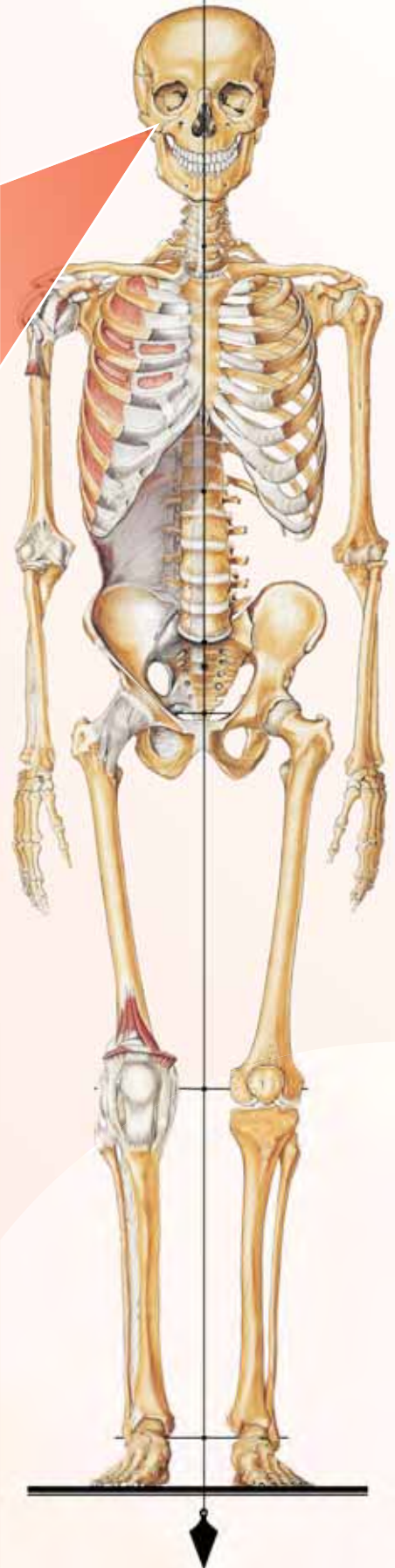
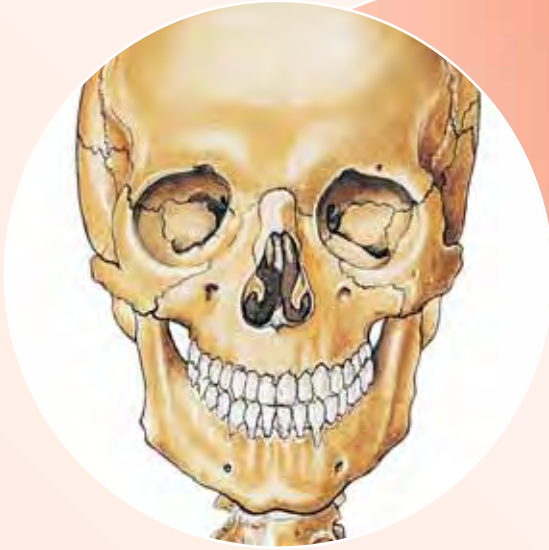Kakkiviap Sauninga

Umiitik / Umiutik

Maxillaire  
(ou mâchoire  
supérieure)



# Cheekbone



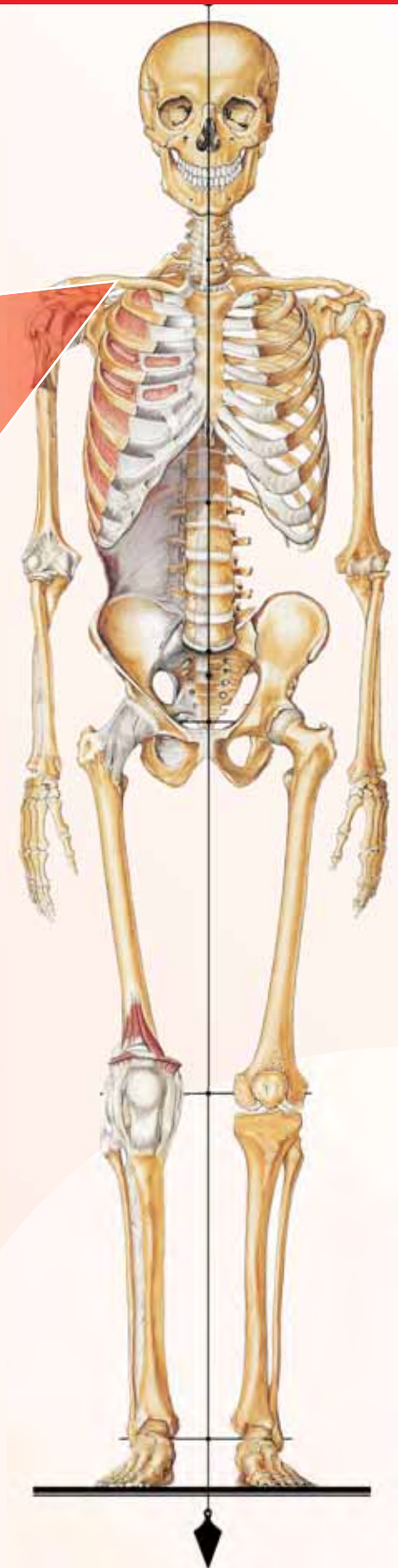
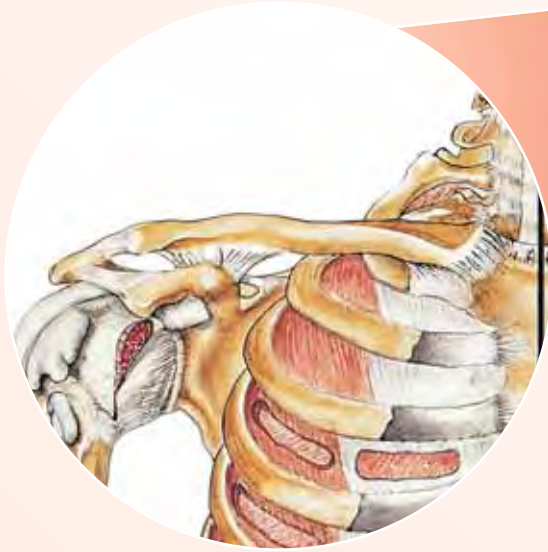
ՃՆՎ՛ ԿՃՏ՞Ն

Uluap Sauninga

Uluangnaq

Pommette

# Clavicle / Collarbone



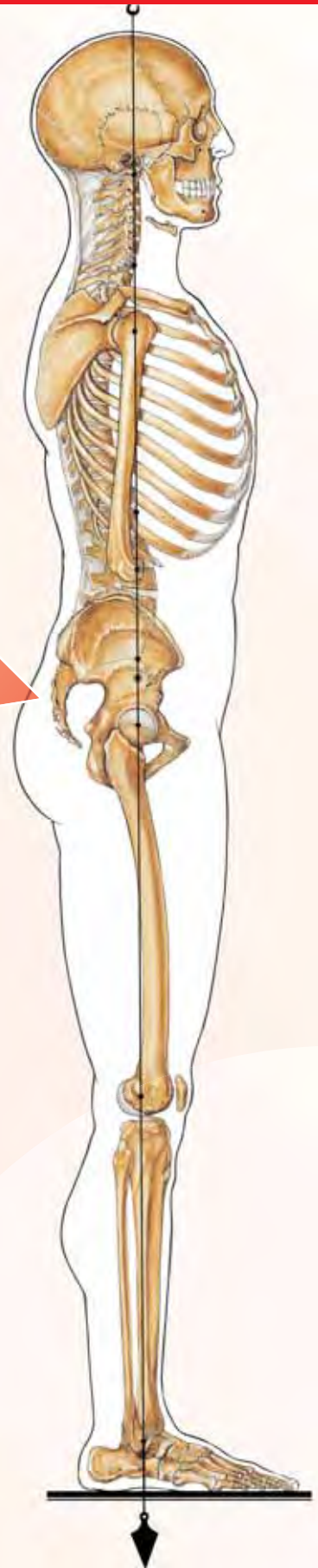
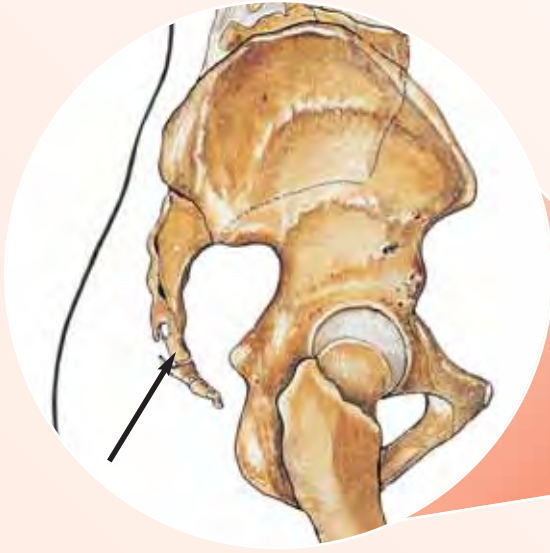
كلاوية

Qutu

Qutuk

Clavicule

# Coccyx / Sacrum



<Г>ᑭᑭ

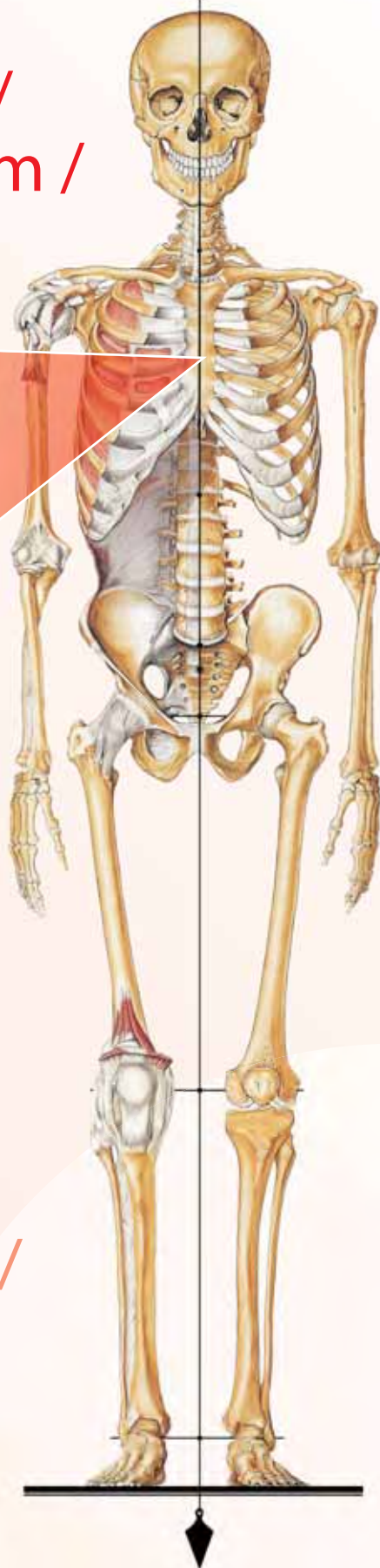
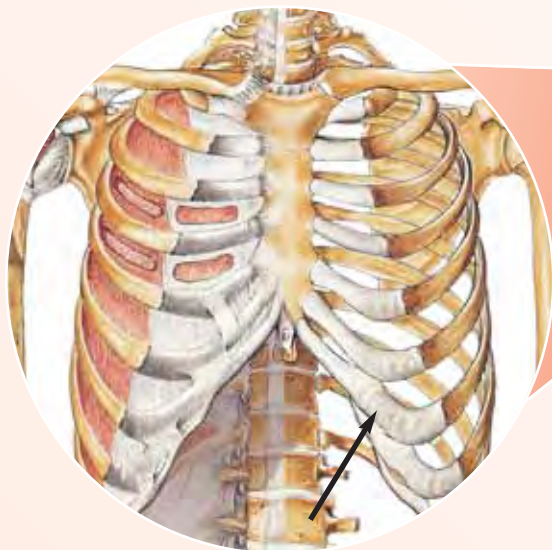
Pamiuq

Pamialluk

Haut de la raie  
des fesses



# Costal Cartilage / Rib Cage / Sternum / Breast Bone



ᐱᐱᐱᐱ

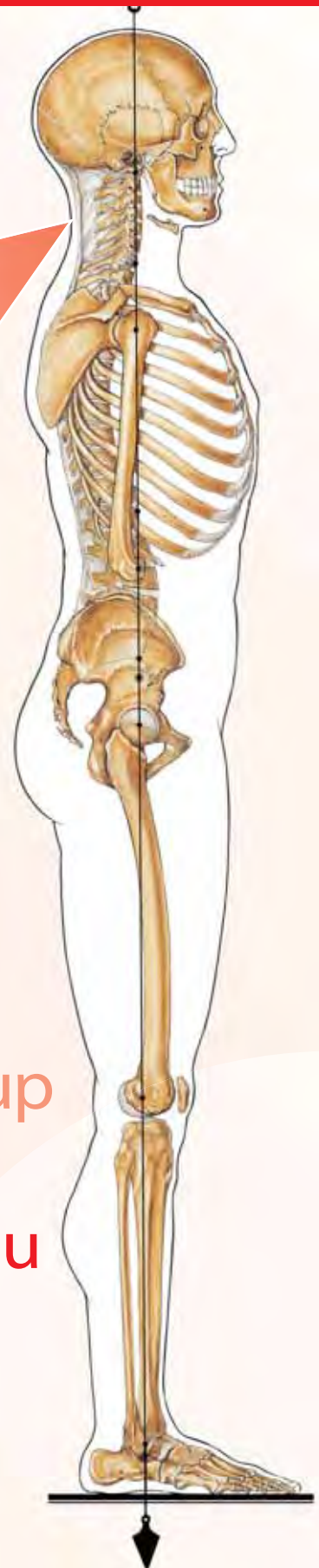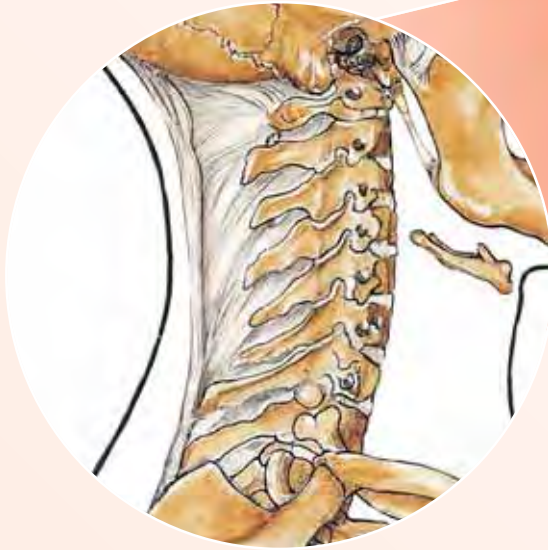Sagvik

Ilaun'nguyaq

Cartilage costal /  
cage thoracique /  
sternum



# Craniovertebral Articulation



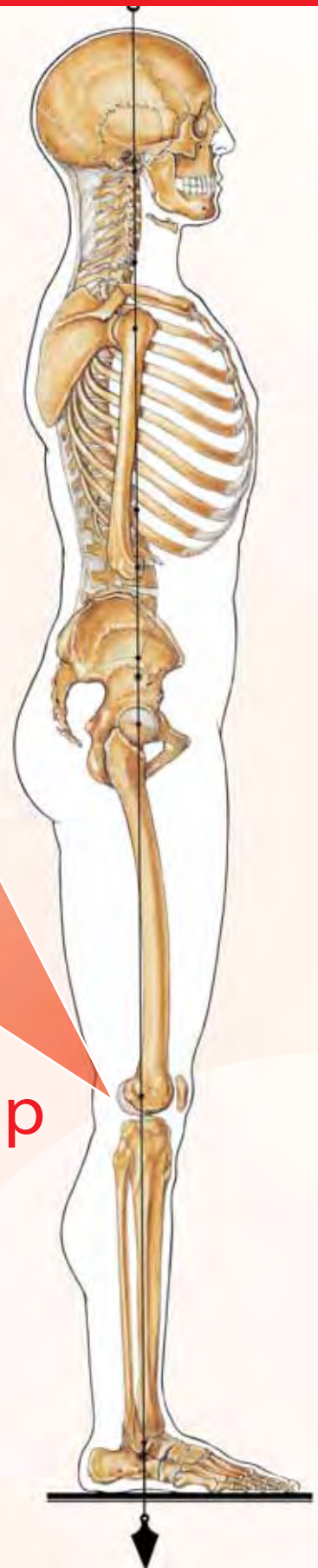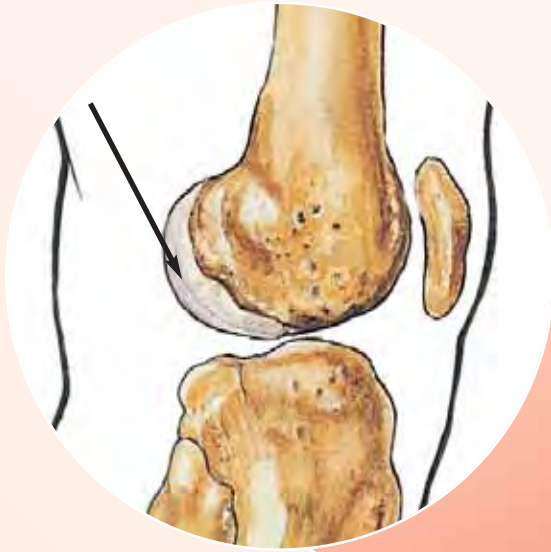σΔϕδϑΓϑ ϕδϑϑϑΔϑ  
ϑϑΔϑϑϑ

Niaqurmit Qungasiup  
Nagguangit

Niaqqup Qimirluublu  
Ingutaarnia

Articulation crânio-  
vertébrale

# Distal Epiphysis



ᕐᕈᕐᕐᕐᕐᕐᕐ ᕐᕈᕐᕐᕐᕐᕐᕐᕐ

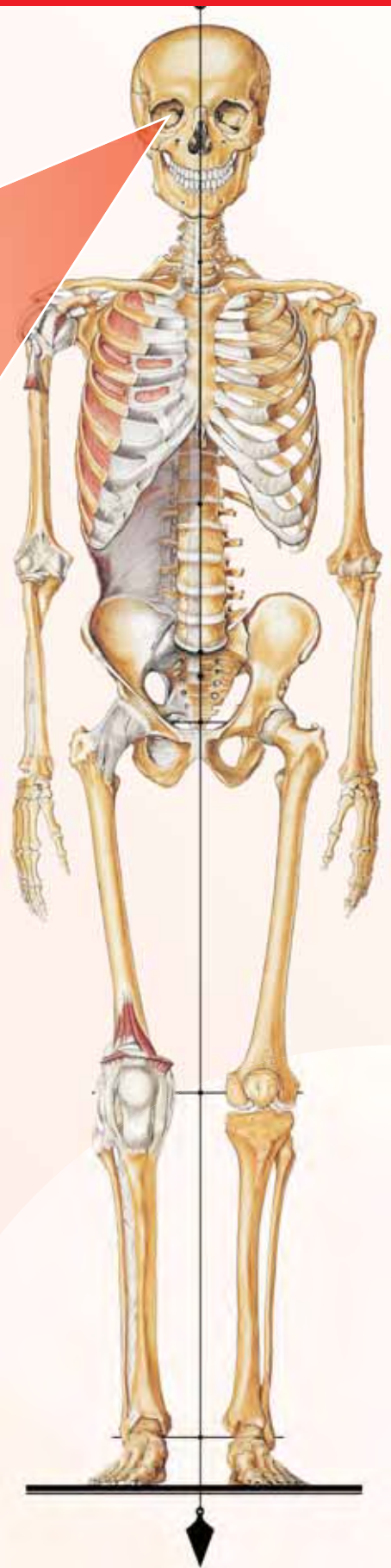
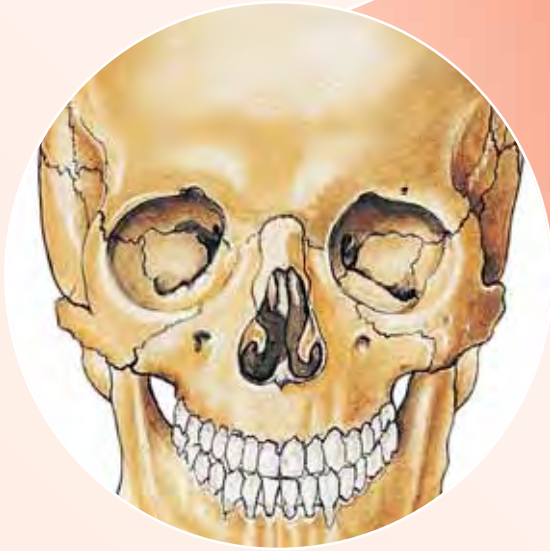Sauniup Isua

Ihugluit/Ipiringniup

Qaqqulaanga

Épiphyse distale

# Eye Socket or Orbit



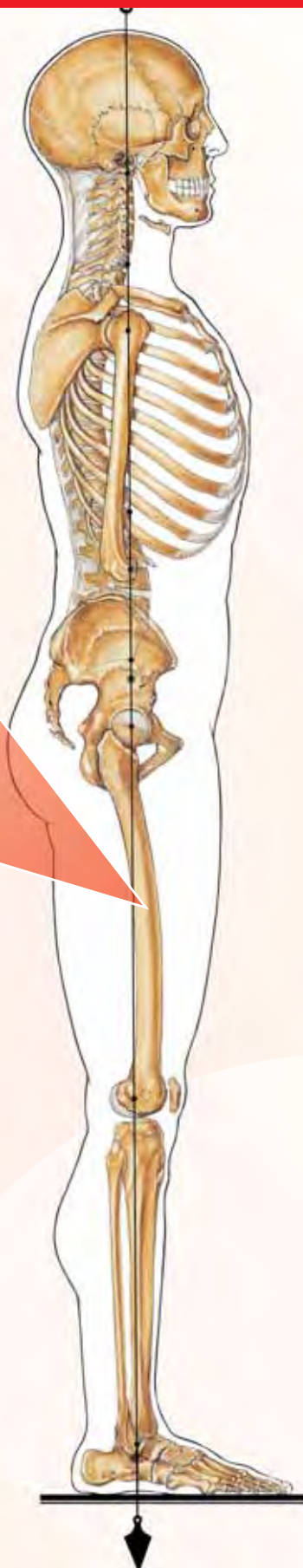
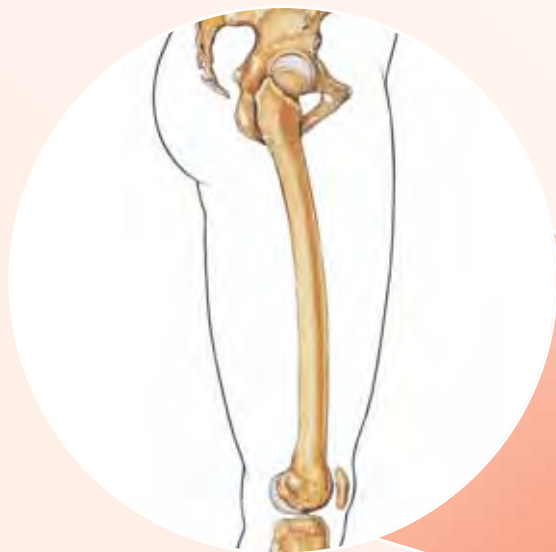
Δῖϙᾶῖῖ

Ijilirvik

Iyiqarvik

Orbite

# Femur, Thighbone



ᠵᠠᠮᠤᠨ

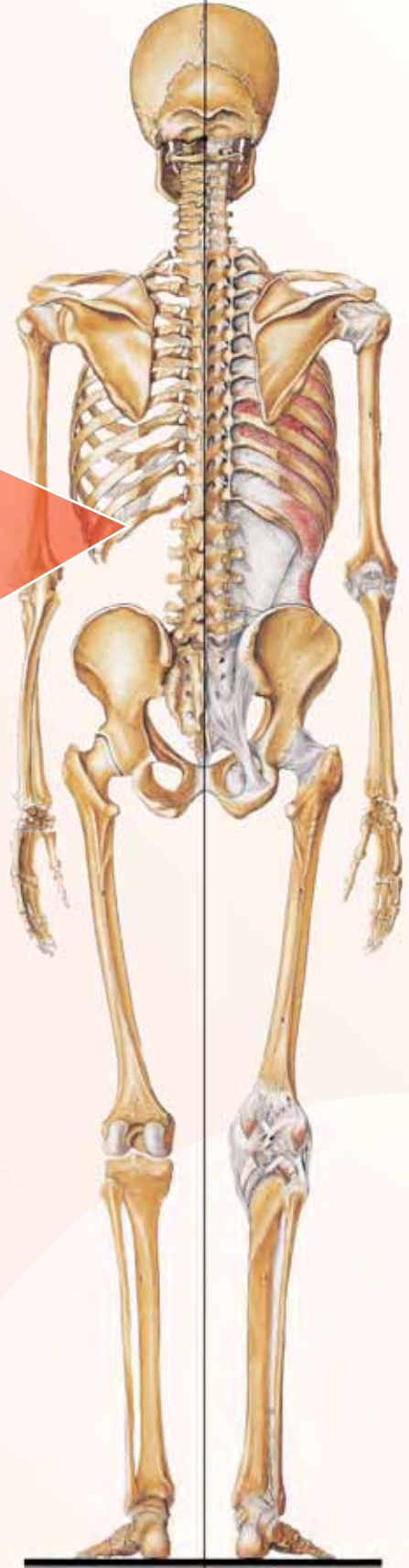
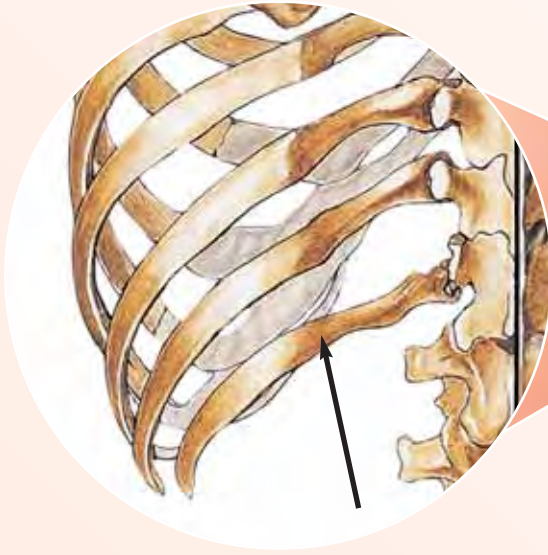
Qukturaq

Qukturaq

Cuisse (face  
antérieure), femur



# Floating Rib, Last Rib



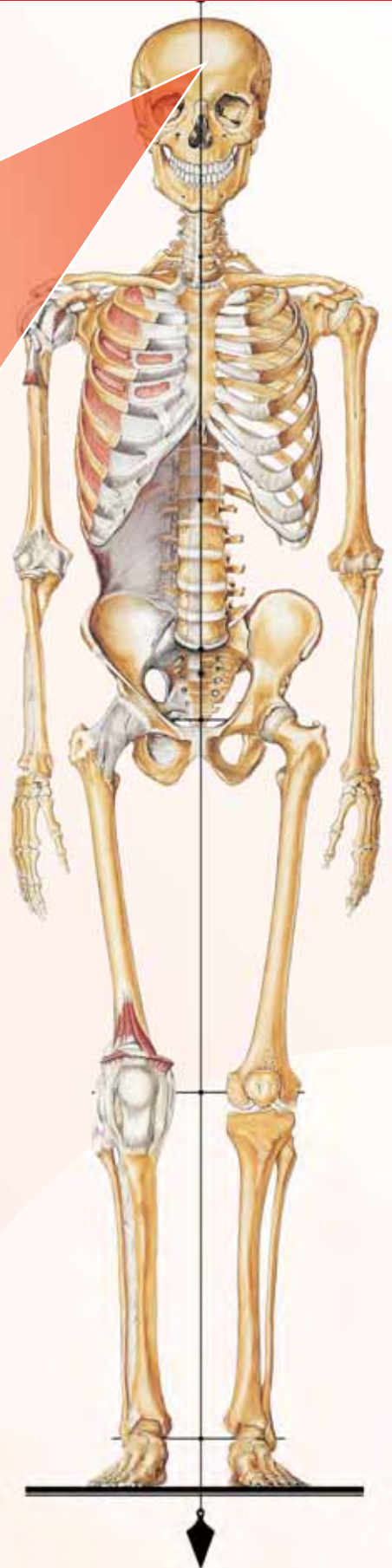
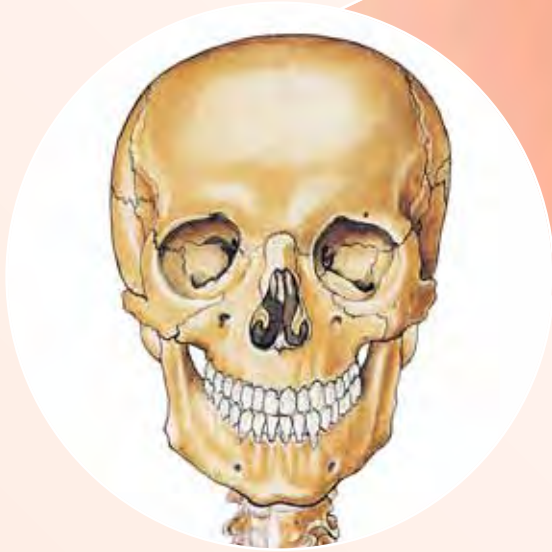ᄀᄁᄂᄃᄄᄅ

Nuvuliksaq

Ihukhiq

Côte flottante,  
dernière côte

# Frontal Bone



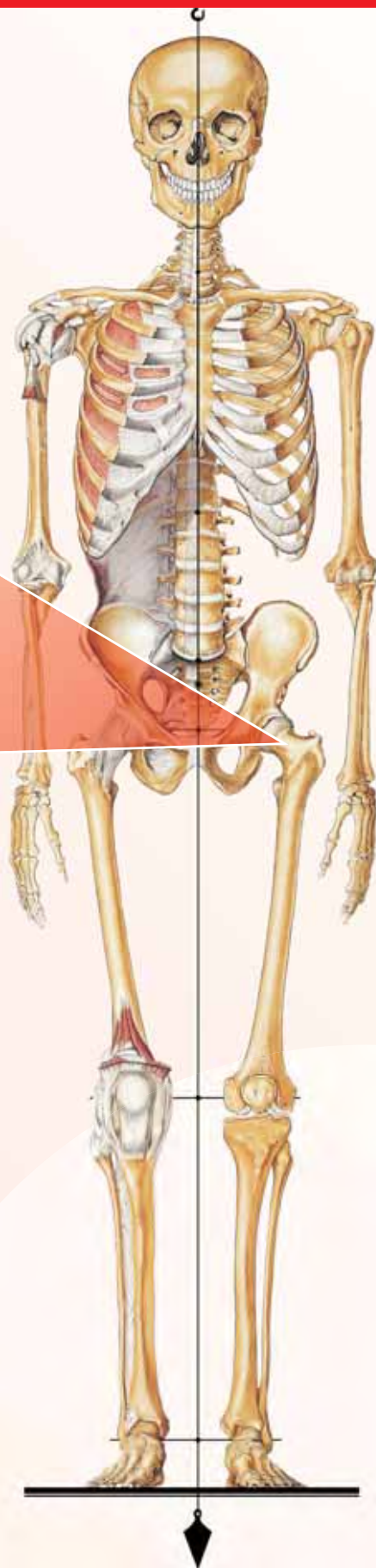
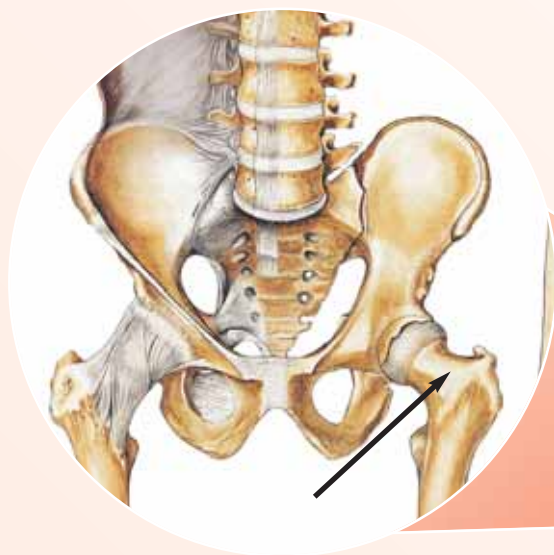
ᠶᠪᠳᠶᠪ

Qauq

Qaup Haunia

Os frontal

# Greater Trochanter



ԼՐԴԳԾ

Makisiq

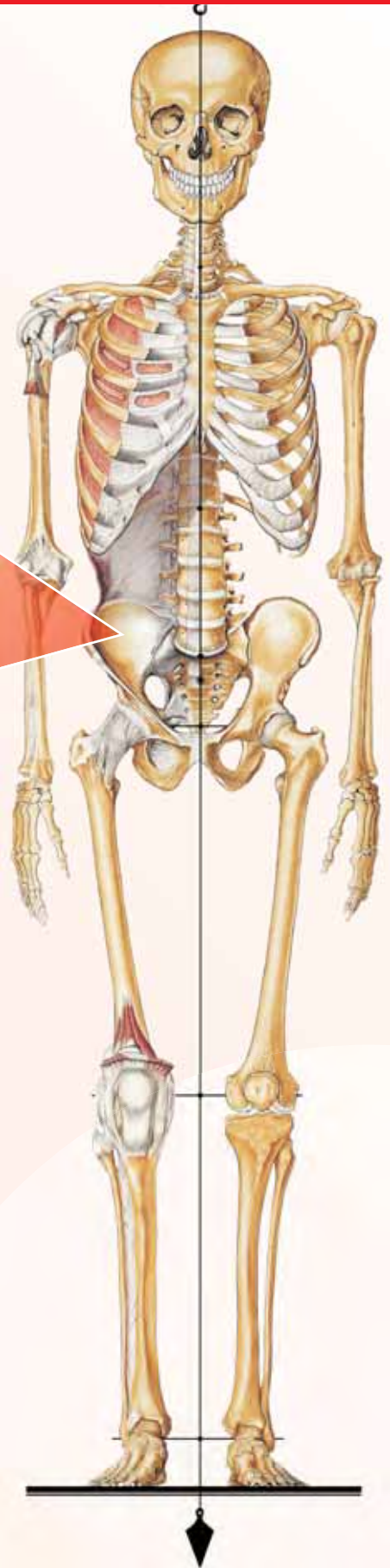
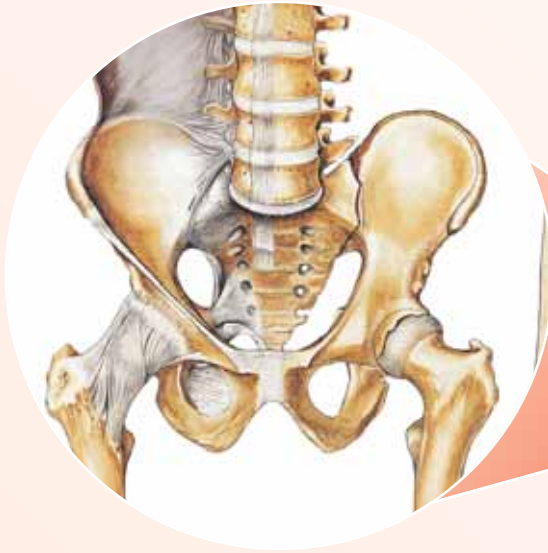
Makitiq

Hanche

(région de la)



# Hip



ძეგნა

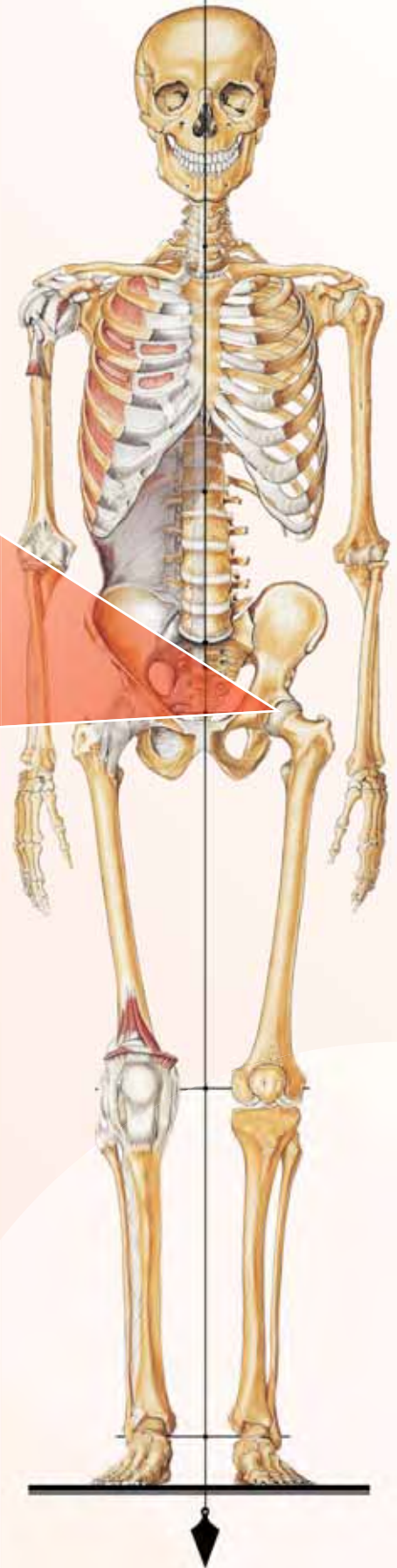
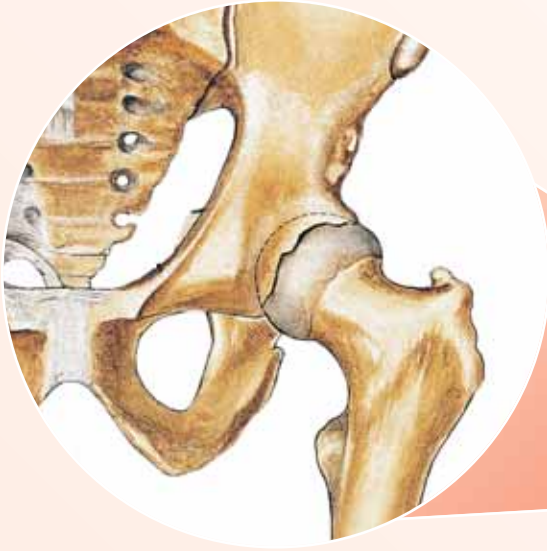
Kuuttiq

Hilviaq

Hanche



# Hip Joint



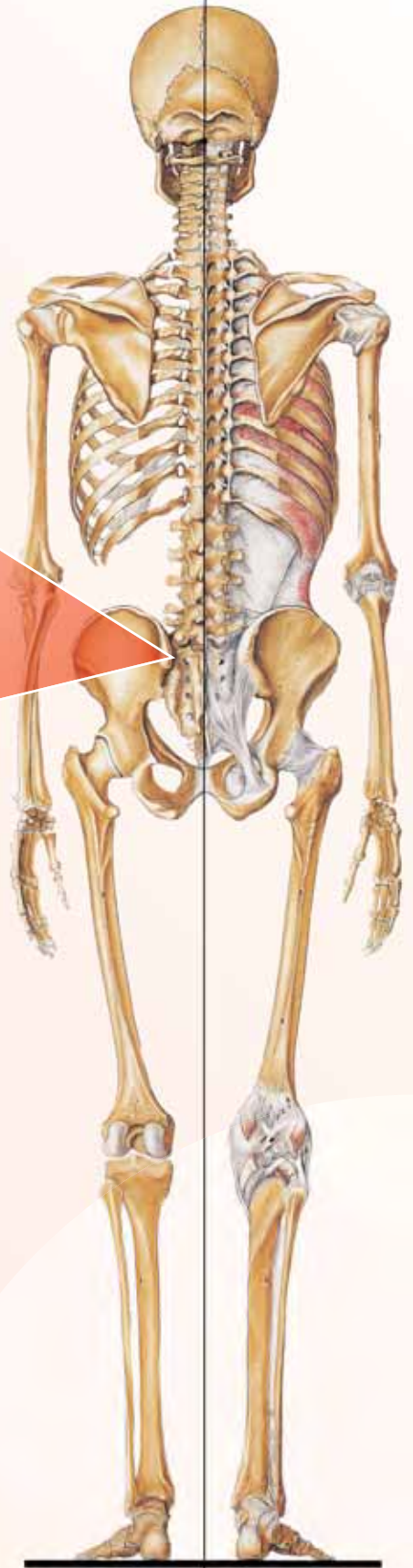
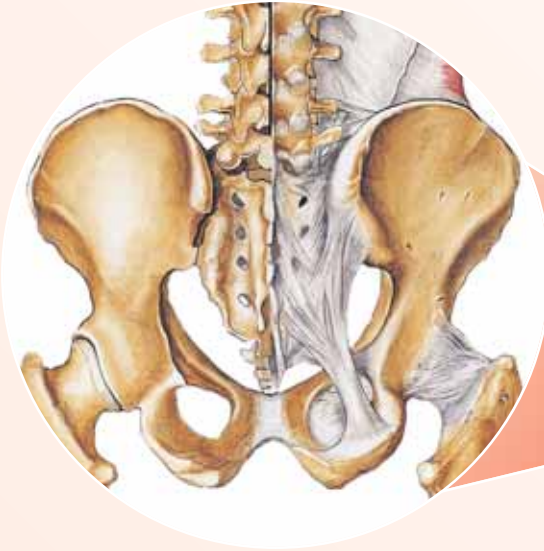
ᐱᑦᐱᐱᐱᐱᐱᐱ

Sivviaq

Kuuttiq

Os iliaque,  
os de la hanche

# Hip, Iliac Bone / Hip Area



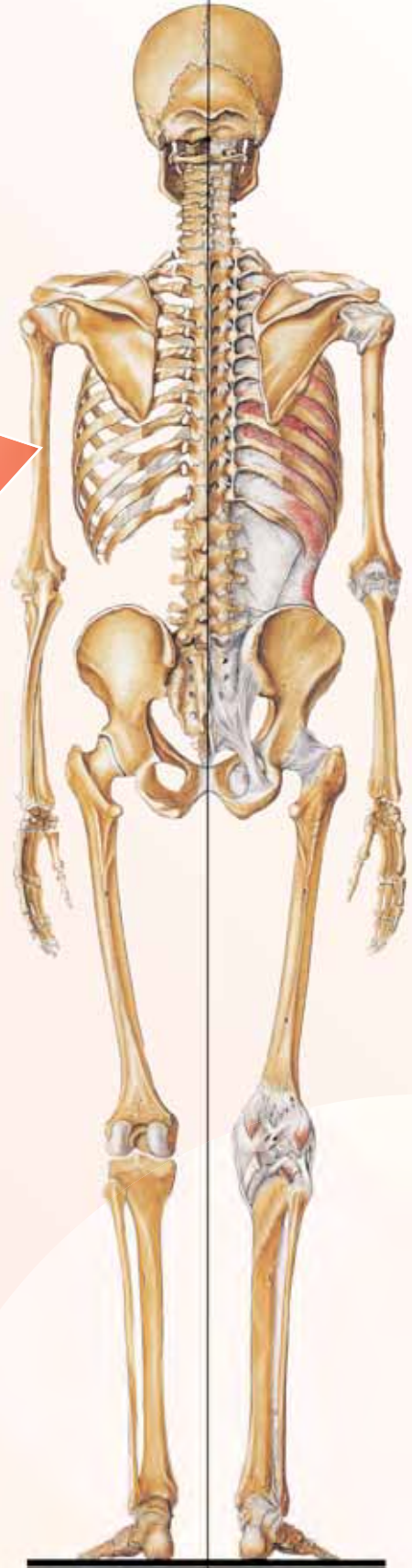
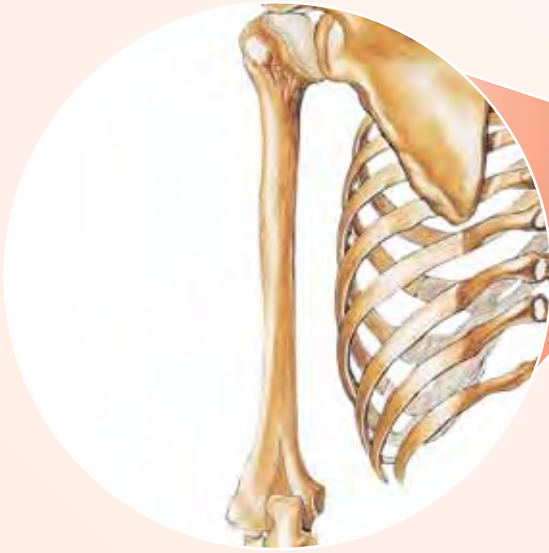ᑭᓄᓃᓂᓂᓂᓂᓂᓂᓂᓂᓂᓂᓂᓂ

Sivviaqarvik

Hilviaq

Hanche,  
os iliaque

# Humerus



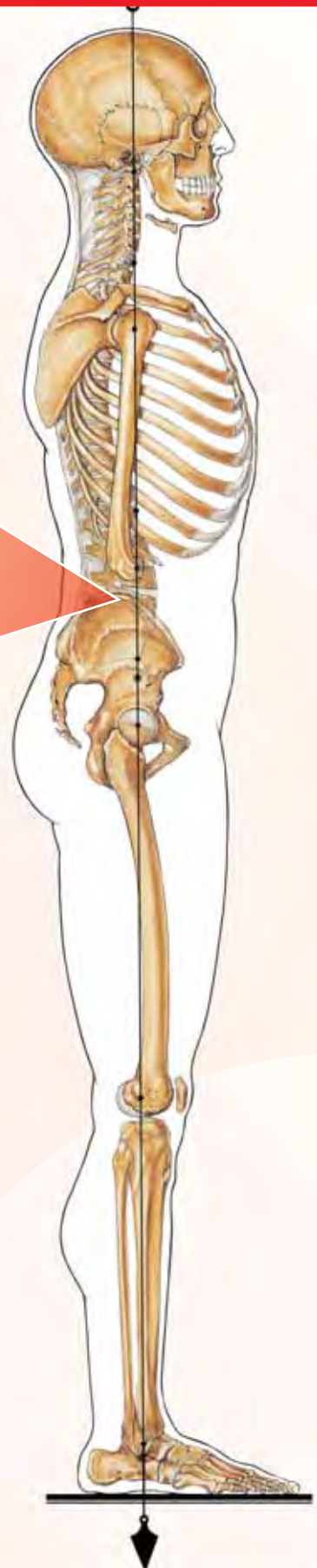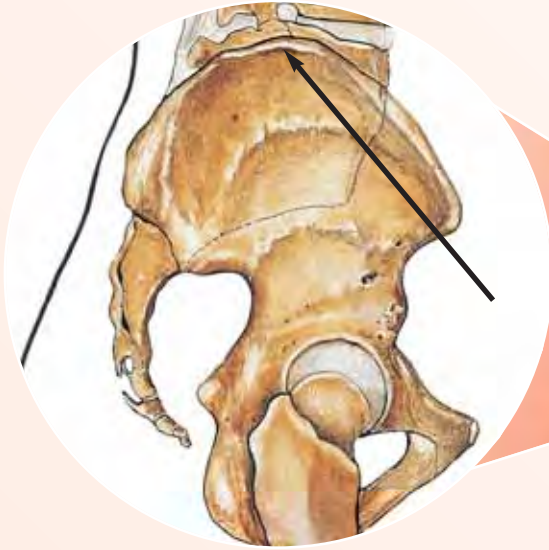
ᐃᐅᐅᐅᐅᐅᐅᐅᐅ

Aksaqquq

Akhatquq

Humérus

# Iliac Crest



ᐱᕈᕈᕐᕐ

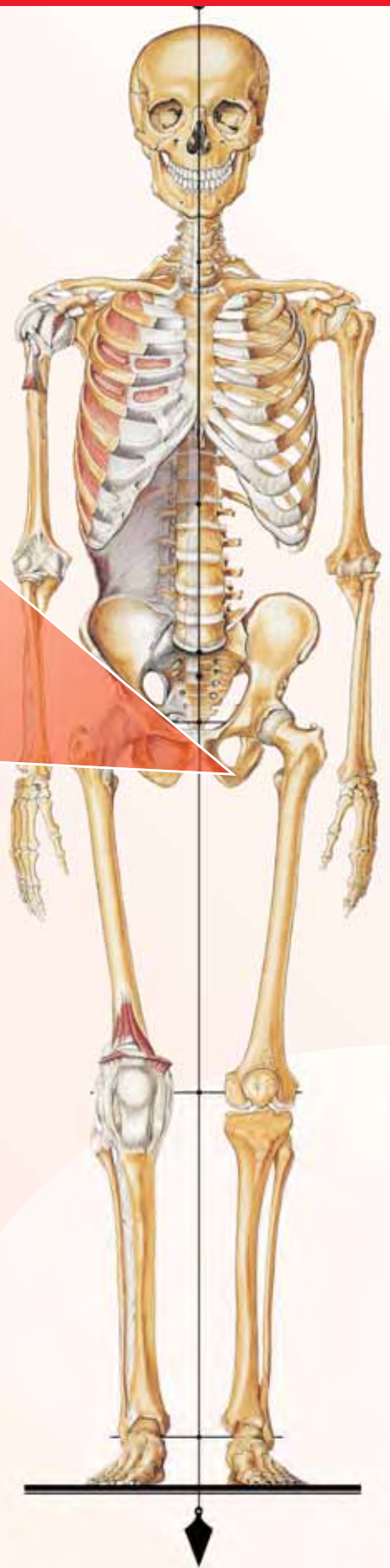
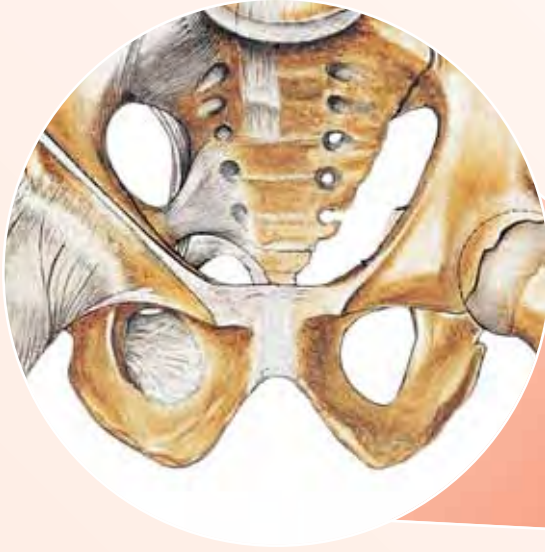
Makisiq

Kuuttiniq

Crête iliaque



# Ischium



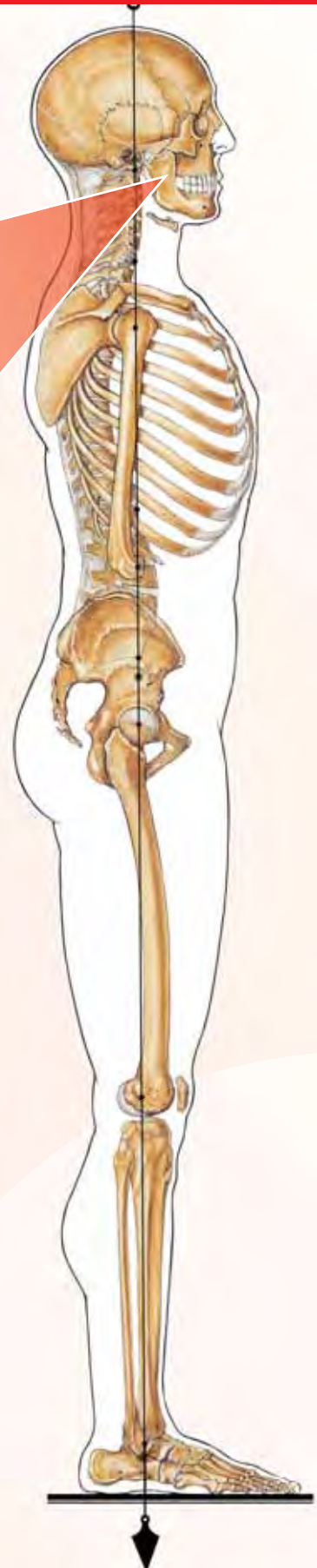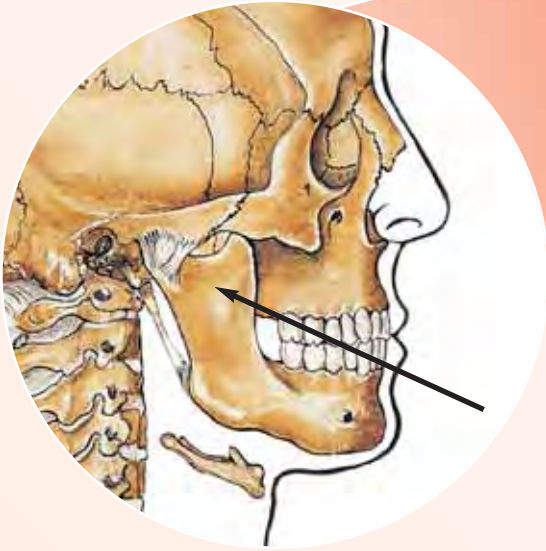نُلُوق

Nuluq

Kuuttiup Kangia

Ischion

# Jaw Bone



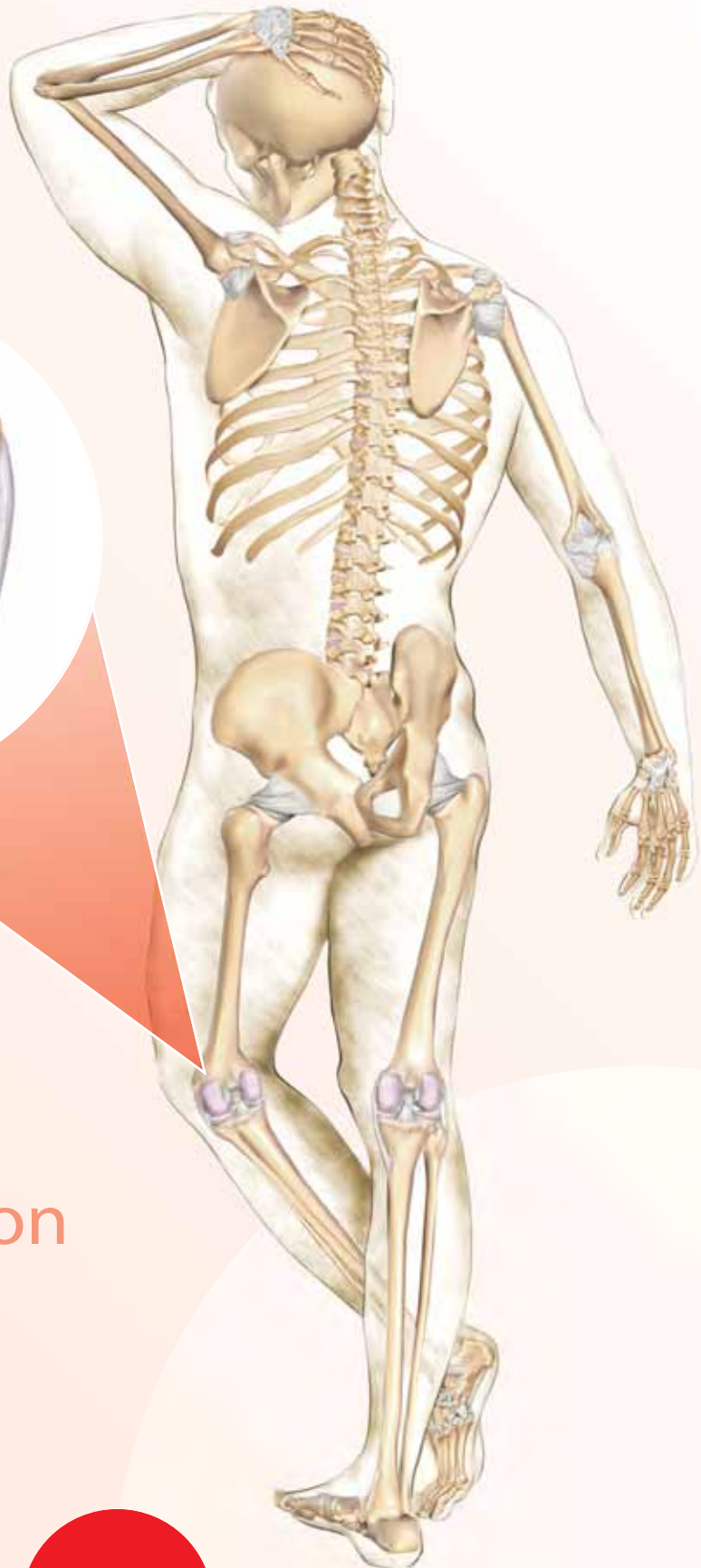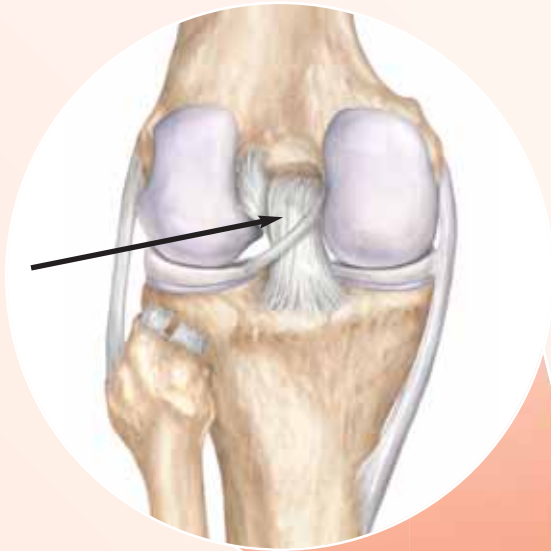
ᐃᓗᓗᐅ ᐱᓗᓗᐅ ᐱᓗᓗᐅ  
ᐱᓗᓗᐅ ᐱᓗᓗᐅ ᐱᓗᓗᐅ ᐱᓗᓗᐅ

Uluap Sauninga  
Ataaniinniiqsaq

Uluap Haunia

Os malaire ou  
zygomatique

# Knee Joint



ᐃᑦᐃᑦᐃᑦ

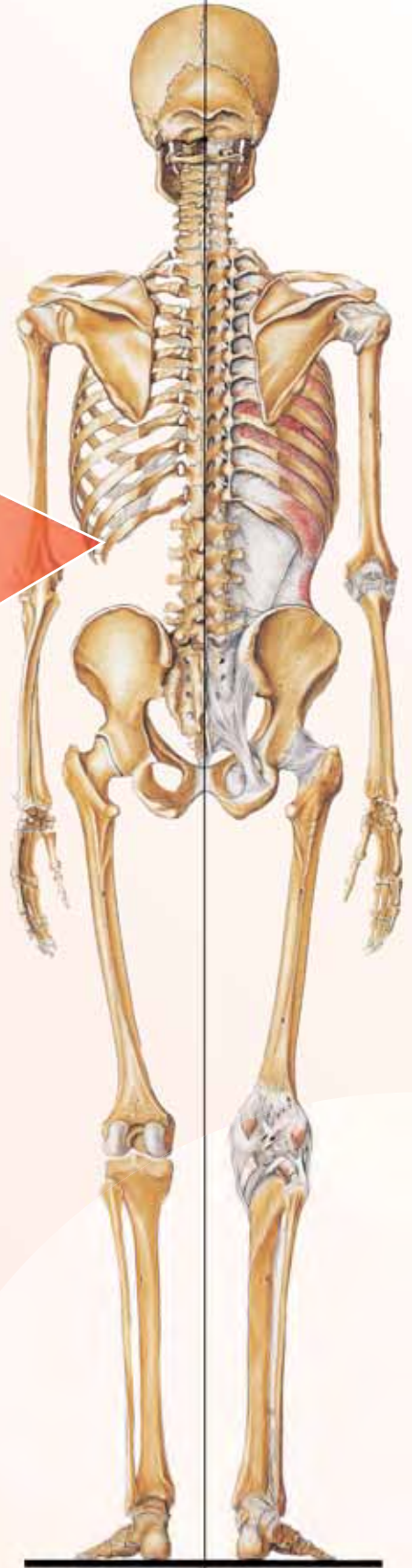
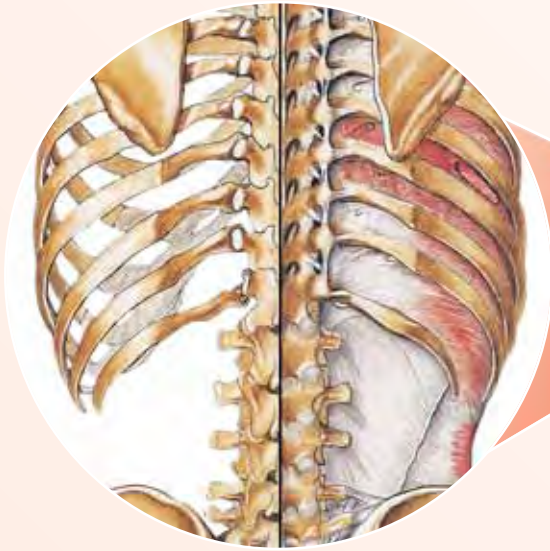
Siiqquaq

Nabluk

Articulation  
du genou



# Lower End of the Ribs



ᄀᄁᄂᄃᄄ

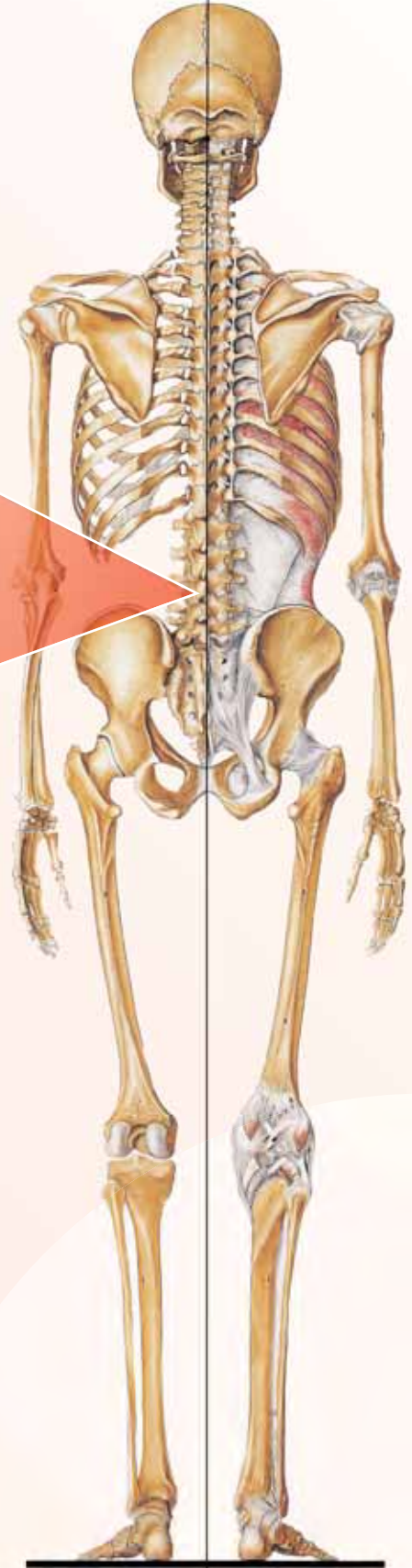
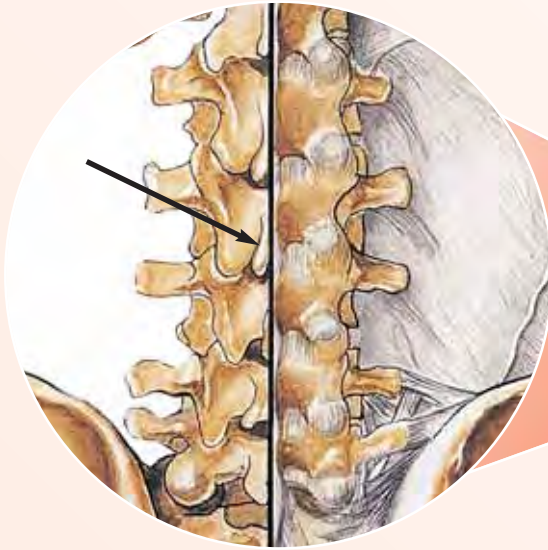
Nuvulixsat

Ihukhiq

Bas des côtes



# Lumbar Vertebrae / Sacrum



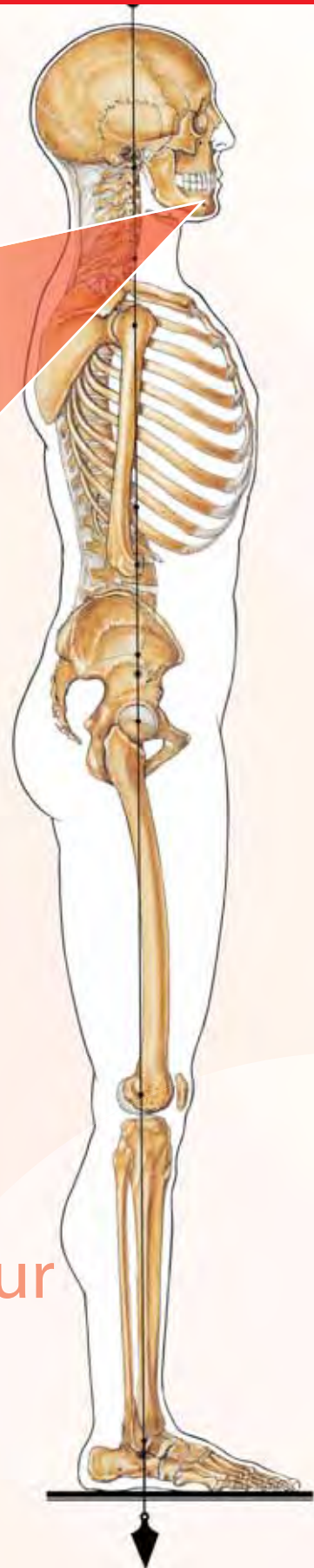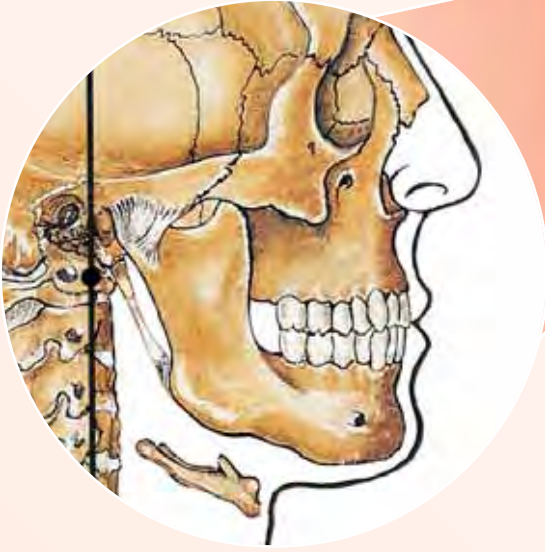
ᐃᑦᑎᐸᑦᑲ

Kuttiniq

Kuuttiniq

Vertèbres  
lombaires /  
sacrum

# Mandible / Lower Jaw Bone



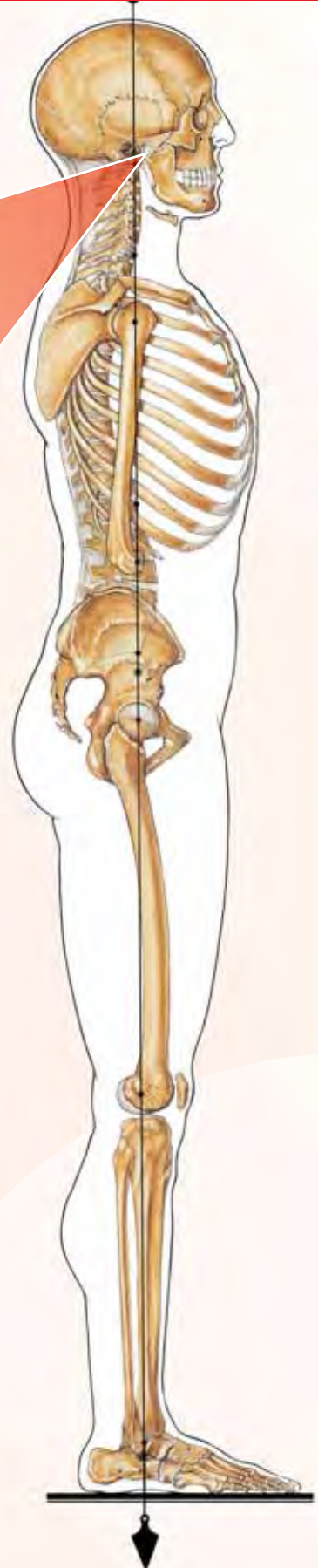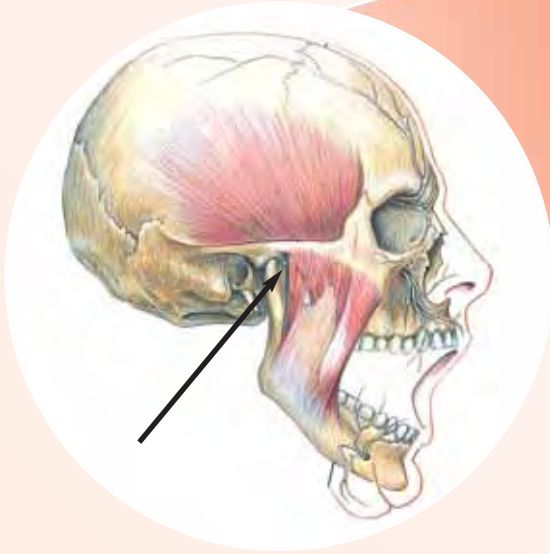
ᐱᓂᓂᓂᓂᓂᓂ

Agliuruq

Agliuruq

Mandibule  
(maxillaire inférieur  
ou mâchoire  
inférieure)

# Mandibular Condyle



ᐱᓕᓂᓂᓂ ᐃᓂᓂᓂᓂ

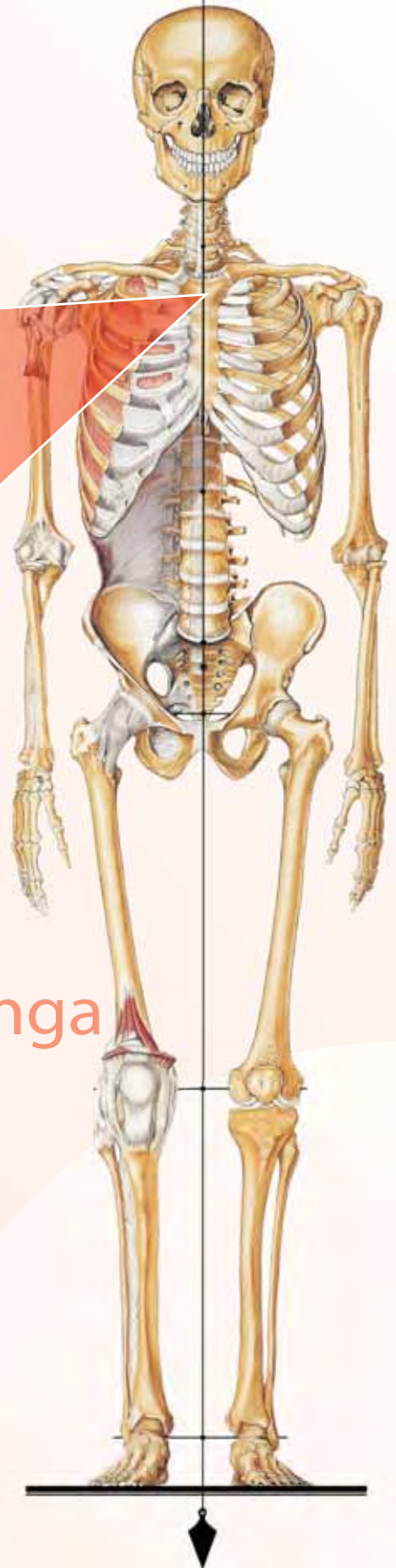
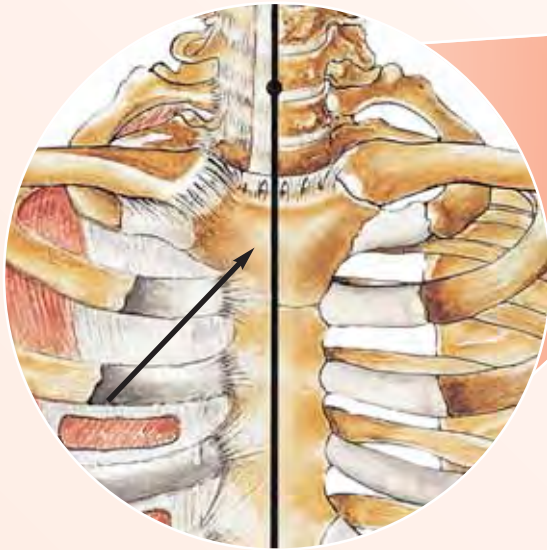
Agliruup  
Tunganinga

Tuttak

Condyle de la  
mandibule



# Manubrium



ԿՐՎԷ ԳԾԸՊՆՆՆ

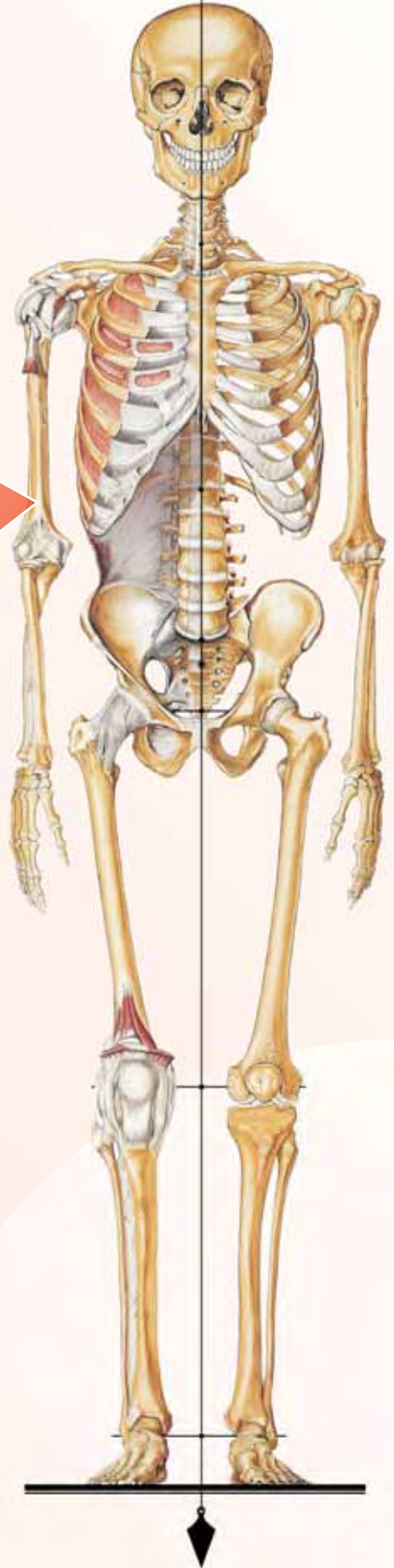
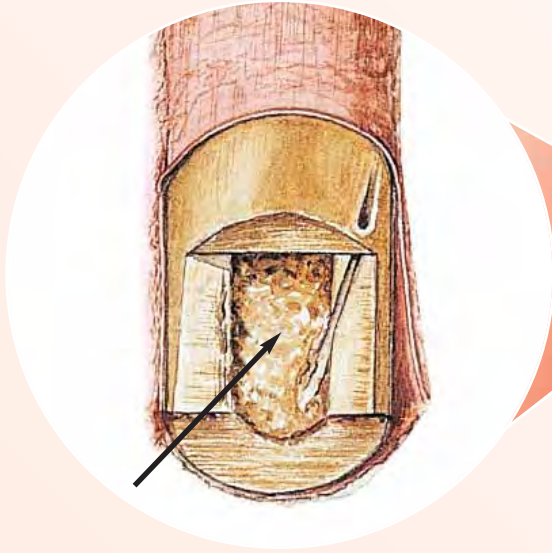
Sakiap Qulingaanga

Hakiap Haunia

Manubrium



# Marrow



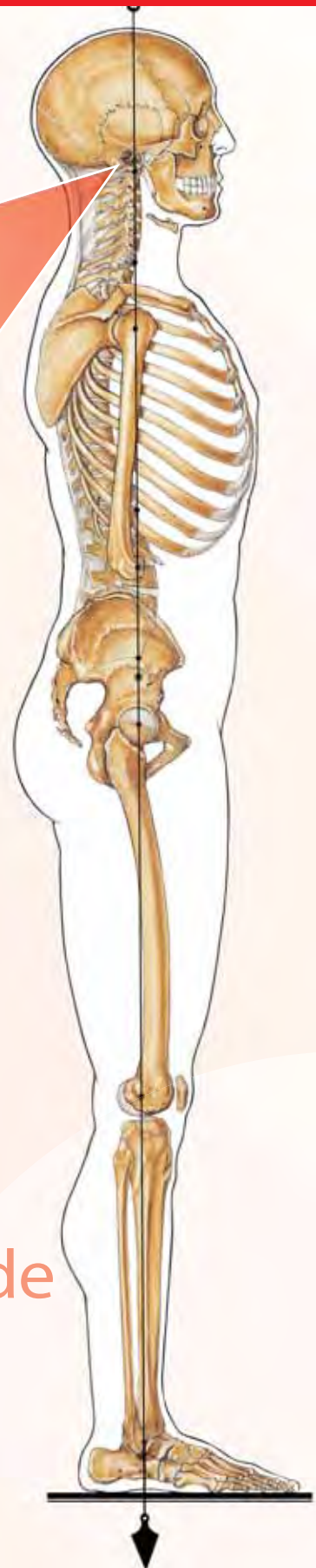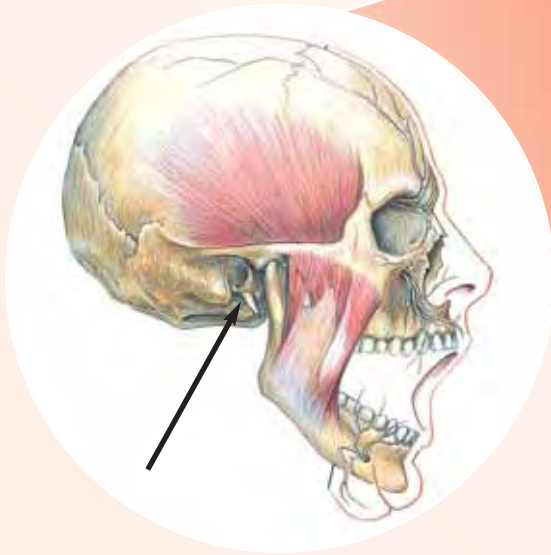
كُنْف

Patiq

Patiq

Moelle osseuse

# Mastoid Process



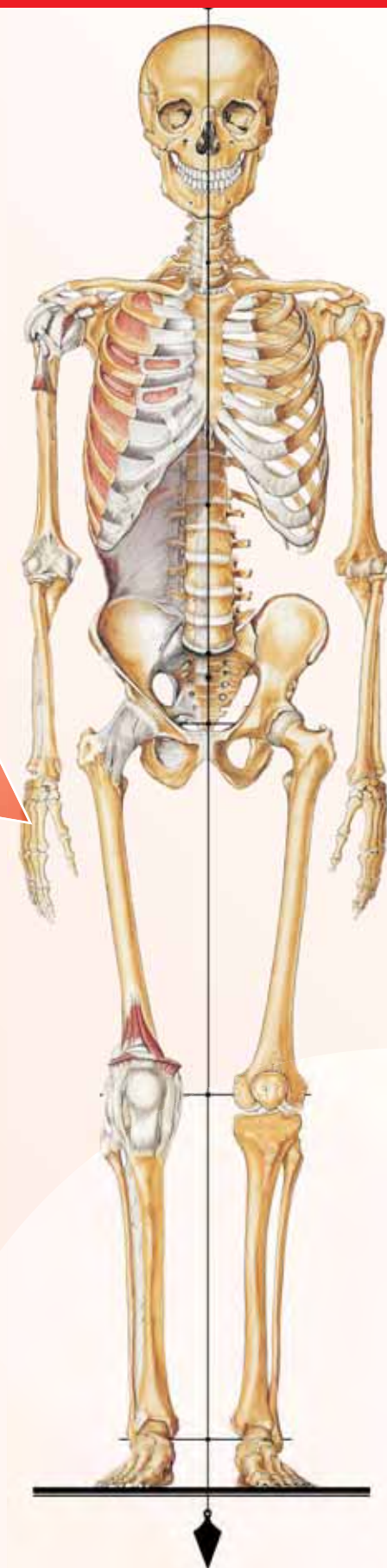
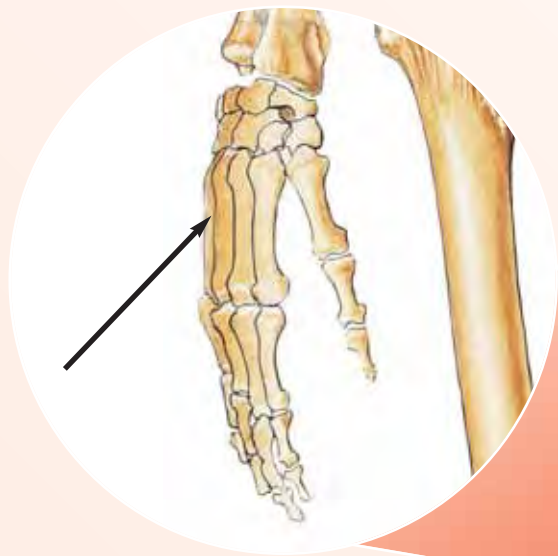
σ▷C<sup>sb</sup>

Niuliq

Niuliq

Processus (ou  
apophyse) mastoide

# Metacarpus



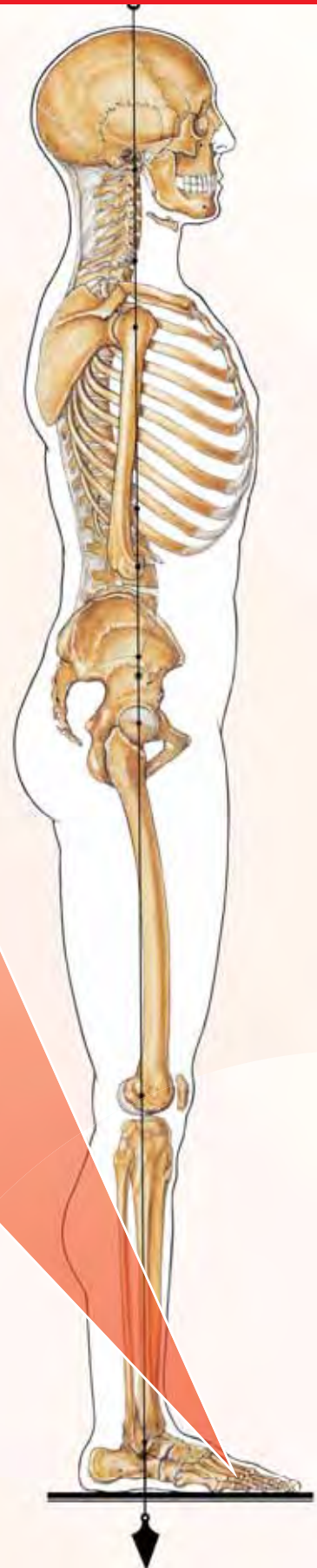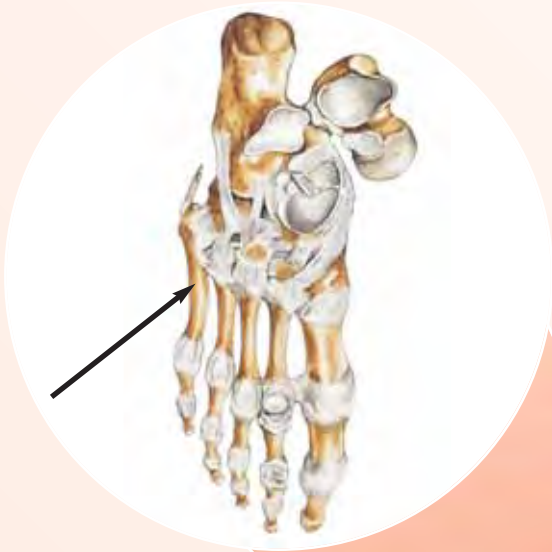< 6 b

Pagvik

Algaup Hauniit

Métacarpe

# Metatarsus

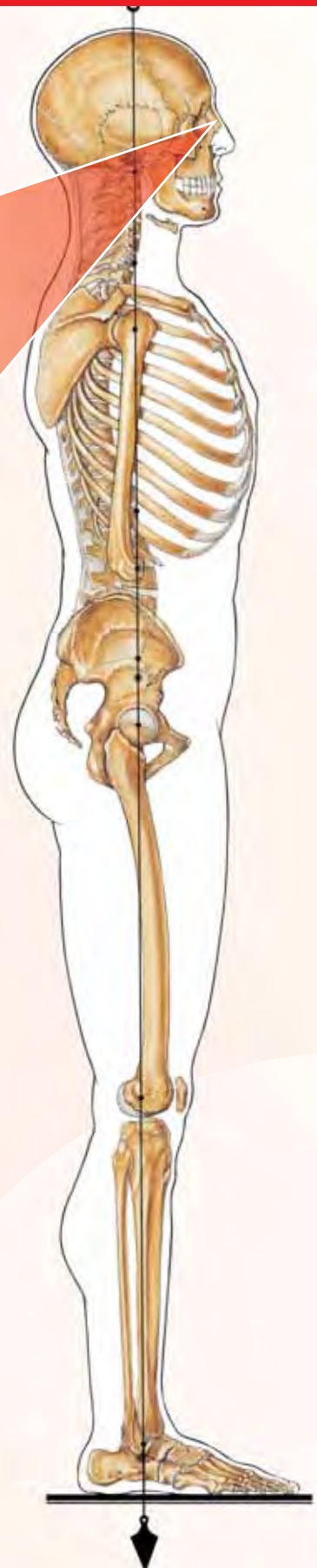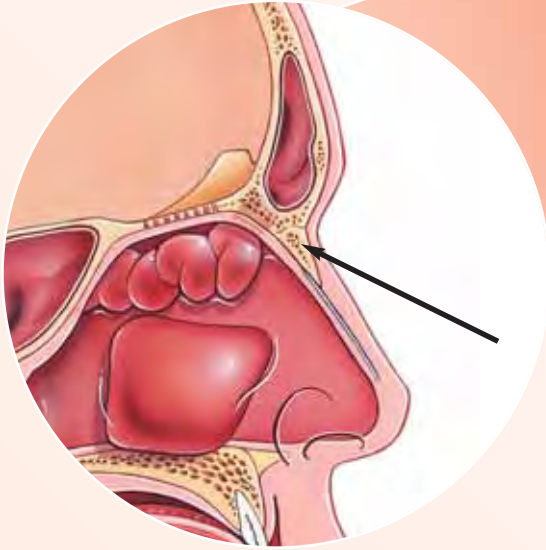


ΔΡΛΔ<  
<Λ&°Γ<

Isigaup  
Pagvingit  
Itikkap Hauniit  
Métatarse



# Nasal Bone



ԳՐՆԱԾՎ ԿԾՏՆ

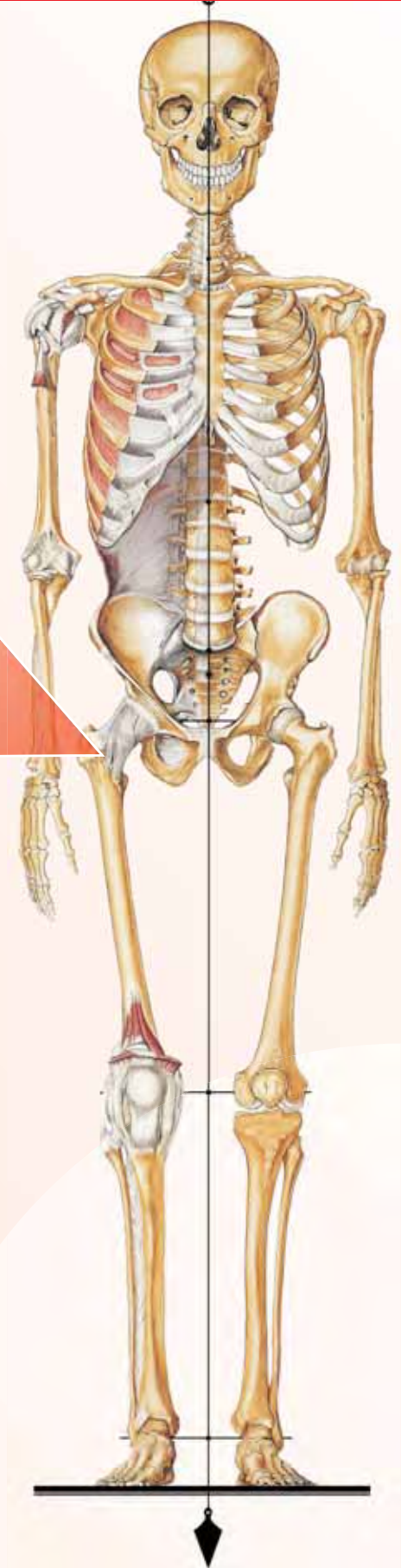
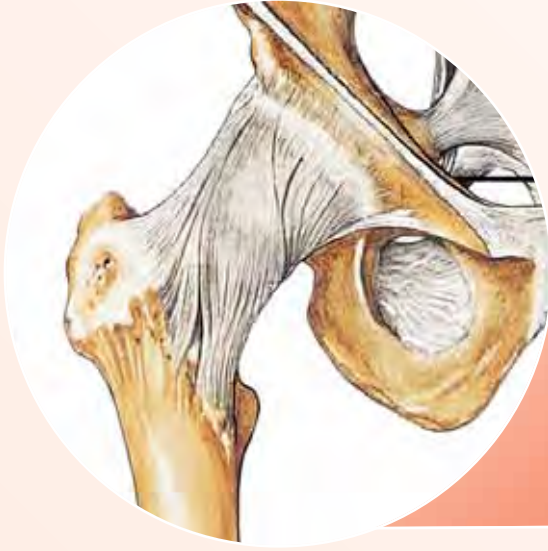
Qingaup

Sauninga

Qingaukhuq

Os du nez

# Neck of the Thighbone, Hip Articulation



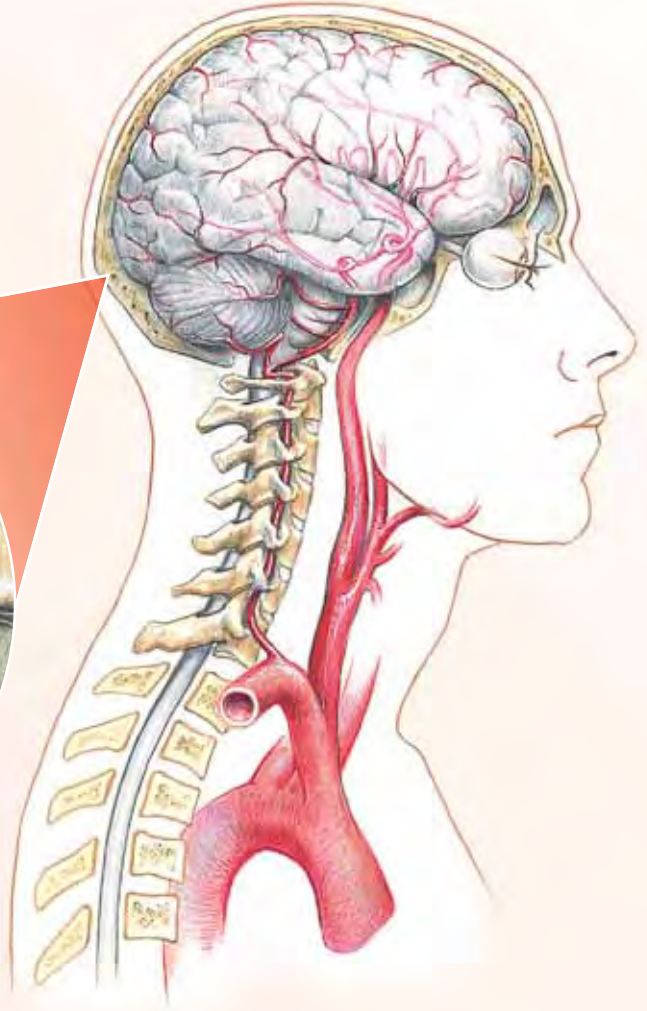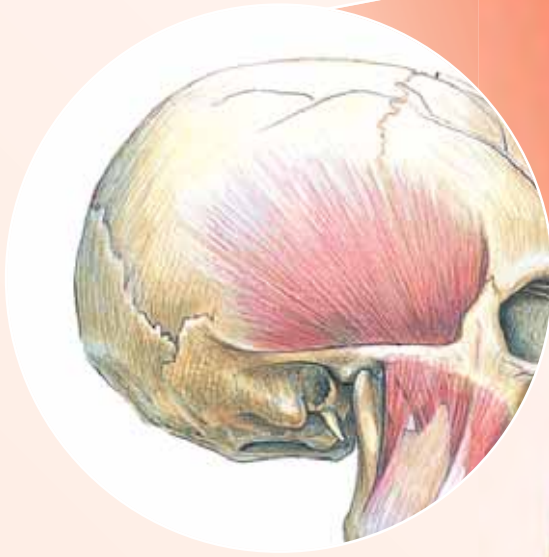
ᐱᑦᐱᐱᐱᐱᐱᐱ

Sivviaq

Hilviaq

Col du fémur,  
articulation de  
la hanche

# Occiput



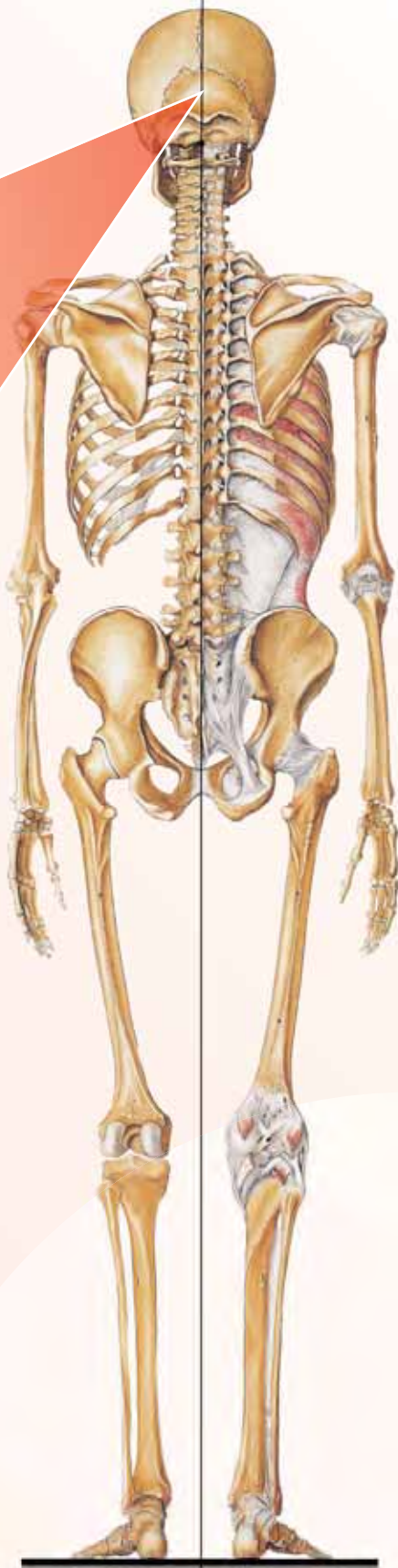
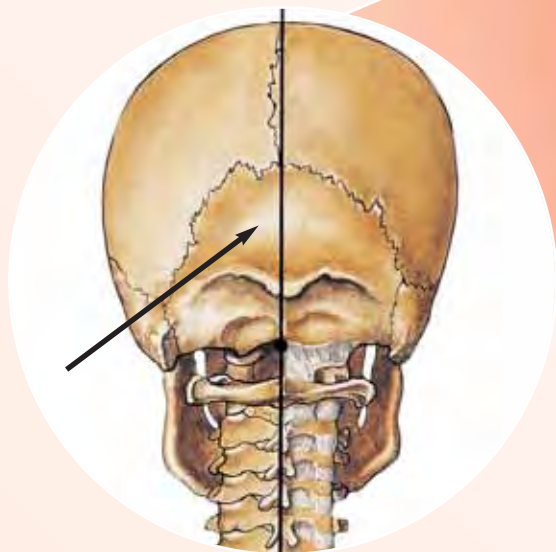
برفك

Tunusuk

Tunuhuk

Occiput

# Occipital Bone



ᠲᠦᠨᠤᠰᠤᠭ ᠯᠢᠰᠢᠨ

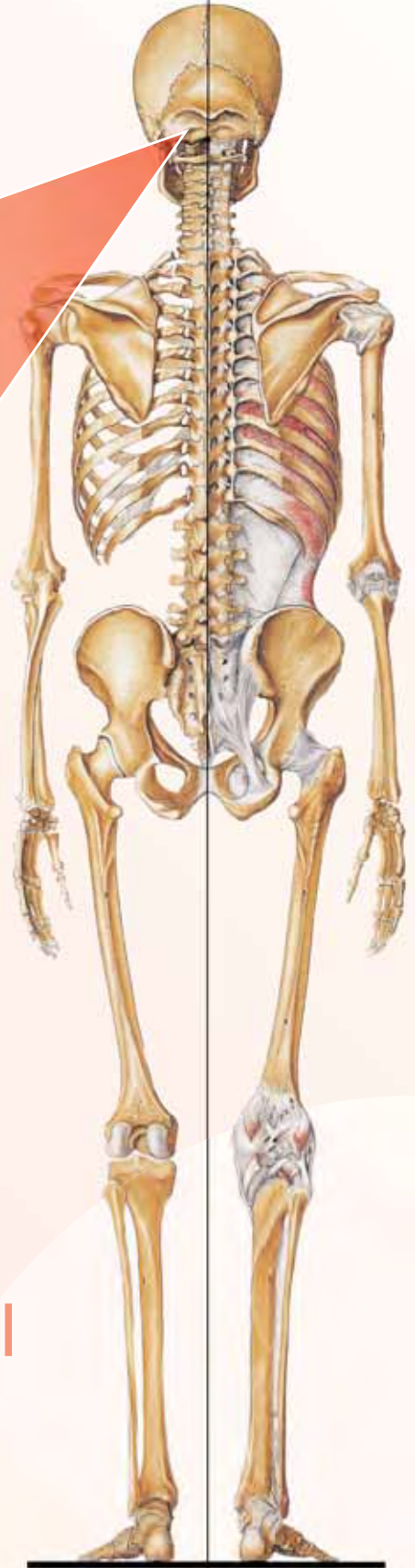
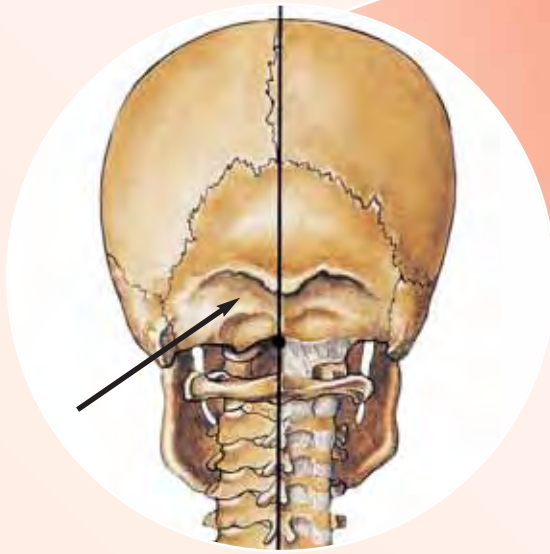
Tunusuup  
Pirninga

Tunuhuk

Os occipital



# Occipital Condyle



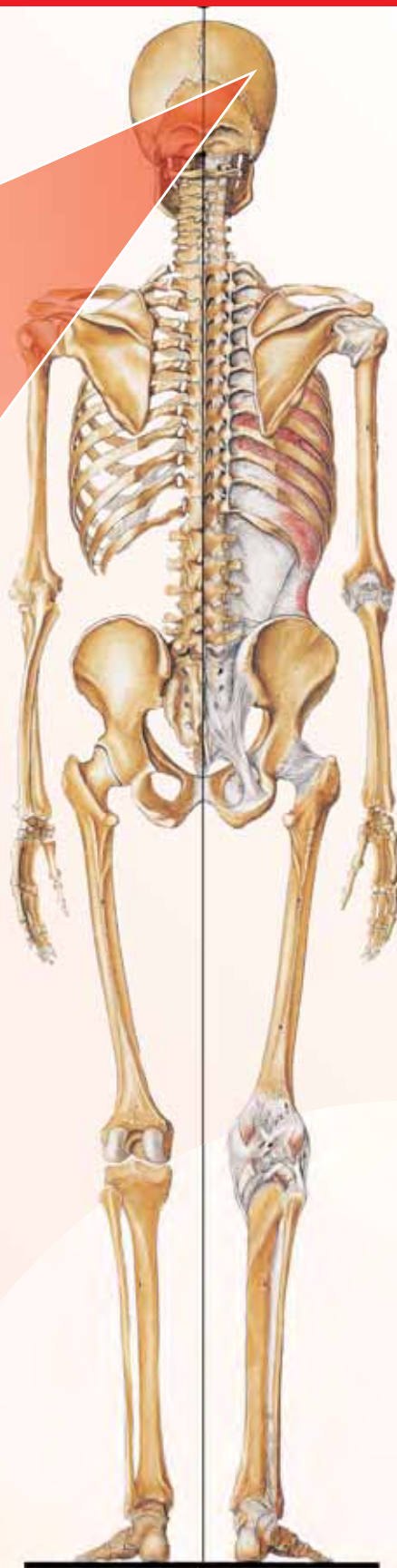
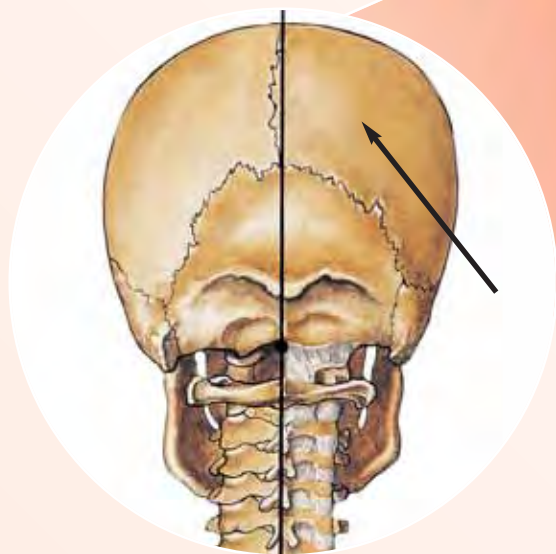
ᐅᑦᑦᑦᑦ ᓄᑦᑦᑦ

Tunusuup  
Niulinga

Niuliq

Condyle occipital

# Parietal Bone



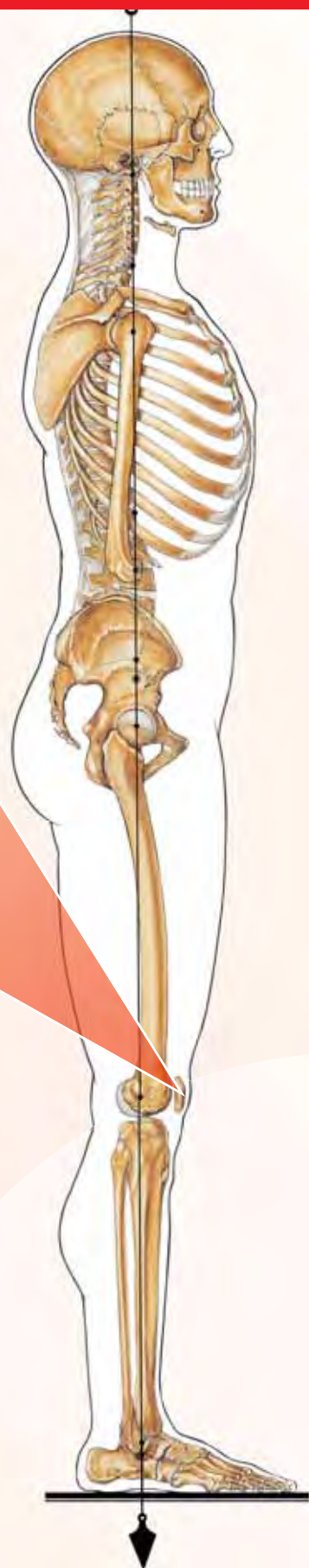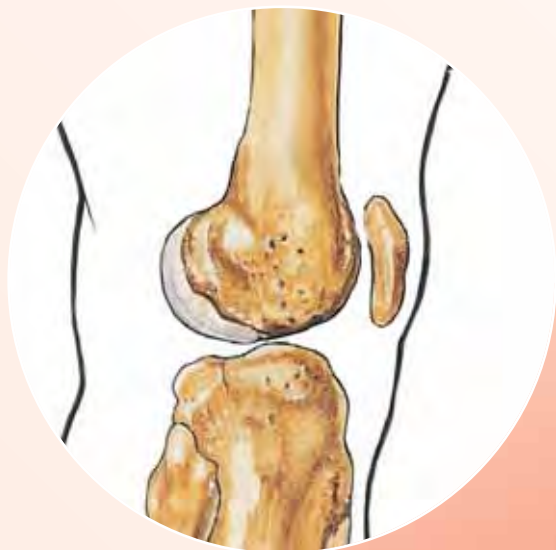Լ՛ԵԵԳԵ

Makkaq

Kaavyiup Haunia

Os pariétal

# Patella / Kneecap



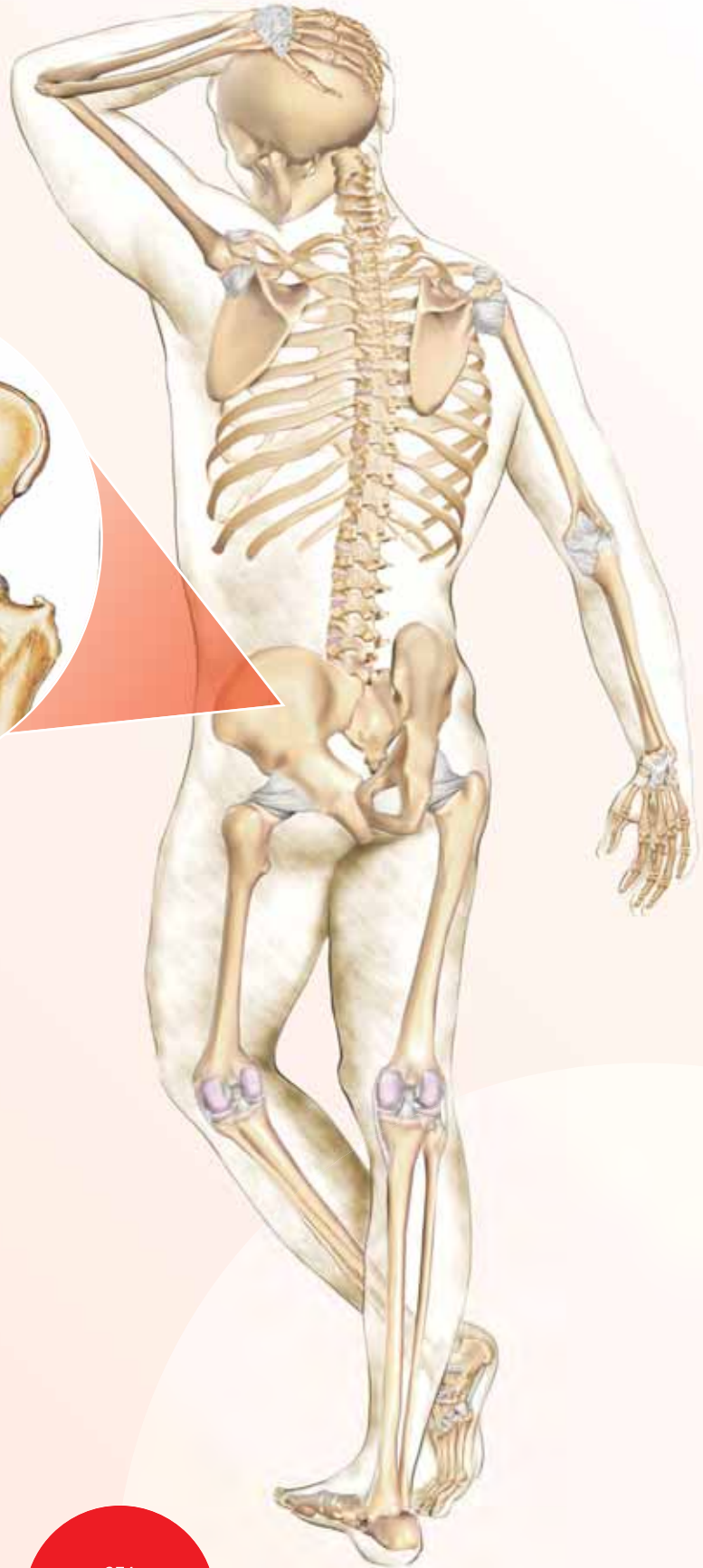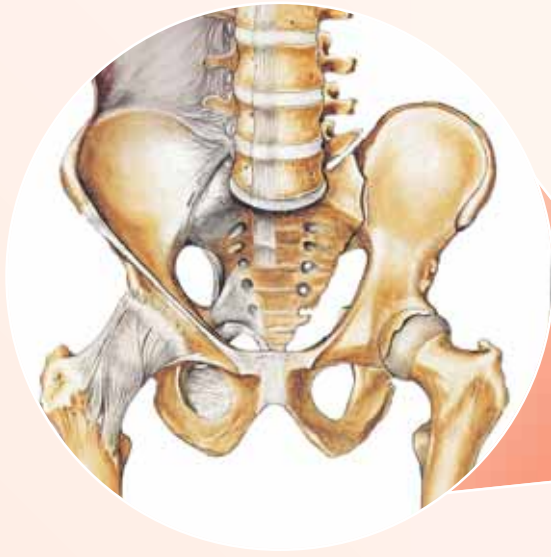
ᐃᑦᐃᑦᐃᑦ

Siiqquaq

Hiitquaq

Rotule

# Pelvis



ԺԿՈՎԵ

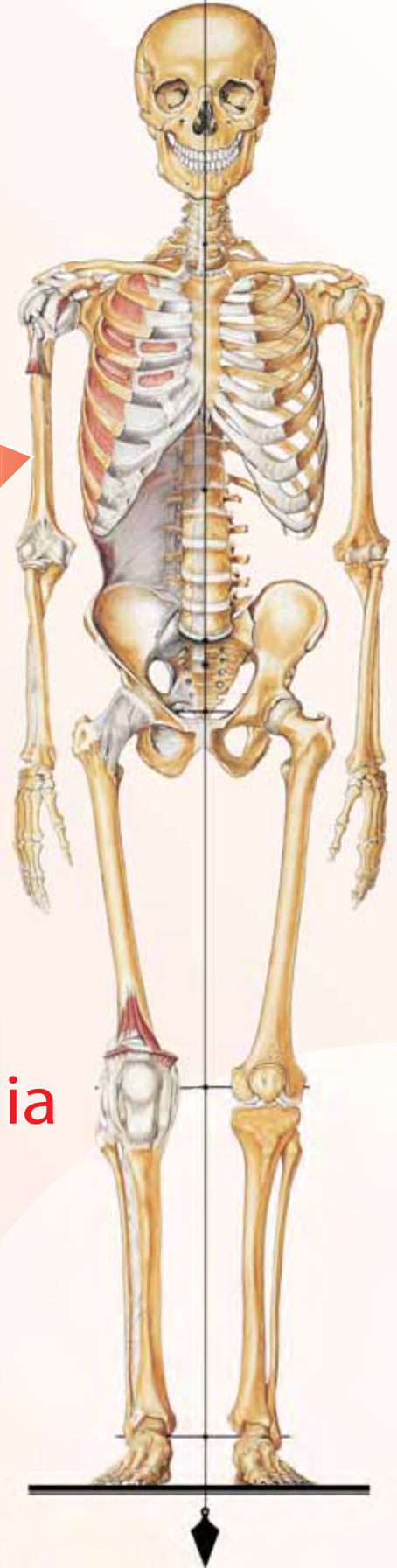
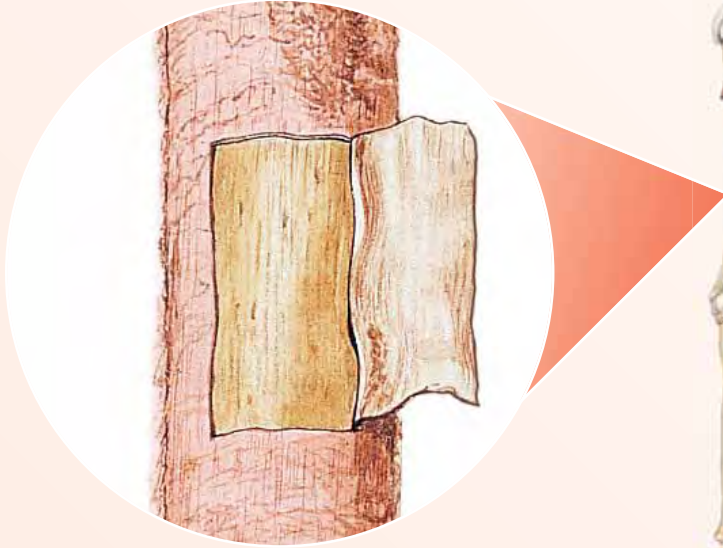
Kuuttiq

Kuuttiq

Bassin



# Periosteum



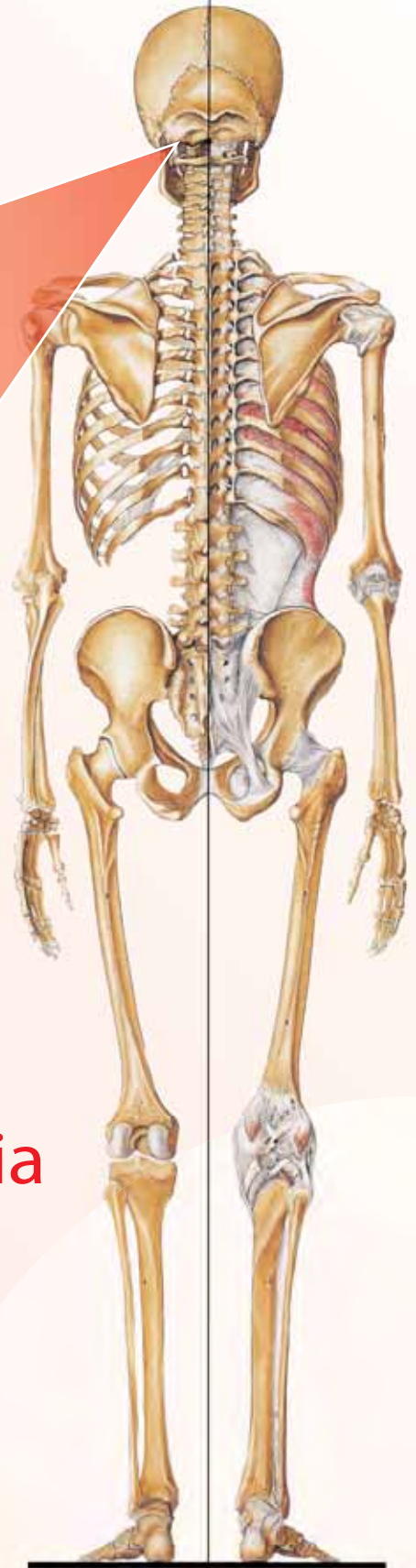
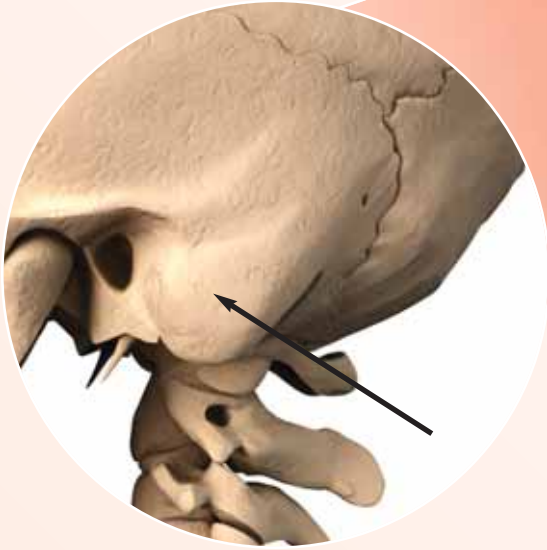ΔΛσ<sup>9b</sup>

Ipiniq

Haun'ngup Mamia

Périoste

# Petrous of Temporal Bone



ᐱᐅᐅᐅᐅᐅᐅ

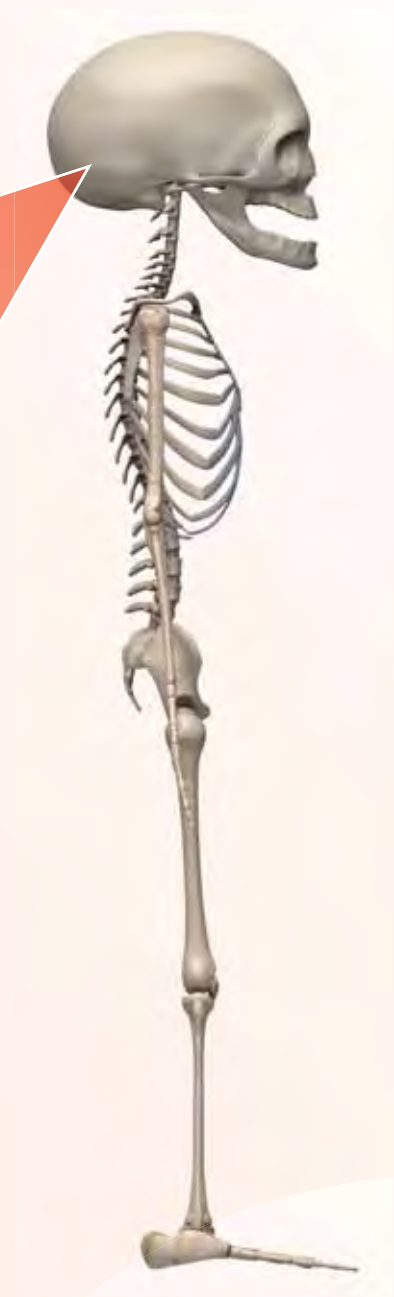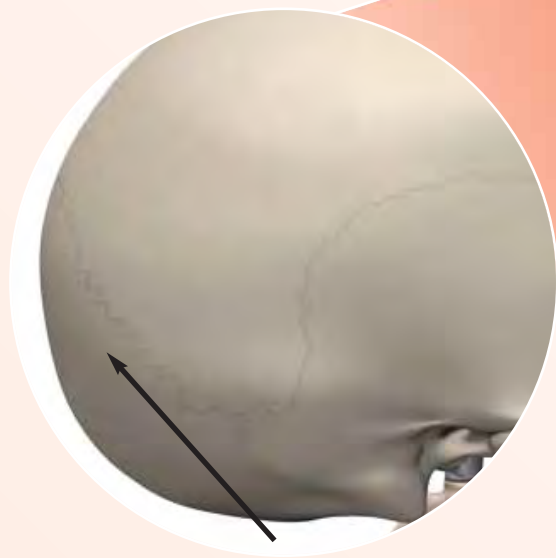Siunnaq

Tuuttiniup Haunia

Rocher de l'os  
temporal



# Posterior Fontanelle



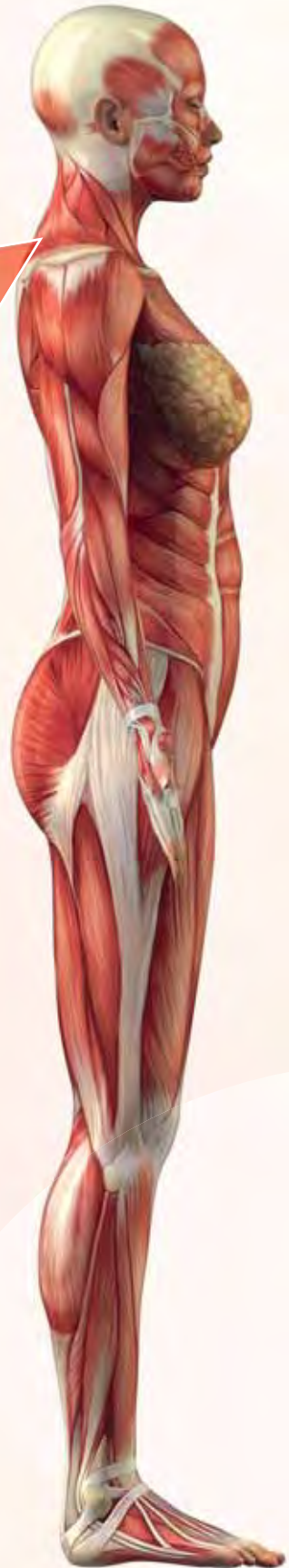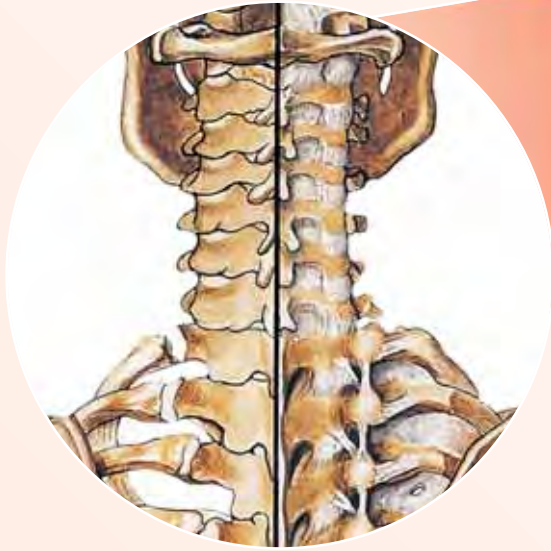Avaag

Tunuhuk

Fontanelle postérieure



# Protuberance of the First Dorsal Vertebra, Bump



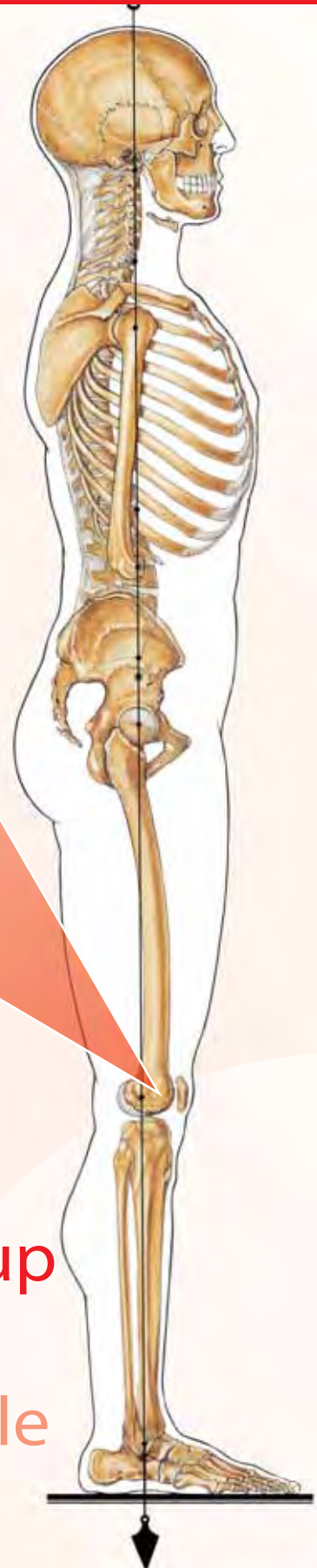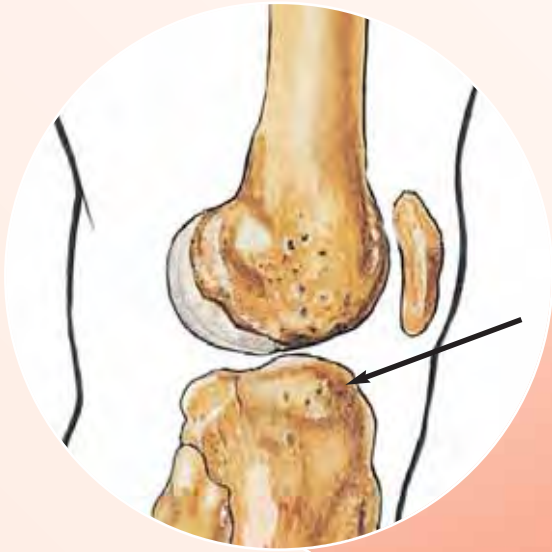
$\Lambda d^b$

Pikuk

Pikuk

Vertèbre  
proéminente  
dorsale

# Proximal Epiphysis



ᕿᐅᓂᐅᕐ

ᐅᓂᓂᓂᓂᓂ

Sauniup

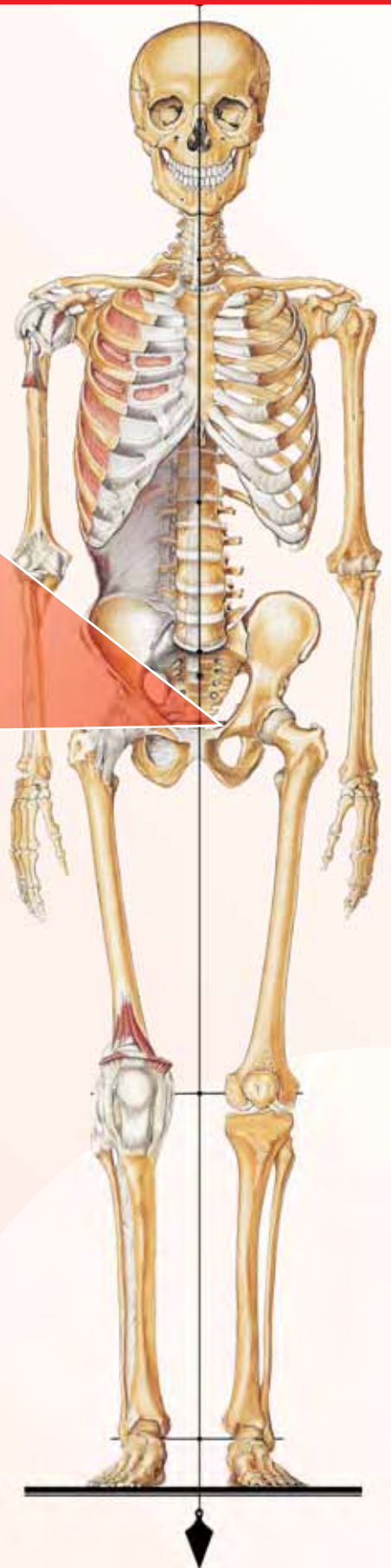
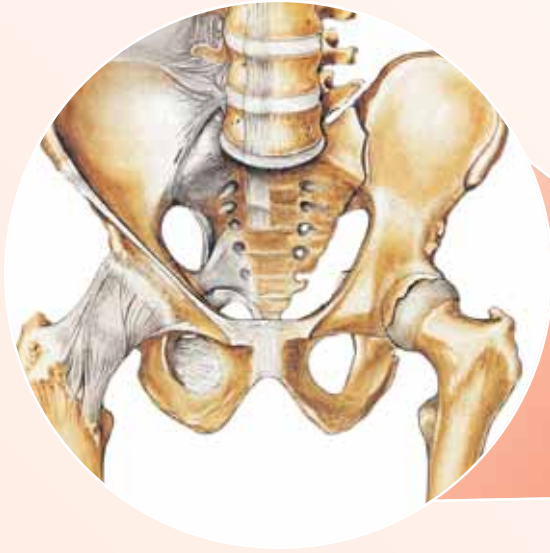
Tunnganinga

Ihugluit/Ipiringniup

Qaqqulaanga

Épiphyse proximale

# Pubic Bone

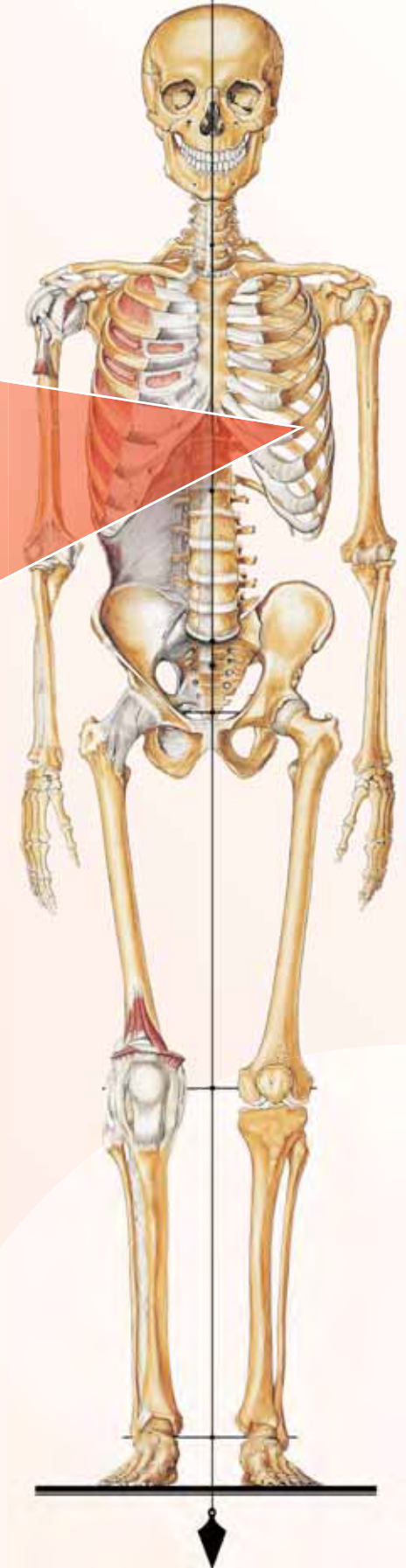
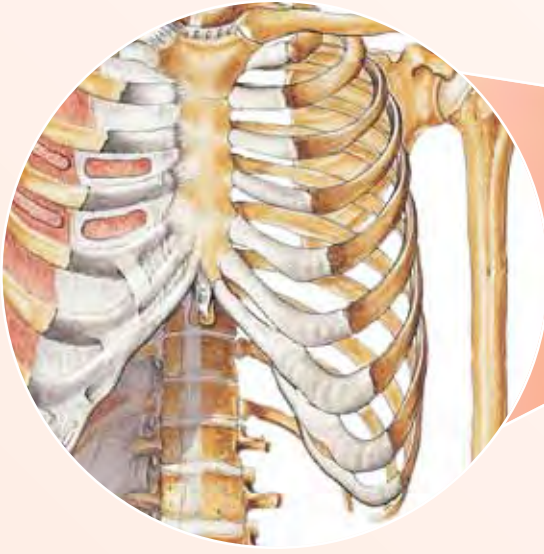


ᐃᓴᓯ  
Ingi  
Ingik  
Pubis





# Rib



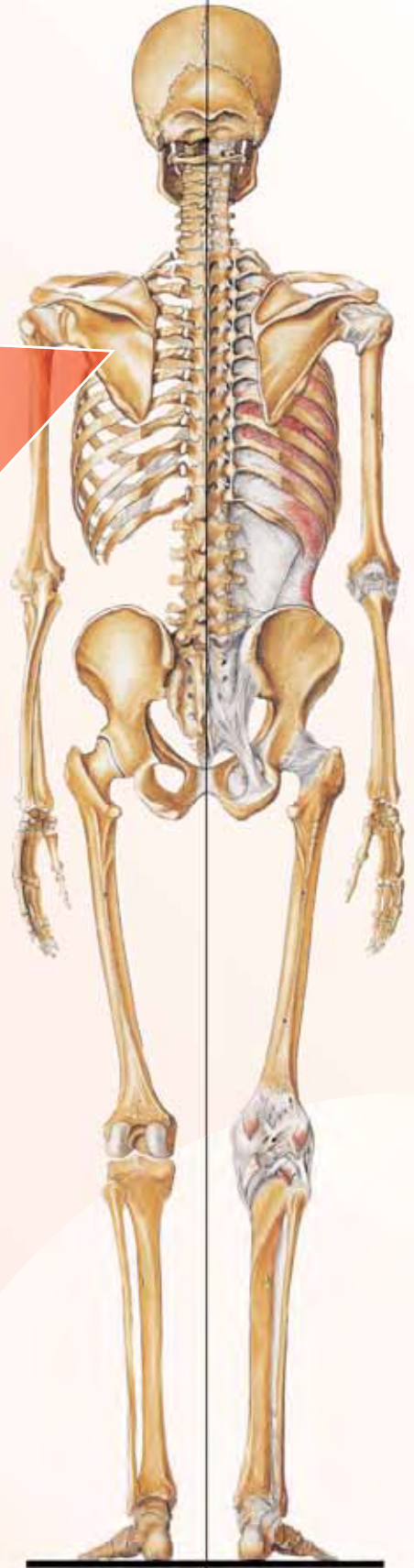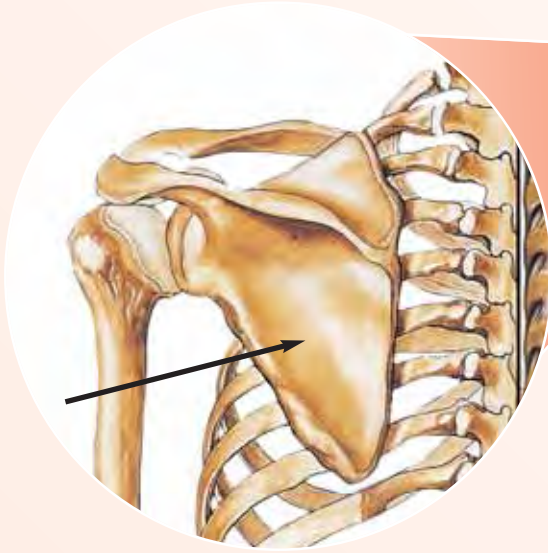
ᐃᐱᐱᐅᑦ

Tulimaaq

Tulimaaq

Côte

# Scapula / Shoulder Blade



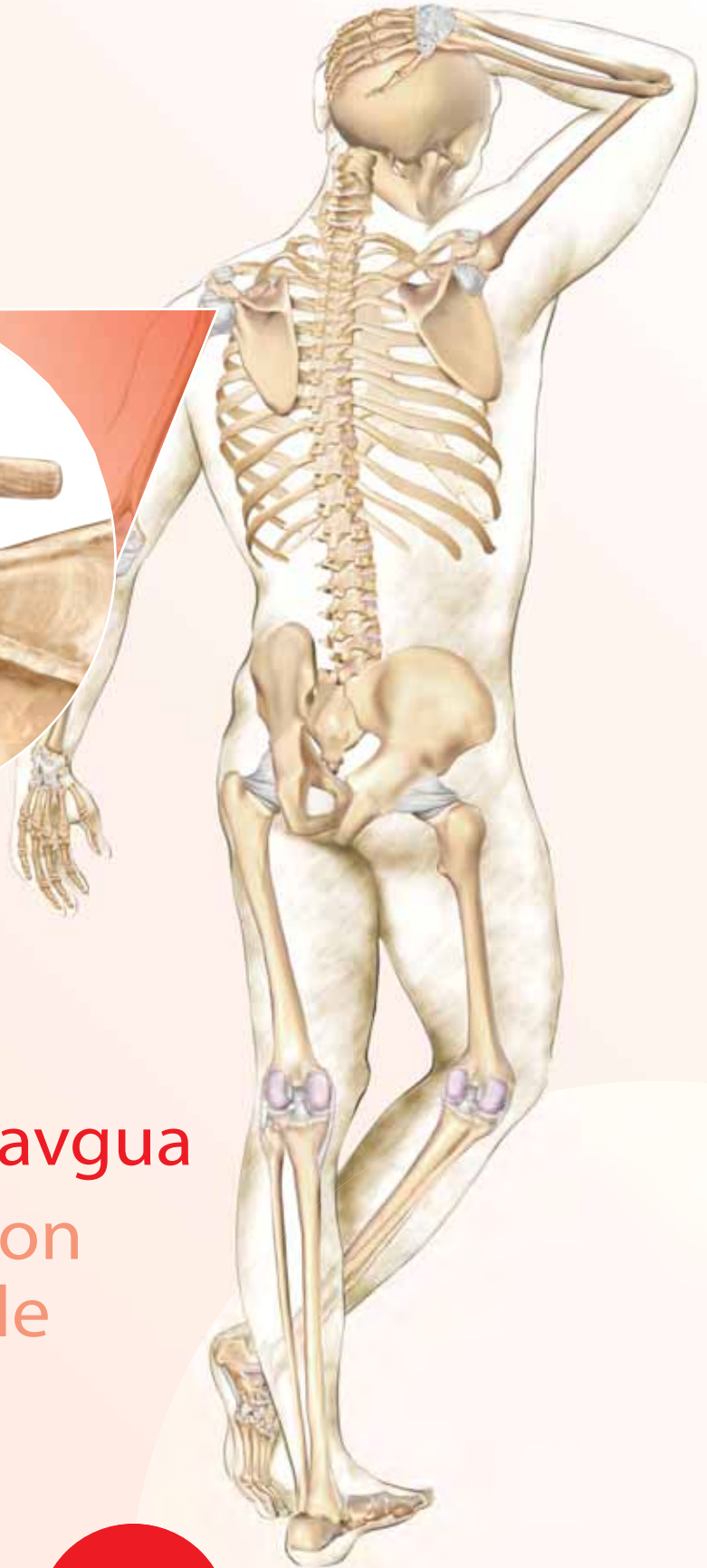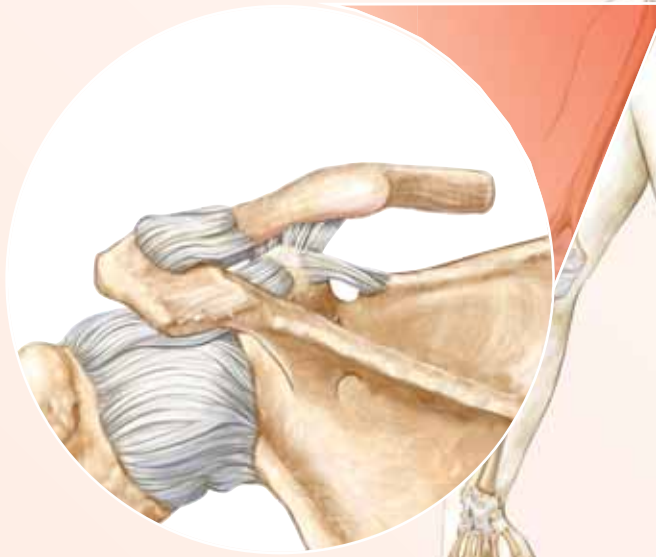
ᐃᐱᐃᐅ

Kiasik

Kiahik

Omoplate ou  
scapula

# Shoulder Joint



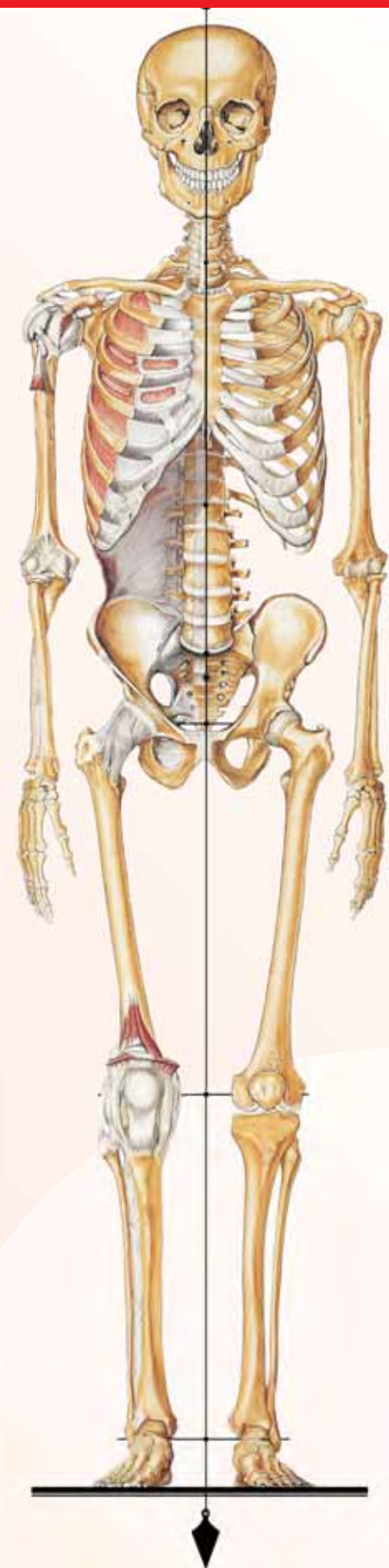
σς<sup>ϵ</sup> ρ<sup>ϵ</sup>β

Nigalluq

Tuigup Navgua

Articulation  
de l'épaule

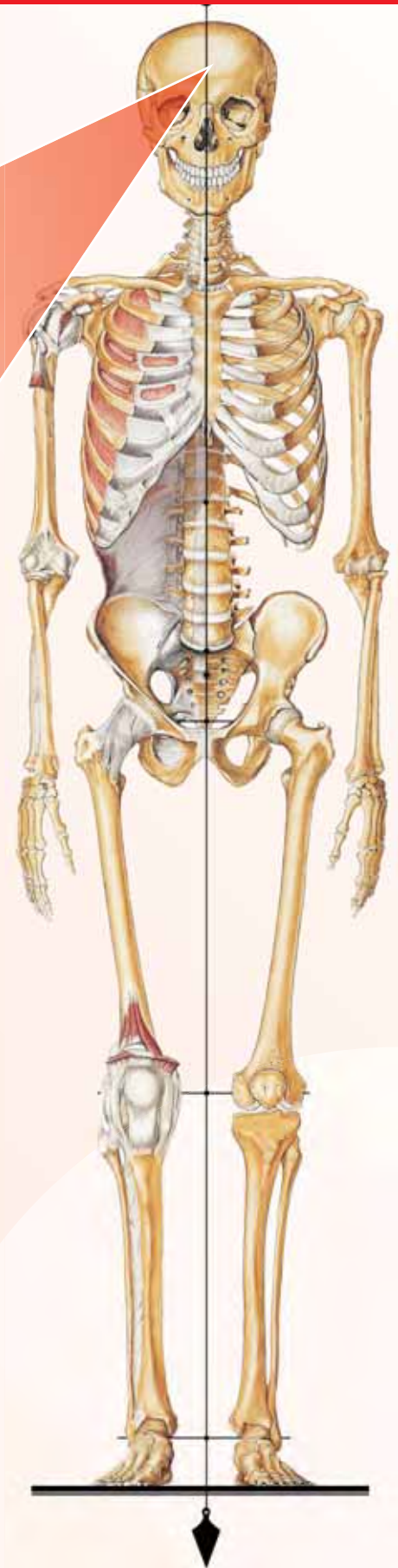
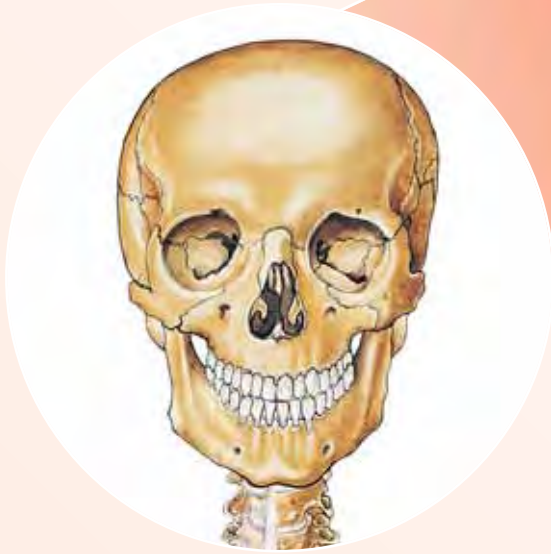# Skeleton



ᕐᕈᕐᕐᕐᕐᕐᕐ  
Sauniinnaq  
Haun'ngit  
Squelette



# Skull



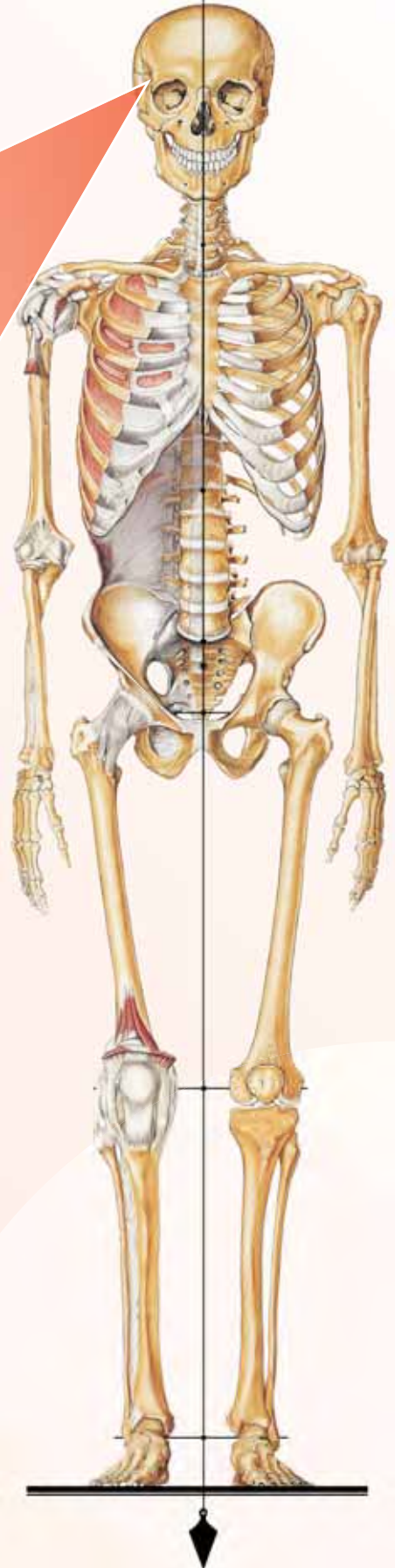
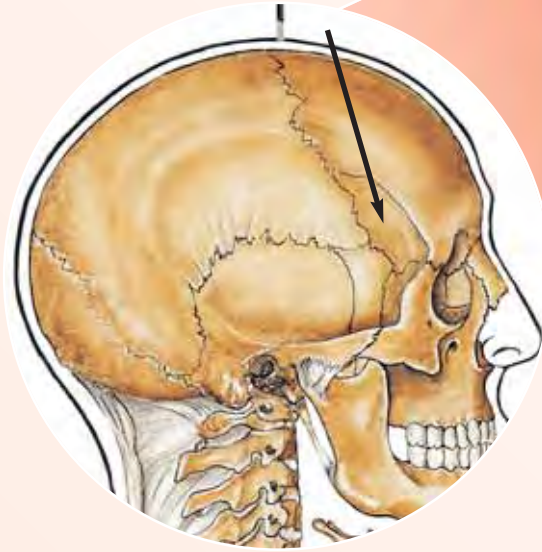
ᓄᐱᐱᐱᐱᐱ

Niaquq

Niaqqup Haunia

Crâne

# Sphenoid Bone



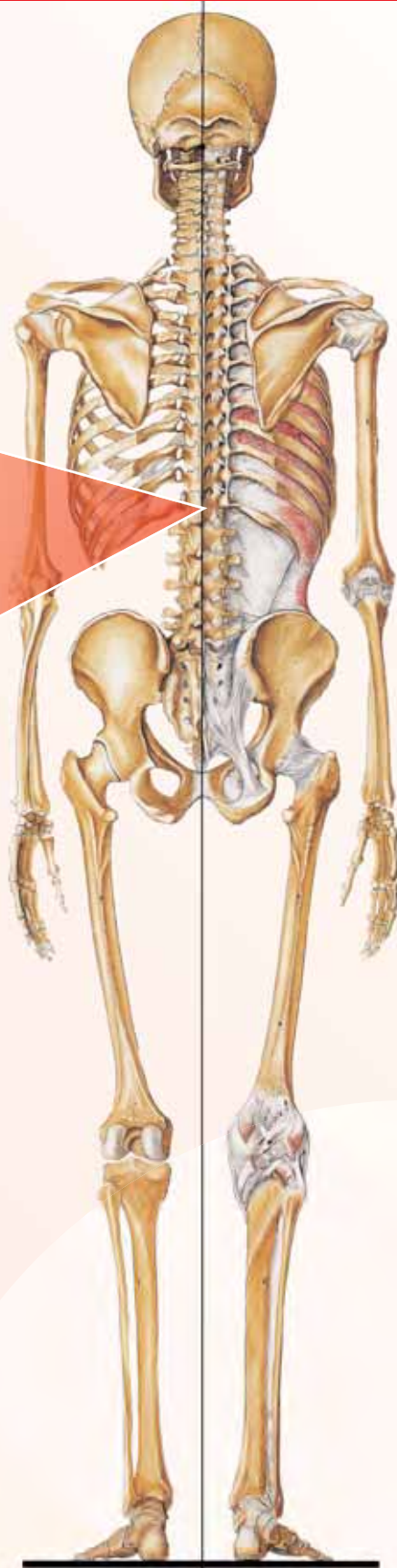
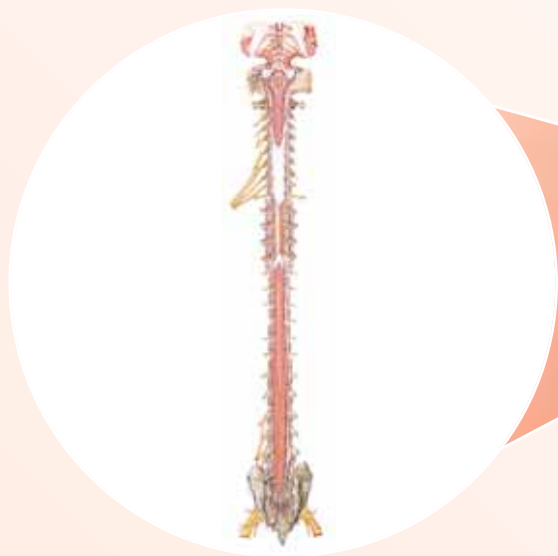Δ ၄၆၂ ၄၆

Iqsaq

Hiutiqarvik

Os sphénoide

# Spinal Cord



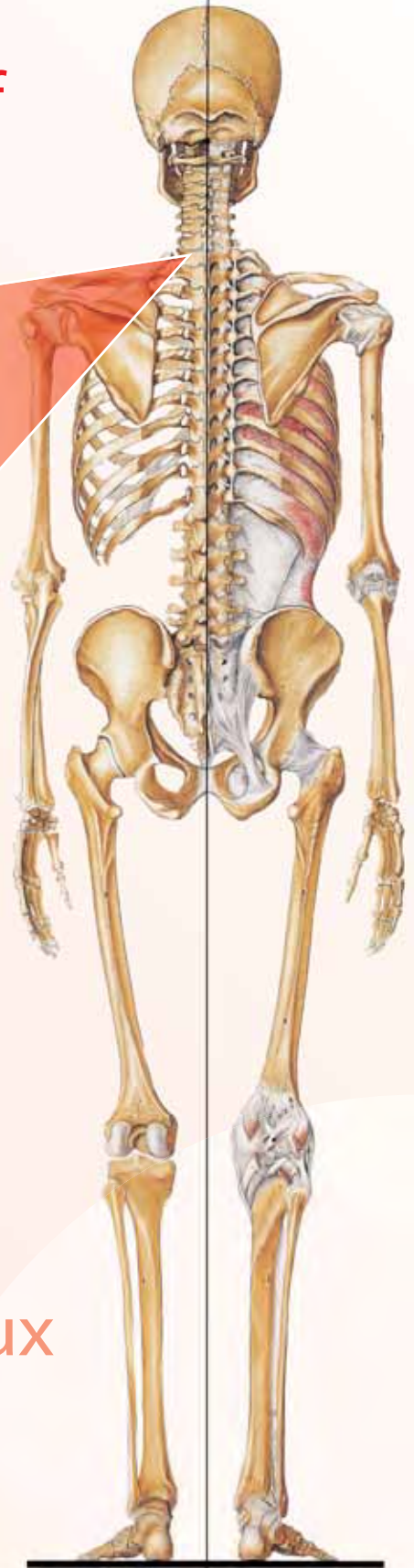
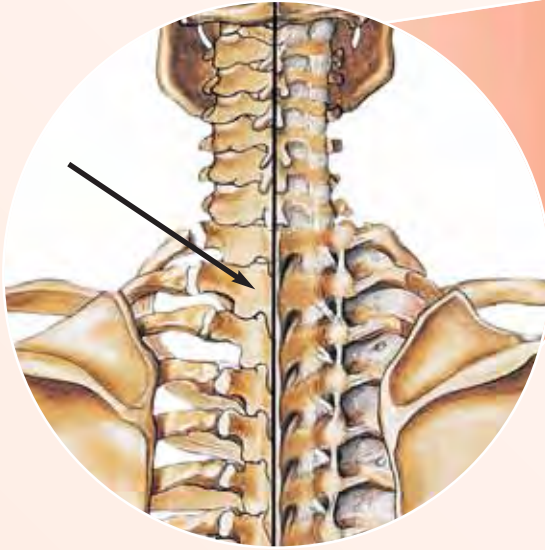
ᄎᄎᄎᄎ

Qitiraq

Qitiraq

Moelle épinière

# Spinal Process of the First Thoracic Vertebrae



Ad

Piku

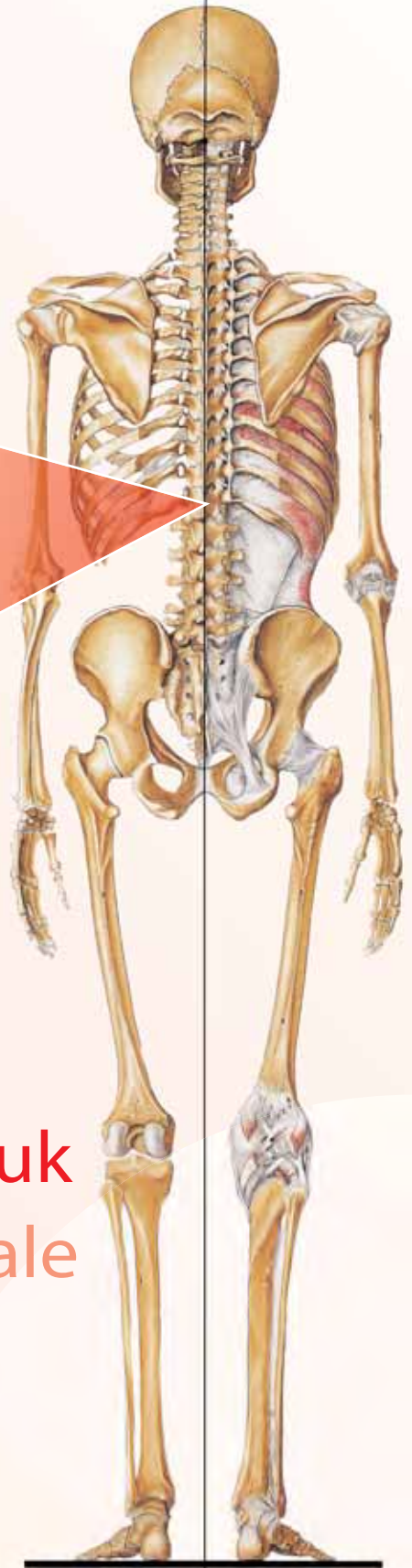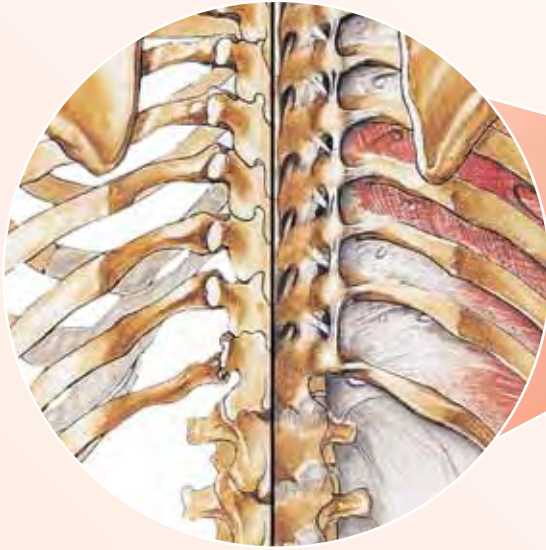
Kuapigaup

Nungummaa

Processus épineux



# Spine



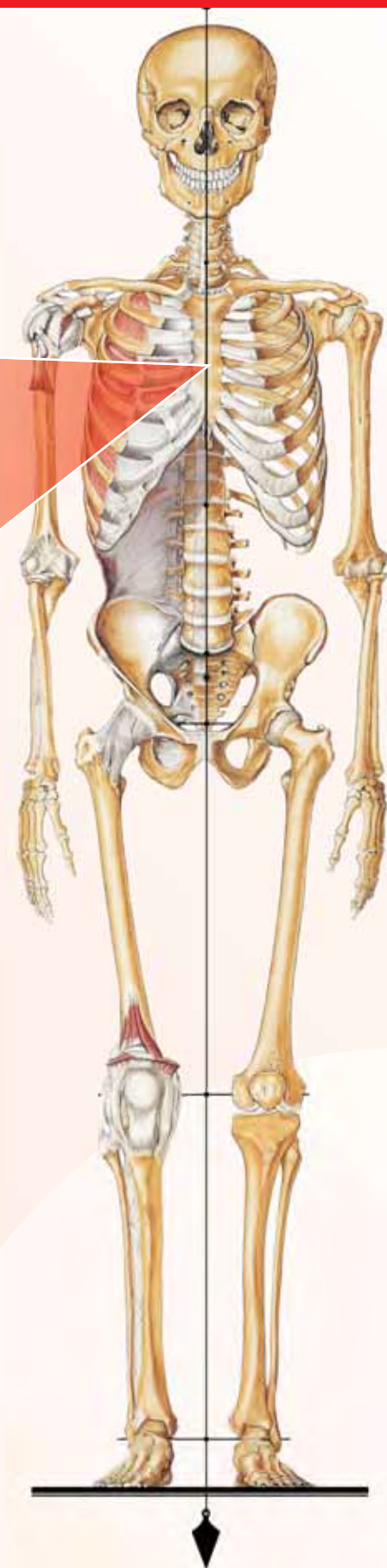
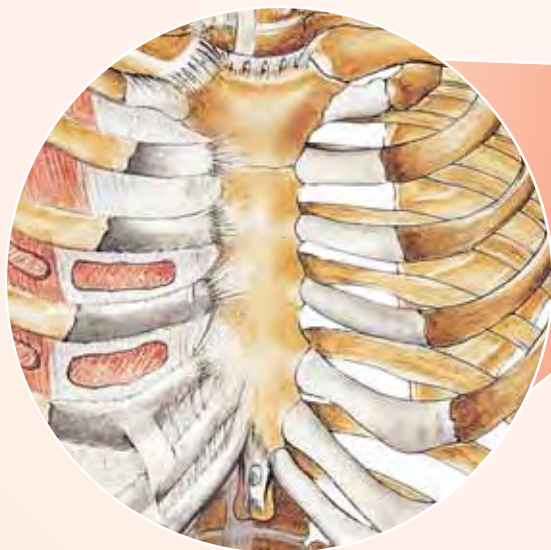
ᄃᄃᄃᄃᄃᄃ

Qimirluk

Kuapigaq/Qimirluk

Colonne vertébrale

# Sternum / Breastbone



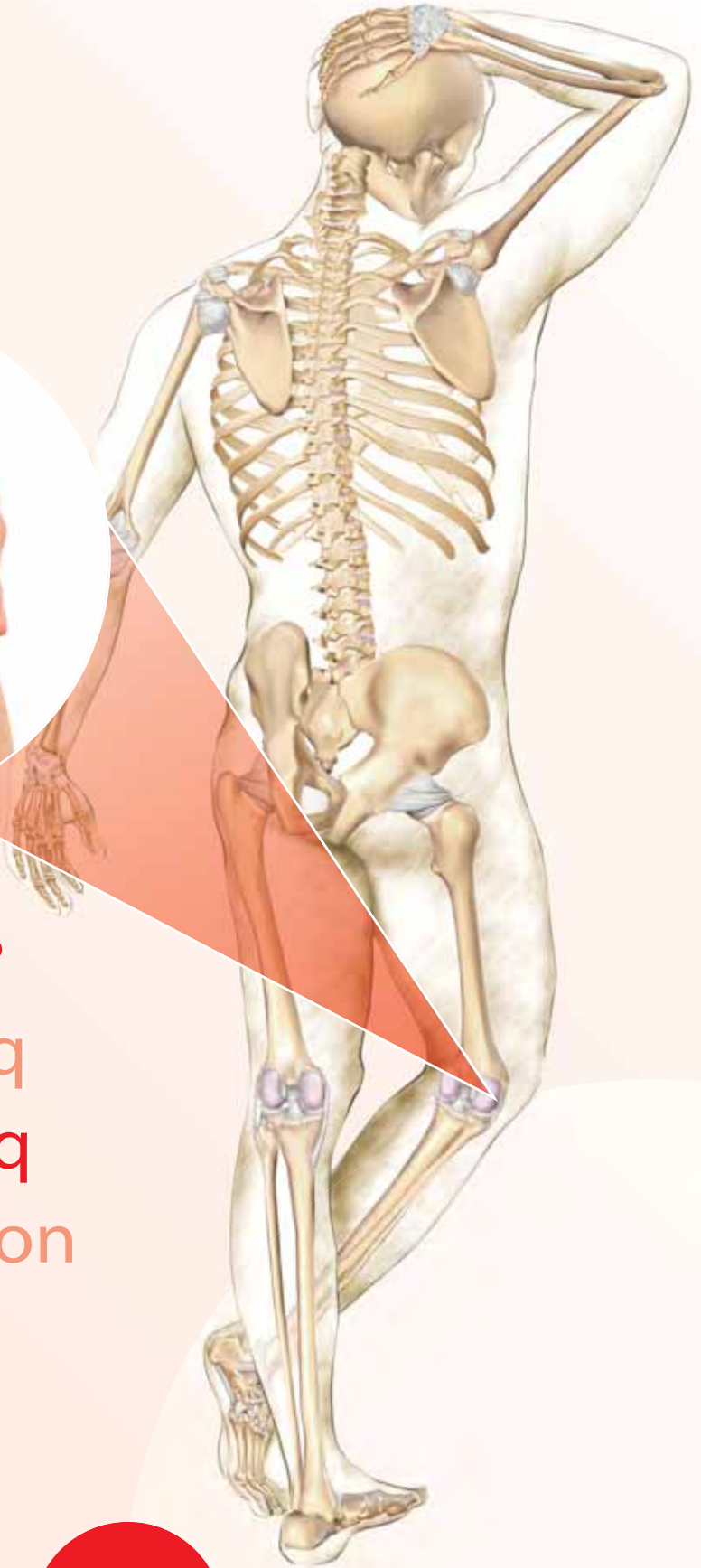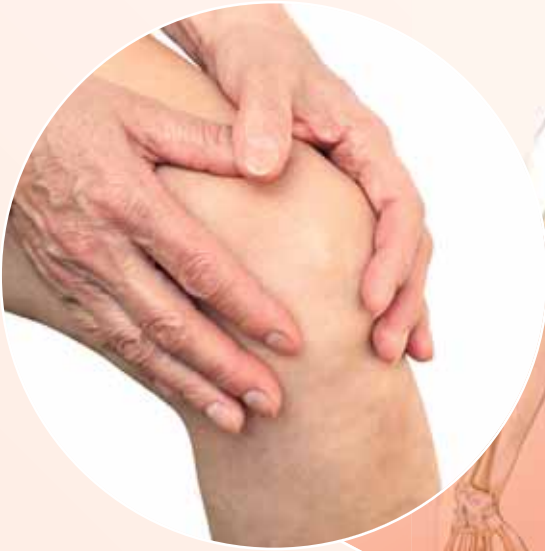ᐱᐳᐱᐳ

Sagvik

Hakiak

Sternum

# Stiffen Joint



ᐃᑦᑲᑦᑲᑦᑲᑦ

Nuqaqtuq

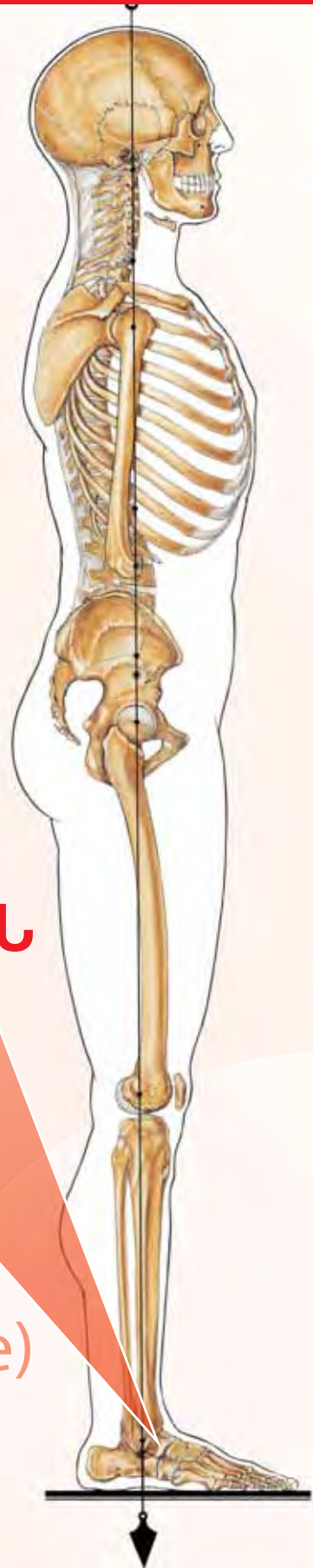
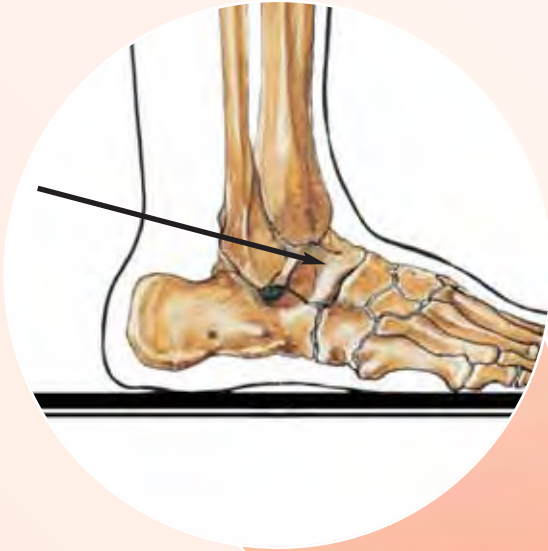Tumaqtuq

Articulation

raidie



# Talus / Astragalus



ᲠᲚᲛᲗ᲏Რ ᲛᲗ᲏ᲠᲗ᲏Რ

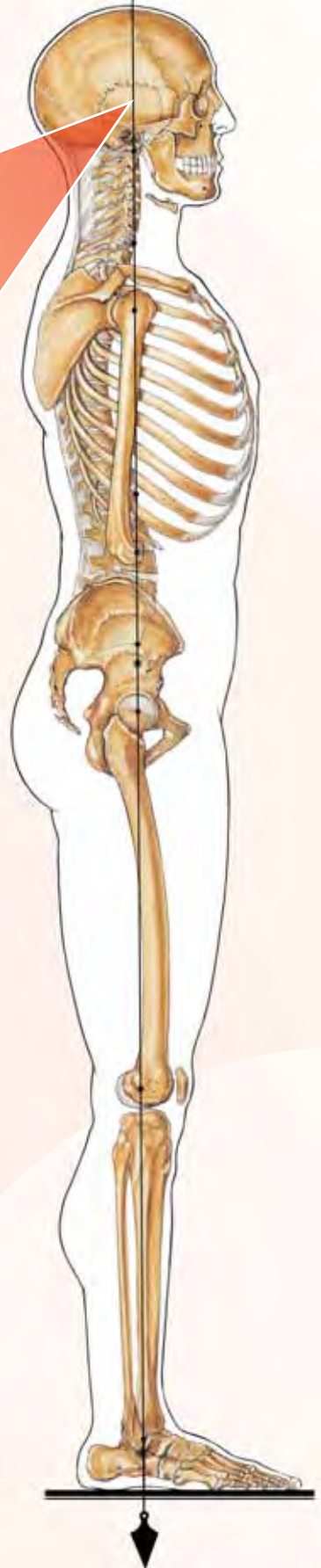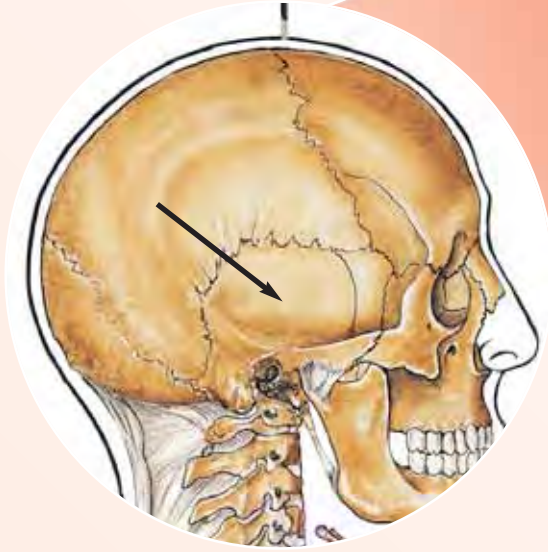
Singirniup  
Nagguanga

Itigaup  
Nabluangit

Talus (ou astragale)

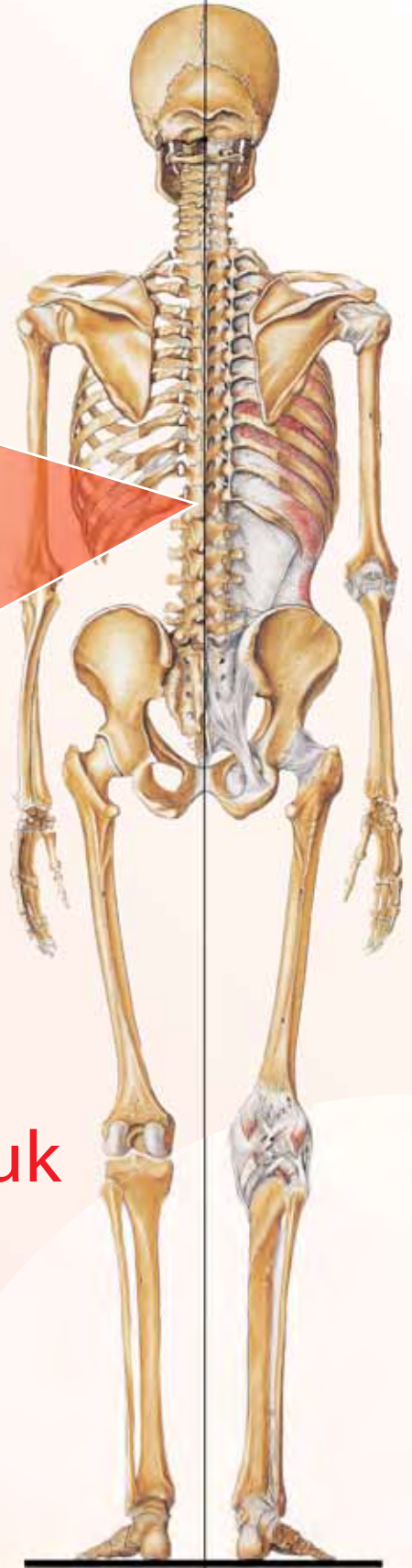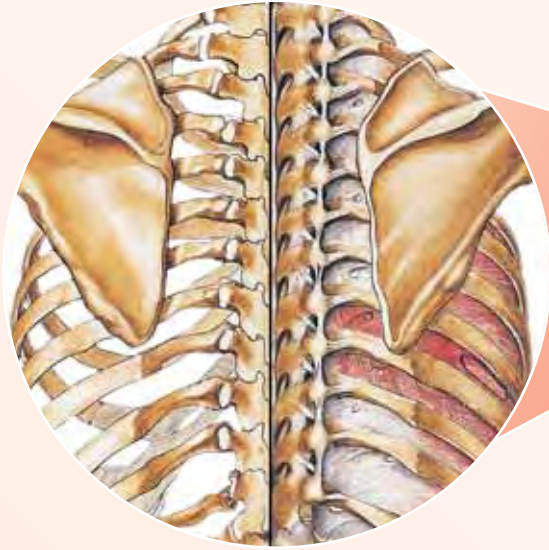


# Temporal Bone



Δῆβλῶς ἠδῶσῶν  
Iqsaup Sauninga  
Tuuttiniup Haunia  
Os temporal

# The 12 Dorsal Vertebrae



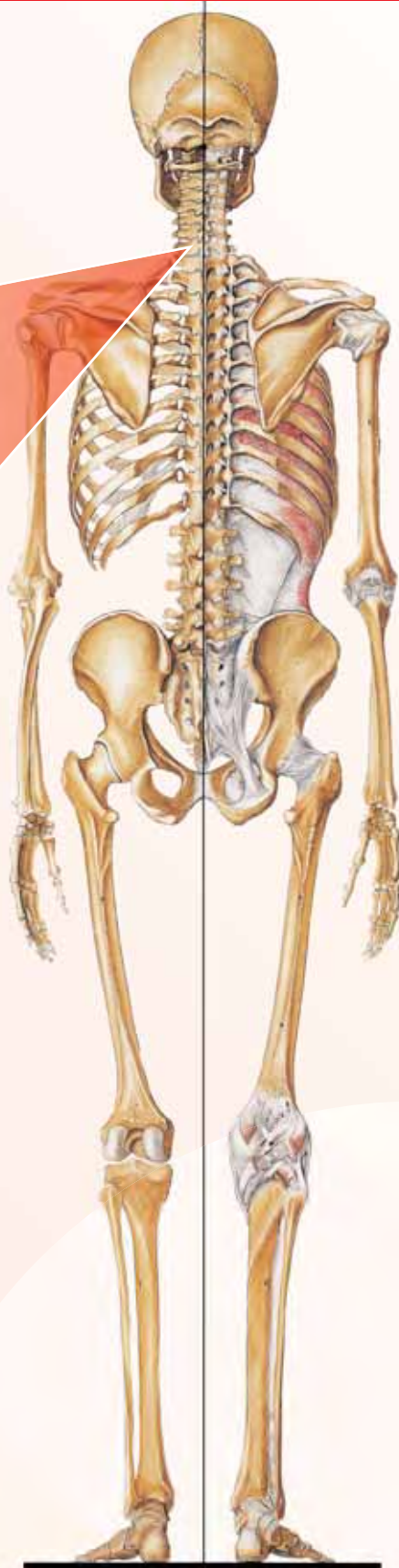
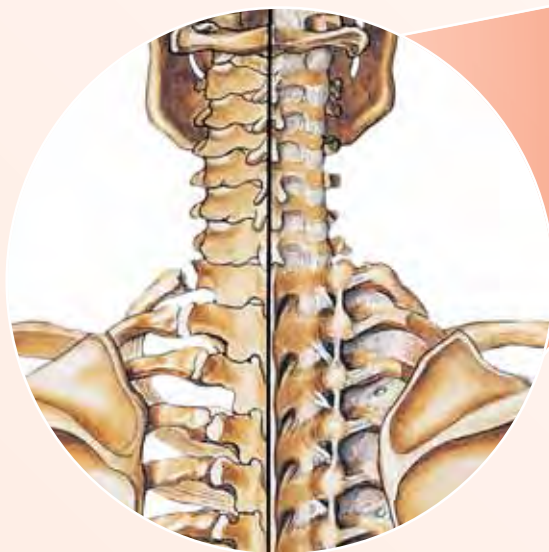
ᄋᄋᄋᄋᄋᄋ

Qimirluk

Kuapigaq Qimirluk

Les 12 vertèbres dorsales

# The 7 Cervical Vertebrae



ᑭᑭᑭᑭᑭᑭᑭᑭ

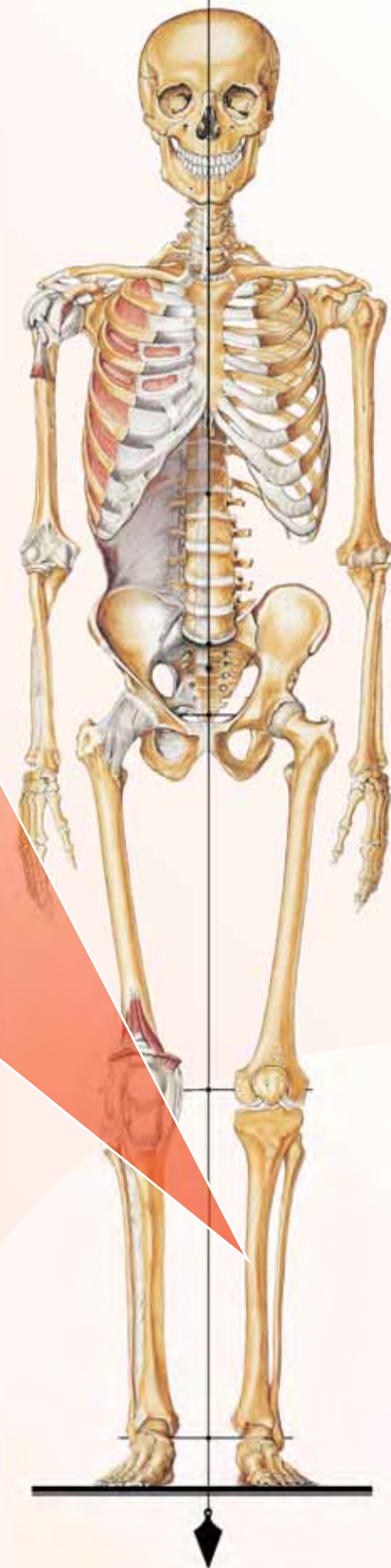
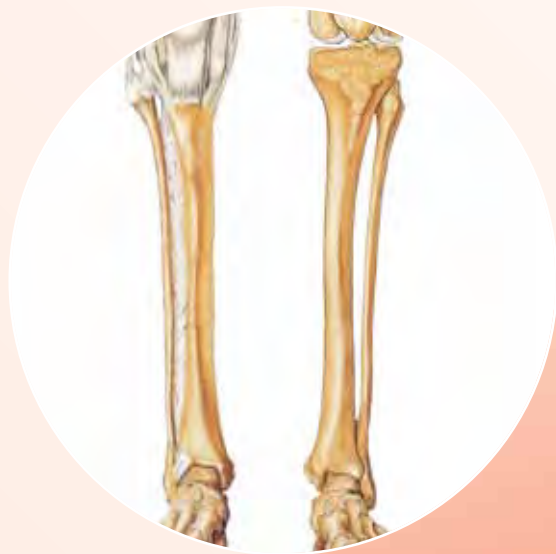Qungasiq

Niuliq

Les 7 vertèbres  
cervicales



# Tibia / Shinbone



հրէկ ԳԵ

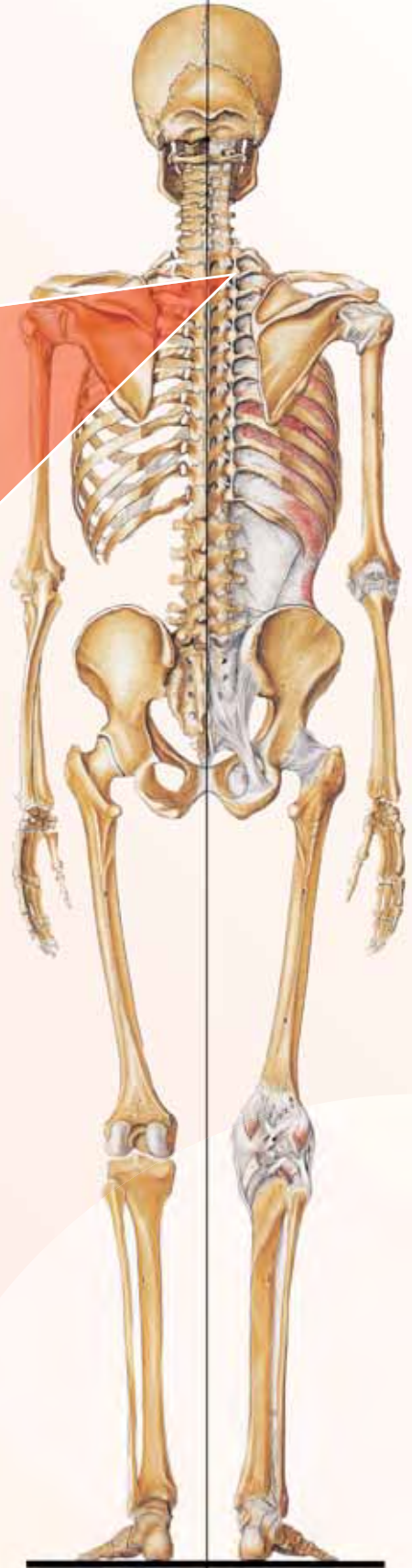
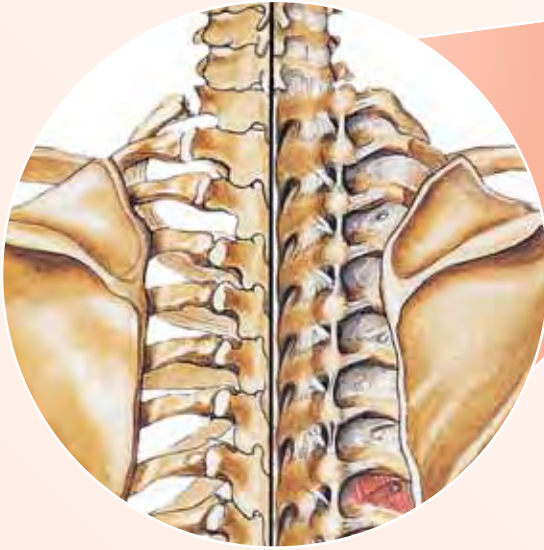
Qingaaq

Qingaaq

Tibia



# Transverse Process



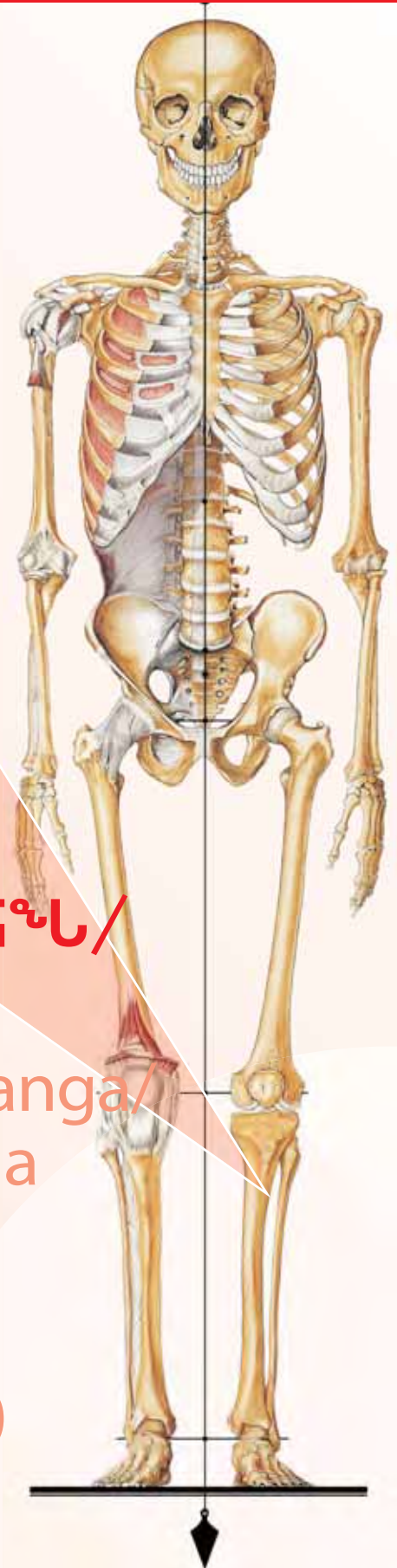
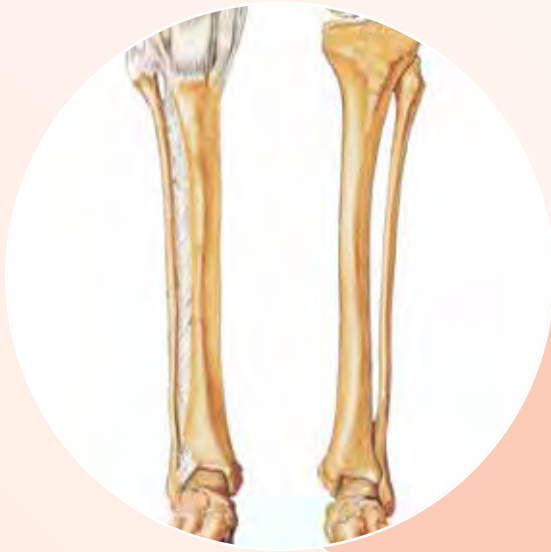Δ50°

Isatit

Kanivautiqarvik

Processus  
transverse

# Ulna / Fibula



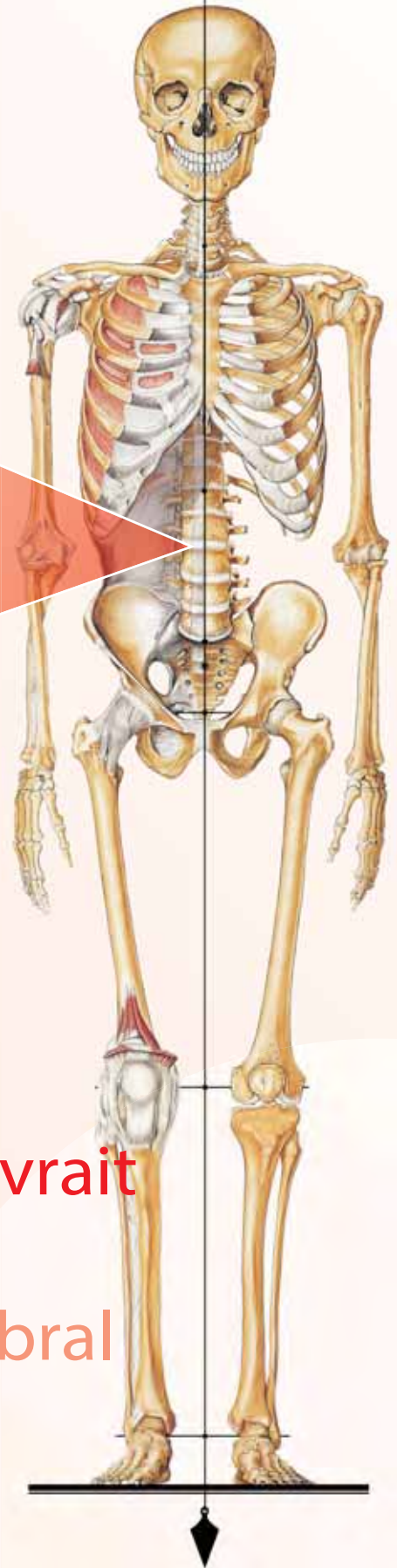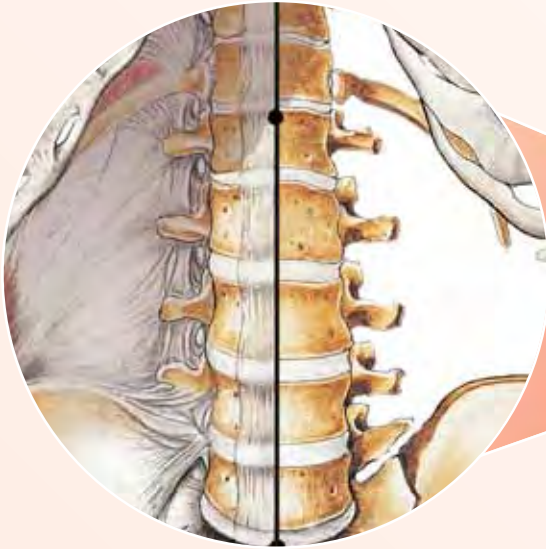
ԱՆՈՒՅՑ ԱՐԿԱՆ/  
ԲՉՑ ԱՐԿԱՆ

Aggautiup Amiliranga/  
Kanaap Amiliranga

Amiliraq

Cubitus (ou ulna)  
péroné (ou fibula)

# Vertebral Body Inter-Vertebral Disc



Δῖλσᶜᵇ

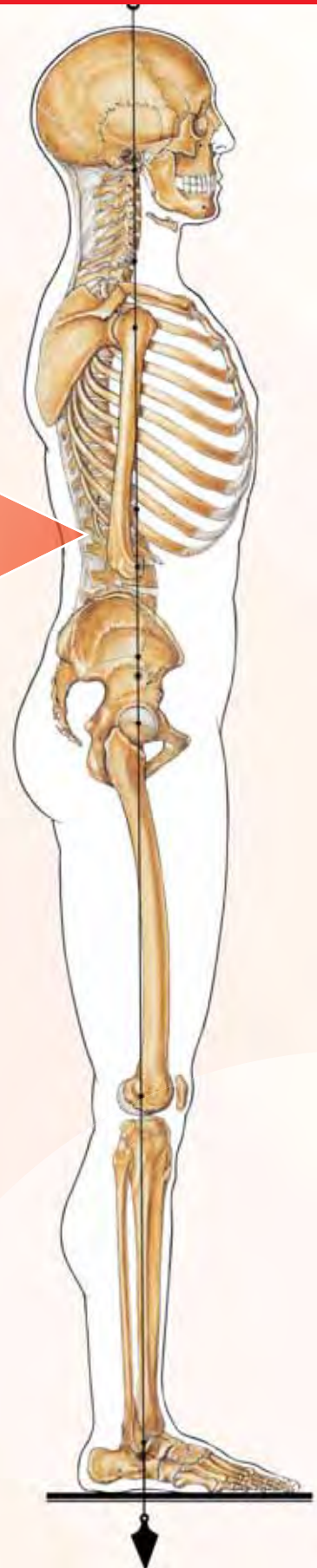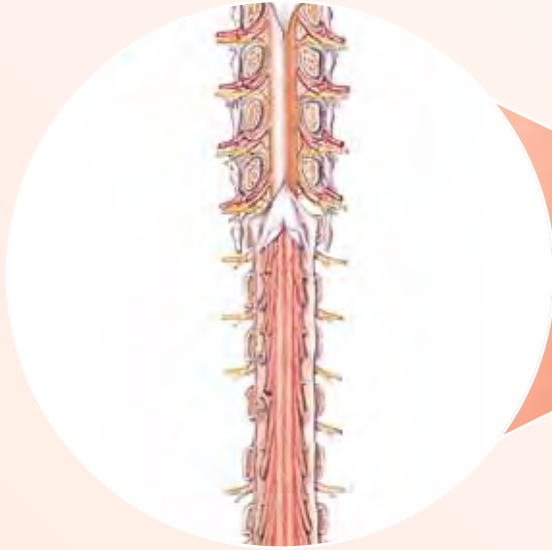
Isiriniq

Qimirluup

qaqqulaangit/ikuvrait

Corps vertébral,  
disque intervertébral

# Vertebral Canal



ԳՐՈԿԳԵՎԻՆ

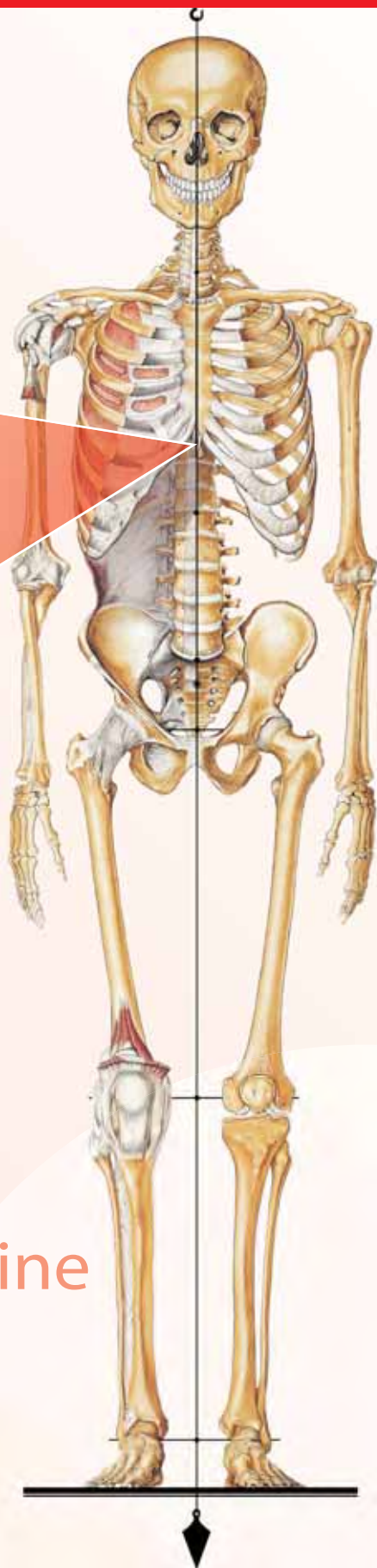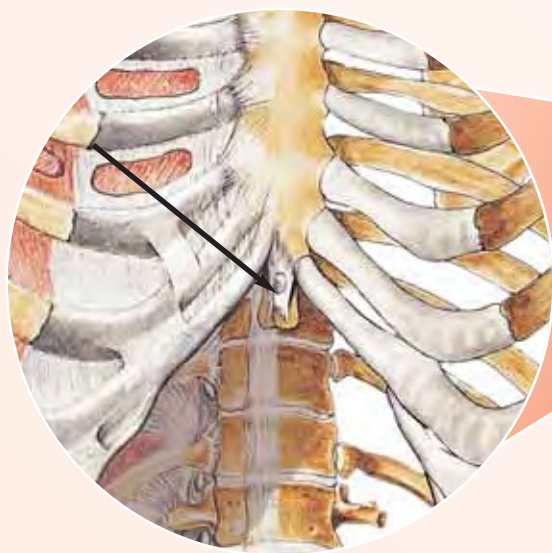
Qitiraqarvik

Pattaq

Canal vertébral



# Xiphoid



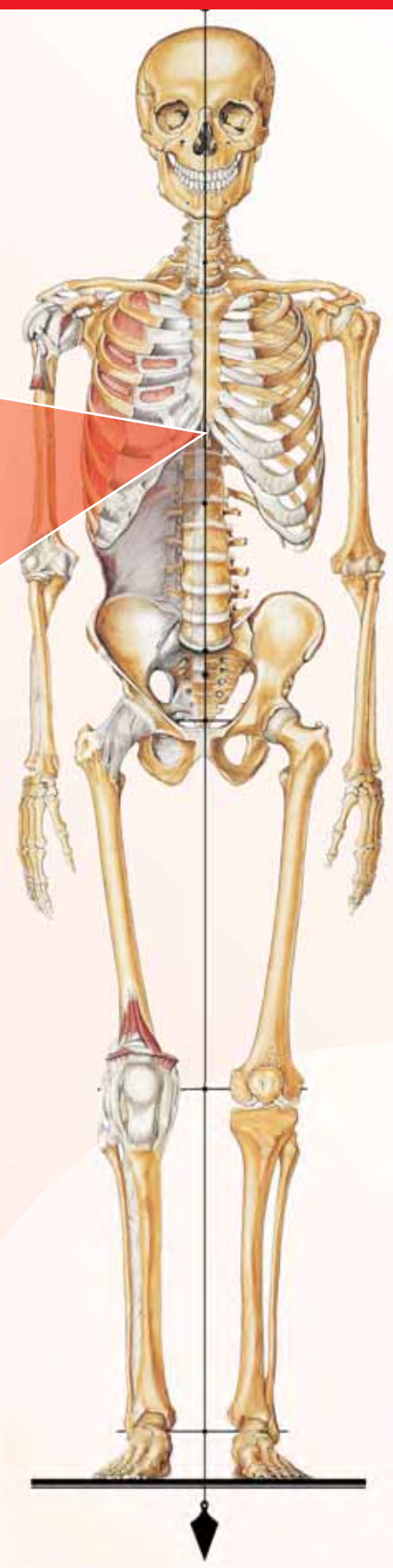
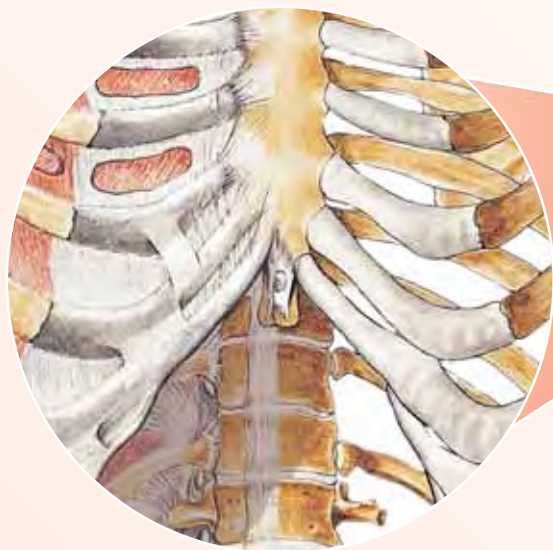
ᐱᓐᓂᓂᓐ

Saqqaaq

Ilaun'nguaq

Creux à la base  
du sternum, poitrine

# Xiphoid Process



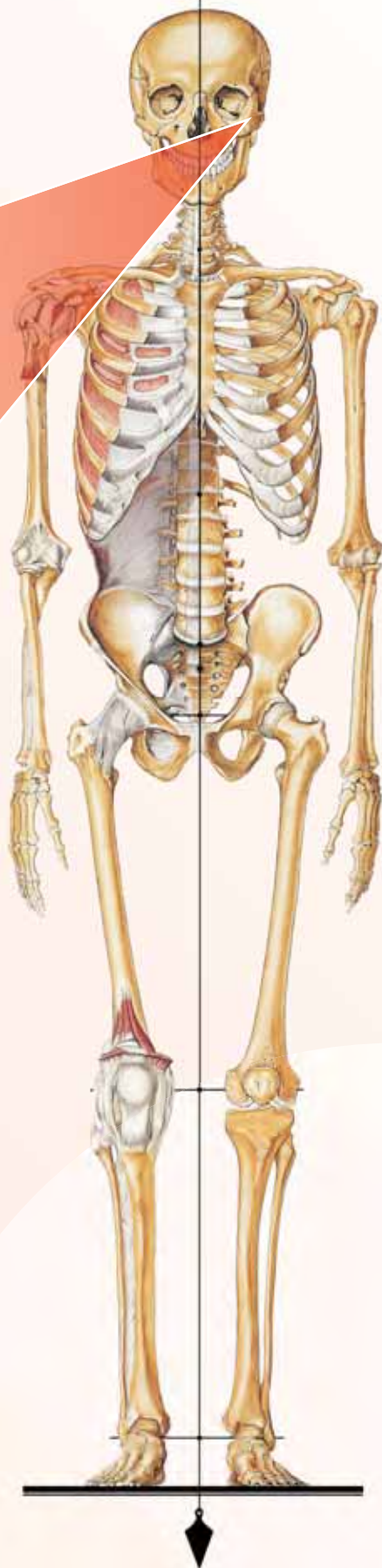
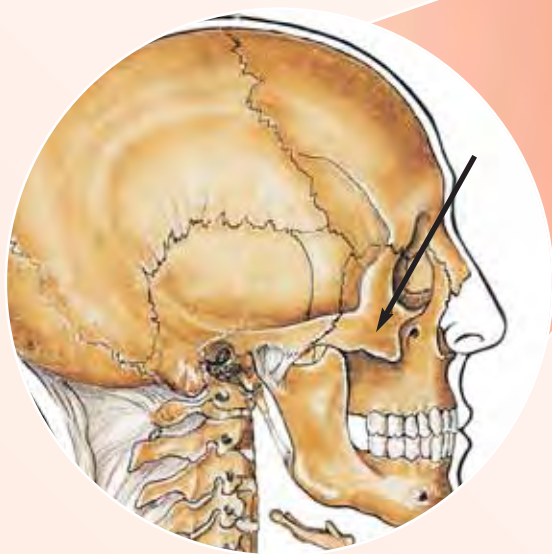ᐱᑦᑲᑲᑲᑲ

Saqqaaq

Ilaun'nguyaaq

Appendice  
xyphoïde

# Zygomatic Arch



ᐅᐱᐱᐱ ᐱᐅᐱᐱ

Uluap Sauninga  
Agliqqup Kangia  
Arcade  
zygomatique





IBC Blank



ᐃᑦᑲᑦᑲᑦᑲᑦᑲᑦᑲᑦ  
Pitquhiliqiyikkut  
Culture and Heritage  
Culture et Patrimoine